

Chronic Sinusitis: Defective T-Cells Responding to Superantigens, Treated by Reduction of Fungi in the Nose and Air

DONALD P. DENNIS

Atlanta Center for ENT and Facial Plastic Surgery
Atlanta, Georgia

and

Department of Otolaryngology—Head and Neck Surgery
Northside Hospital
Atlanta, Georgia

and

Department of Otolaryngology—Head and Neck Surgery
Piedmont Hospital
Atlanta, Georgia

ABSTRACT. In this study, the author used endoscopic sinus photography to study the effects of reduction of fungi in the nose, and in environmental air, on the sinus mucosa of 639 patients diagnosed with chronic rhinosinusitis. Sinus mucosal photographs were taken before and after reduction of fungal load in the nose and air, to determine if there was an optimum environmental air fungal load associated with sinus mucosal recovery to normal appearance. Systemic symptoms associated with fungal exposure, which resolved when fungus was removed from the patient and the environmental air and reappeared with recurrent environmental fungal exposure, are also discussed and are termed *systemic fungal symptoms*. Interventions consisted of nasal fungal load reduction with normal saline nasal irrigations and antimicrobial nasal sprays, and environmental air fungal load reduction with high-efficiency particulate air (HEPA) filtration in combination with ionizers or evaporation of a solution of botanical extract. Main outcome measures were obtained with environmental air 1-hr gravity-plate fungal colony counts, laser air particle counts, and endoscopic sinus photography. Blood levels of immunoglobulins IgG and IgE for 7 common molds were also determined. After intervention, 94% of patients who used antimicrobial nasal sprays and who reduced their environmental fungal air count to 0–4 colonies per 1-hr agar gravity-plate exposure ($n = 365$) exhibited normal sinus mucosa by endoscopic exam. Environmental air fungal counts that exceeded 4 colonies resulted in sinus mucosal abnormalities ranging from edema, to pus and/or nasal polyps at higher counts. Neutralization of allergy, and/or surgery, were used as appropriate following implementation of environmental measures. On the basis of these observations, as well as detailed clinical experience and a review of the current literature, the author hypothesizes that the pathogenesis of chronic rhinosinusitis, allergic fungal sinusitis, and systemic fungal symptoms is a genetic defect at the variable beta chain helper T-cell receptor (TCR $V\beta$) site which requires the presence of an antigen (fungus). Chronic sinusitis patients who have recurring exposure to environmental air that contains fungal concentrations in excess of 4 colonies per 1-hr agar plate exposure appear to have an increased risk of persistent chronic sinusitis and/or systemic symptoms, regardless of the medical treatment provided.

<Key words: allergic fungal sinusitis, mold, rhinosinusitis, sinusitis, superantigen, T-cell receptor>

CHRONIC RHINOSINUSITIS (CRS) affects approximately 37 million Americans, or 1 in 6 (16.3%). It is more common than arthritis (12.47%), orthopedic impairment (12.14%), or hypertension (11.44%). CRS

costs patients and insurance companies over \$2.4 billion per year for medication, hospitalization, and surgery. In excess of 200,000 sinus surgeries are performed every year in the U.S. Many patients remain refractory

to surgery and antibiotic therapy, despite the more than 46.9 million prescription and nonprescription medications ordered annually.¹ Antibiotics are not effective in treating CRS because they target bacterial super-growth and not the underlying fungal problem. In the most recent decade, the rate of CRS occurrence has been increasing steadily,¹ but the pathogenesis of chronic sinusitis has not yet been determined. The standard school of thought is that fungus allergy is involved in fewer than 10% of cases,¹ likely because fungi are visible endoscopically in the nose in less than 10% of cases studied. However, fungi are present microscopically in 93% of cases examined by culture.² By definition, all CRS patients also have secondary bacterial infections. It is likely that the immune reaction to microscopic fungi causes mucosal pitting and mucous stasis, both of which lead to the development of secondary bacterial infections.²

In 1999, researchers at the Mayo Clinic demonstrated a causal connection between fungi and CRS. They found that 93% of all CRS cases also met the diagnostic criteria for allergic fungal sinusitis (AFS). It was postulated that an immune reaction to fungi in the mucosa is likely responsible for AFS and most CRS.² This fact was confirmed by Braun et al.³ in 2003. In addition, immunoglobulin (Ig)E-mediated hypersensitivity was not present in the majority of cases studied, regardless of whether nasal polyps were present.

Because 93% of CRS cases were found to meet the diagnostic criteria for AFS, it is likely that AFS and CRS represent varying degrees of allergic response to the same fungal antigens, with AFS representing more extensive production of polyps and allergic mucin. Therefore, AFS and CRS will be used synonymously in this article. The Mayo Clinic's diagnostic criteria for AFS are (a) CRS; (b) presence of allergic mucin (clusters of eosinophils and their byproducts, such as Charcot-Leyden crystals and major basic protein); and (c) presence of fungal organisms in the mucin, confirmed by histology or culture, or both.² In the present study, radioallergen sorbent (RAST) delayed mold reaction testing revealed elevated fungus-specific IgG levels to 2 or more of 7 common fungi in all patients.

In CRS patients, the nasal mucous contains eosinophils, Charcot-Leyden crystals, IgG fungal antibodies, no helper T-lymphocytes, and no antigen-processing cells (APCs).² Peripheral blood and nasal mucosa of CRS patients contain fungal-specific elevated IgG and fungal antigens. These antigens activate helper T-lymphocytes in the blood, producing cytokines (interleukin [IL]-5 and IL-13) that recruit eosinophils; lymphocytes from normal controls do not recruit eosinophils in response to fungal antigens.⁴ This fact is key to our hypothesis because it means that helper T-cells in CRS patients are bypassing APCs, and are therefore likely to have defective receptor sites.

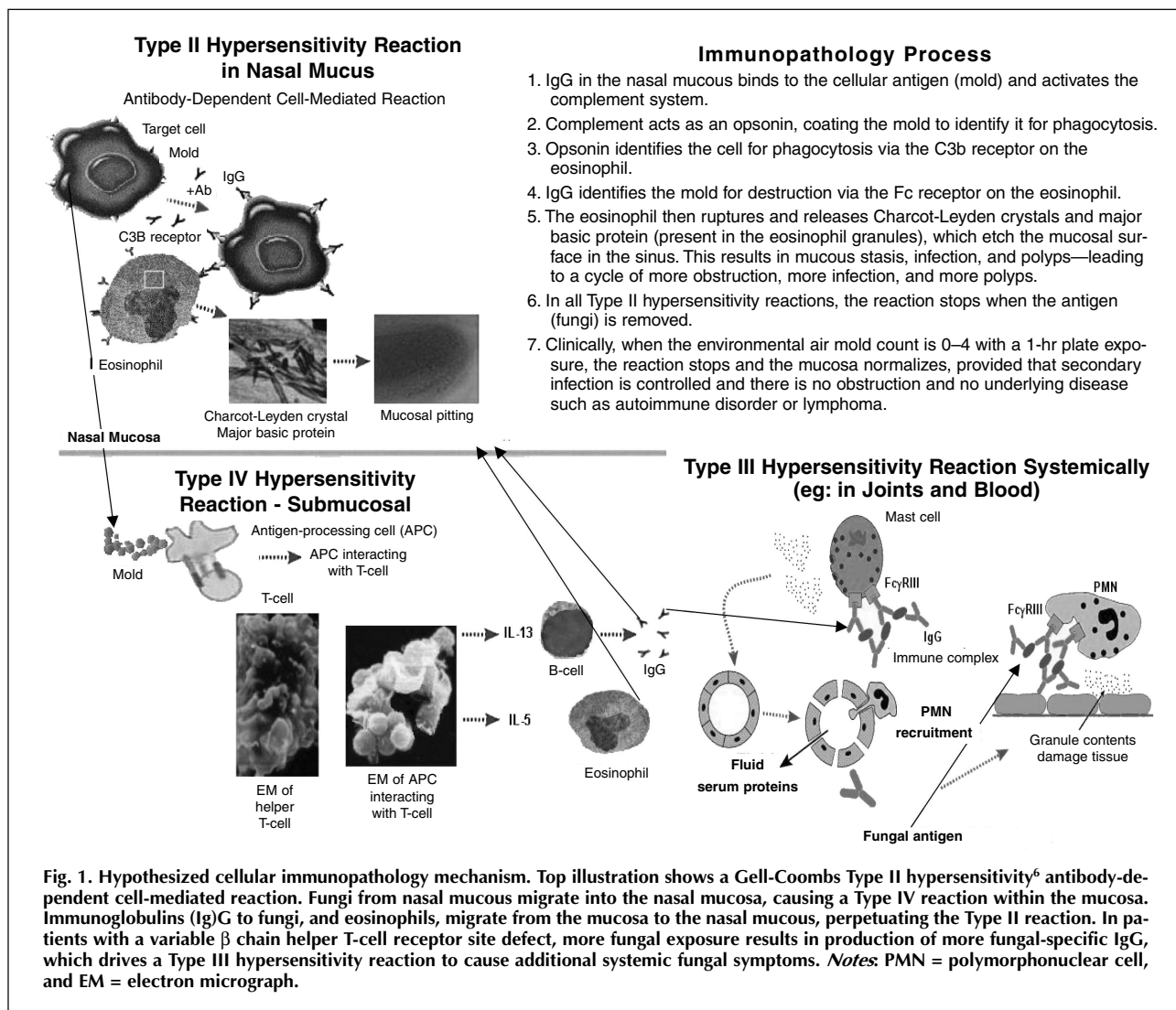
IL-13 causes immunoglobulin isotype switching (e.g., to IgE and IgG₁) and IgG production by immature B lymphocytes. IL-5 promotes eosinophil activation and activates B cells for terminal differentiation into Ig-secreting cells.⁴ Thus, both eosinophils and IgG are ready to migrate through the mucous membrane and attack the mold in the nasal mucous—a classic Type II hypersensitivity reaction (Fig. 1).

Waxman et al.⁵ proposed a Gell-Coombs Type III hypersensitivity reaction⁶ in *Aspergillus* sinusitis and chronic bronchopulmonary disease. In AFS, the sinus mucosa contains small lymphocytes, plasma cells, and eosinophils—a condition similar to that seen in asthmatic bronchial mucosa.⁷

Systemic immune-complex-mediated disease (Type III hypersensitivity reaction) affects tissues of the kidneys, joints, skin, heart, and serosal surfaces. The reason for this specific organ/tissue predilection is unknown. More work is needed to determine if a Type III hypersensitivity reaction to fungus is responsible for the arthritis and other systemic fungal symptoms seen clinically.

The only real difference between Type II and Type III reactions, then, is in the location of the antigen. Type II reactions are against antigens located on cell surfaces or on extracellular matrix components, whereas Type III reactions occur against soluble or circulating antigens. Systemic lupus erythematosus and most types of glomerulonephritis are the result of Type III immune injury.⁸ Therefore, in all types of allergic hypersensitivity reactions, when the antigen (fungus) is removed the reaction stops. This fact forms the basis for our CRS treatment goal: to remove fungal antigen from both the nose and the environmental air, in order to stop the fungal immune reaction and allow the sinus mucosa to recover.

Researchers have hypothesized that the immunopathology affecting more than 16% of the population is the result of a genetic defect in 1 or more of 9 genes (genes 2, 3, 5.1, 6.7, 8, 12, 13.1, 13.2, 17) on the outside of the beta chain variable region of the T-cell receptor site (TCR V β genes)⁹⁻¹¹ (Fig. 2). Normally, the antigen (fungus) must first be processed by an APC into smaller fragments, and these fragments must be transported to the human leukocyte antigen (HLA) class II molecule on the surface of the APC, in order for the TCR site to recognize the antigen linked with the HLA II molecule and bind to it,⁶ causing the T-cell to release IL-5 and IL-13. Because the helper T-lymphocytes of CRS patients produce IL-5 and IL-13 when presented with fungal antigens, without APCs,⁴ the fungus is likely bypassing the APC HLA II molecule (the antigen-specific area) and binding directly to the outside of the TCR V β site via defective gene(s) on the TCR V β chain. This genetic defect allows a microbe or toxin superantigen to bind to HLA class II histocompatibility molecules on APCs and TCR sites simultaneously, bypassing APC-induced activation of T-cells.^{9,10,12,13} The result is pro-



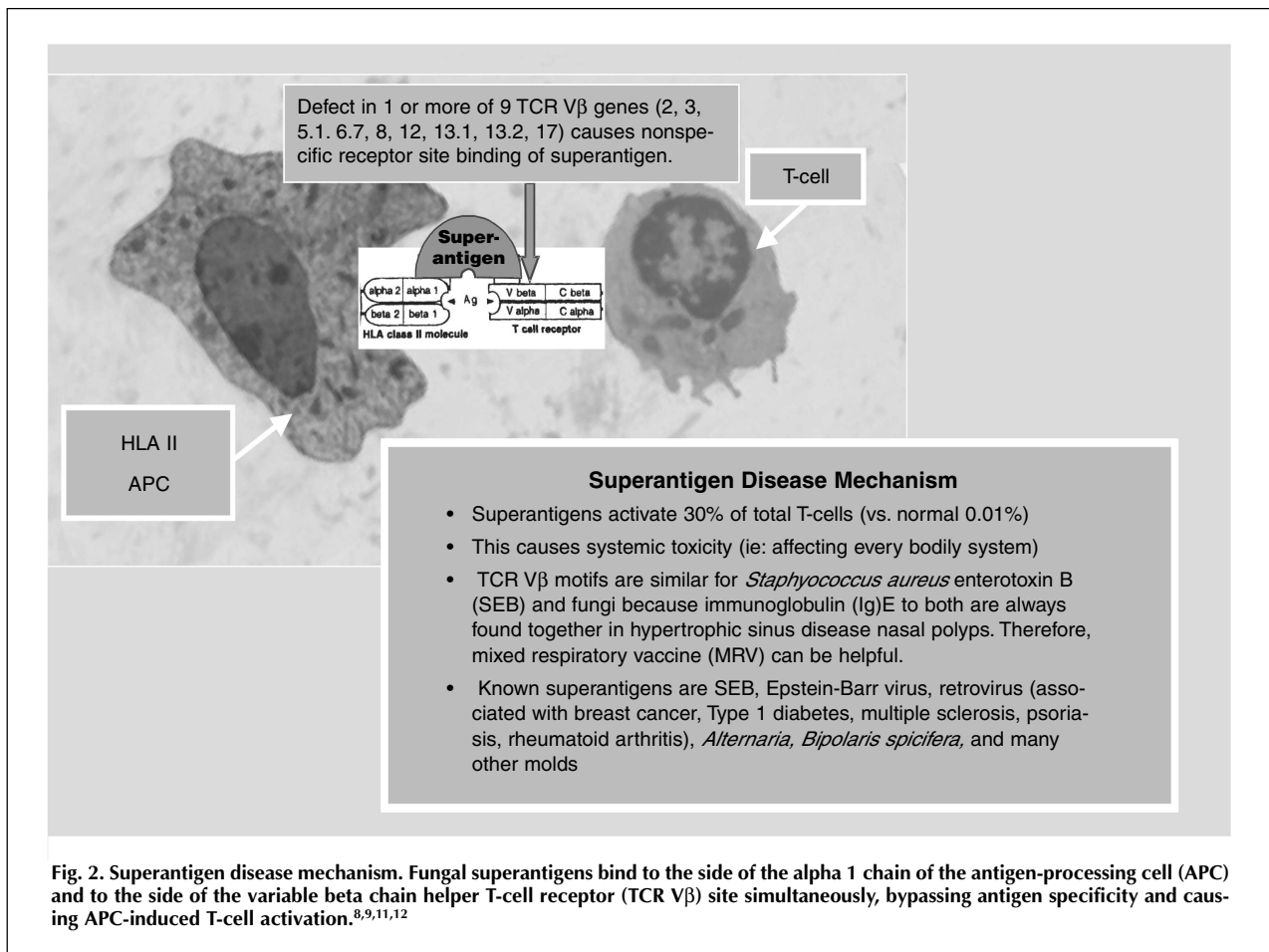
found activation of up to 30% of the body's total T-cells, in contrast with the normal T-cell response of < 0.01%.¹⁴ The subsequent superantigen-induced T-cell activation can cause systemic toxicity and is the likely mechanism for fungal-induced sinusitis and systemic disease.⁹

Superantigens are thought to be associated with systemic disease (e.g., human retrovirus in breast cancer,^{9,15} Type I diabetes, and multiple sclerosis¹⁶). Superantigens have also been linked causally to psoriasis^{17–19} and rheumatoid arthritis.^{20,21} Some fungi are thought to function as superantigens.^{4,9} Our clinical observations have supported such an association because both the CRS and systemic fungal symptoms (e.g., arthritis, memory loss, 6th nerve palsy, dizziness, hearing loss, seizures, fatigue, vision problems, severe headaches, gastroesophageal reflux disease, gastrointestinal disturbances, asthma, IgG subclass deficiency, and fibromy-

algia) have resolved with the use of antimicrobial nose sprays and environmental fungal removal protocol, and return when the protocols are discontinued or when fungal levels in air rise. This retrospective observational study and literature review were conducted to formulate an hypothesis for the cause of CRS and systemic symptoms associated with fungal exposure.

Materials and Method

Study subjects. Between 1989 and 2003, 639 patients age 8–76 yr (average age = 46 yr; 381 females and 258 males) diagnosed with CRS who had failed traditional antibiotic and/or surgical therapy were studied in our private practice otolaryngology clinic. Findings required for inclusion in the study were (a) a diagnosis of CRS on the basis of patient history, (b) abnormal endoscopic sinus exam, and (c) abnormal sinus computed



tomography (CT) scan. Symptoms must have been present for at least 3 mo and had to include 2 or more of the following: (a) facial pain or pressure, (b) facial congestion or fullness, (c) nasal obstruction or blockage, (d) nasal discharge/purulence/discoloration, (e) postnasal drainage, or (f) hyposmia/anosmia. Sinusitis must have been present for at least 3 mo and been treated with antibiotics for 4–6 wk (or 4 or more sinusitis episodes per year treated with antibiotics for 7–10 days each), with symptoms persisting or recurring after cessation of antibiotic treatment.

Treatment protocols. Both the patients themselves and the air in their home, office, and/or car environments (wherever fungal load was found to be elevated) were treated to reduce fungal load. Treatment of patients consisted of (a) normal saline nasal irrigations twice daily to remove fungi mechanically and (b) 2 antimicrobial nasal sprays (containing 2 structurally different antibiotics, an antifungal, and a steroid), administered as 3 sprays, 4 times daily for 4–10 wk, depending on the time required to clear the sinus mucosa, as verified by endoscopic exam. Our nasal spray protocol is summarized in Table 1.

Environmental remediation consisted of reducing air fungal load by following an environmental treatment protocol that included finding and repairing moisture intrusion and implementing portable high-efficiency particulate air (HEPA) filtration or inline central heating, ventilation, and air conditioning system (HVAC) filtration (94% efficient at 0.35- μ m particle size), in combination with either ionizers or the disbursement of botanical extract by evaporation. The odorless botanical extract was dispersed by the patient or environmental consultant by placing 2–4 foil-covered containers, with wicks perforating the foil, on top of a portable HEPA air filtration unit that exited clean air from the top of the machine. These setups were placed in each room used by the patient. In some cases, Room VI 2500 ionizers were used in combination with portable HEPA air filters, instead of the botanical extract. (Botanical extract and an ionizer could not be used in the same room because the ionizer destroys the activity of the extract.) With the patients' permission, sources of moisture intrusion were identified and controlled. Cars were treated by spraying botanical extract into the HVAC system from the outside suction vent at the windshield on both

Table 1.—Antimicrobial Nasal Spray Protocol

1. Begin clindamycin and garamycin sprays (all antibiotic sprays contain an antifungal, clotrimazole or other) with steroids.
 - Omit steroids if patient has steroid difficulty.
 - Add monteleukast for nasal polyps and for maintenance therapy.
 - If patient is allergic to clindamycin, use cefazolin or trimethoprim/sulfamethoxazole.
 - If patient is allergic to garamycin, use ciprofloxacin.
2. If fungus is visible, or if there is a history of significant fungal exposure, use amphotericin-B, clindamycin, and gentamycin sprays.
 - Use amphotericin 1st (unstable), then the clindamycin and gentamycin sprays.
 - Always use all sprays together: 3 sprays qid.
3. Use sprays for 2–8 wk, or until mucosa is clear by sinus endoscopy or computed tomography sinus scan.
4. Maintain with:
 - Agumax® (4 different citrus seed and citrus skin extracts) mixed with betadine and a steroid.
 - Monteleukast nose sprays: 3 sprays each nostril bid (qid when traveling or after exposure).

Note: All spray formulas, and pharmacist training, provided by PharmaSource Int'l, Inc. (Denver, Colorado).

sides, and on the inside of the car. (Portable HEPA filters, botanical extract containers, and ionizers were supplied by National Allergy Supply, Inc. [Atlanta, Georgia] and PharmaSource Int'l, Inc. [Denver, Colorado]; central inline air filters and moisture intrusion correction were supplied by Mead Indoor EnviroTech, Inc. [Atlanta, Georgia].)

All environmental treatment devices were evaluated for effectiveness by an independent mycology laboratory prior to use in the study. Before each device was tested, a gravity-exposure Sabouraud dextrose agar (SDA) plate (PharmaSource Int'l, Inc. [Denver, Colorado]) was exposed for 1 hr inside a test room documented to contain fungal colonies too numerous to count (TNTC). All devices reduced the test room's fungal colony count from TNTC to 0–2 colonies by day 6.

Monitoring. Prior to treatment of the patient and environment, endoscopic sinus photography was performed, and nose and air fungal cultures were taken. Bacterial cultures were taken when visible pus was present. A Calgi swab on SDA was used for nose culture, and a 1-hr gravity SDA plate exposure for the environment. Plates containing nose swab samples were incubated in a dark area at room temperature for 3 days. If growth was observed, the plate was sent to a mycology laboratory (Quest Diagnostics Mycology Laboratory [Atlanta, Georgia]) for counting and identification.

Air samples were taken by exposing open plates in the areas where the patient spent most time, as well as in areas of likely contamination (e.g., bedroom, kit-

chen, den, office, car, basement, crawlspace, attic) for 1 hr with the central HVAC fan in the "on" position. The plates were placed at least 0.91 m (3 ft) from any wall. After exposure, the plates were enclosed in foil and sent to a mycology laboratory (Mold Lab Int'l [Knoxville, Tennessee]) for evaluation.

After treatment of the patient and air to reduce fungal load—in accordance with the aforementioned protocols—1-hr SDA plate exposures were repeated for the environmental air, and a 2nd set of endoscopic sinus photographs were taken for each patient. Comparisons were then made between the environmental fungal colony counts and the endoscopic sinus photographs. If nasal and environmental air fungal cultures did not correspond, a different source of sinus infection was suspected.

Laser air particle counts were performed by Mead Indoor EnviroTech (Atlanta, Georgia) before and after treatment of environmental air. A ParticleScan Pro laser airborne particle counter (IQAir, Inc. [Santa Fe Springs, California]) set at 0.3 μm per 1 ft^3 (0.03 m^3) was used to count particles. The resulting values were expressed as number of particles per 0.1 ft^3 for convention. The RAST assay was used to detect serum IgG (delayed mold reaction) and IgE fungus-specific antibody levels for 7 common fungal antigens: *Alternaria alternata/tenuis*, *Aspergillus fumigatus*, *Candida albicans*, *Cephalosporium acre*, *Cladosporium herbarum*, *Helminthosporium halodes*, and *Penicillium notatum/chrysogenu*. Antibodies for the same 7 antigens were tested by Esoterix Laboratory Services, Inc. (Austin, Texas) with enzymatic immune assay.

Literature review. A review of current literature was conducted to aid in formulating an hypothesis for the pathogenesis of both AFS and systemic fungal symptoms.

Results

A total of 639 patients with persistent CRS were studied. After treatment of the patients and their environments to reduce fungal load, 343 of the patients, who had abnormal sinus mucosa before treatment, showed normal mucosa without infection. Nasal mucosa failed to normalize in 22 patients. Of these, 3 were found to have lymphoma (1 T-cell and 2 B-cell) and 19 had persistent positive nasal fungal cultures (likely resulting from uncontrolled exposure to environmental fungi). In 219 cases, patients were unable to reduce the mold counts in their environments below 5 colonies and had various degrees of mucosal disease remaining. Fifty-five patients were lost to follow-up. All patients had elevated fungus-specific serum IgG levels to 2 or more of the 7 common fungi tested.

Particle and fungal counts. Laser air particle counts higher than 50,000 particles per 0.1 ft^3 (0.003 m^3) at 0.3- μm particle size were associated with sinus mucosa ab-

normalities ranging from edema, to polyps and/or pus. However, counts below 50,000 were associated with sinus mucosal health *only* if mold counts were below 5 colonies per 1-hr gravity-plate colony count. Approximately 90% of patients cultured both mold and bacteria. The bacteria types seen were typical and have been described by many researchers. It is generally agreed that chronic antibiotic treatment does not stop CRS.

Literature review. Review of the current literature supported our hypothesis that the pathogenesis of CRS, AFS, and systemic fungal symptoms is a genetic defect at the TCR V β site, requiring antigen (fungus) presence. When more than 4 fungus colonies (per 1-hr gravity-plate exposure) are present in these patients' environmental air, chronic sinusitis and/or multiple systemic symptoms can present clinically.

Systemic fungal symptoms. The most common systemic symptoms seen to occur with fungal exposure, to resolve with fungal removal, and to recur with repeated fungal exposure are listed below. When these symptoms occur and recur in this manner, it is logical to hypothesize that fungi are the causative agents. The symptoms vary widely among patients and are general. No symptom is listed unless it began with fungal exposure, was concurrent with positive nasal and environmental fungal cultures, and resolved with fungal removal. The following systemic fungal symptoms were observed in our study subjects:

- Headache in the frontal sinus, radiating to the temples.
- Dizziness—both imbalance and vertigo with spinning—and impaired depth perception (e.g., patient misses stair step going down).
- Hearing loss—both high- and low-frequency, both temporary and permanent.
- Tremors, with severe leg pain and thigh weakness. Inability to walk. Non-neurological muscle weakness, fibromyalgia, lip and hand paresthesias, seizures (rare).
- Pain in some or all joints.
- Cognitive disorder and memory loss (e.g., cannot do serial 7's [mental subtraction: 100 – 7 = 93, 93 – 7 = 86, etc.], cannot remember instructions, and cannot tell directions to common places).
- Other symptoms, including loss of smell and taste, chronic sinus infections, bloating diarrhea, esophageal reflux (specific to hypopharyngeal, esophageal, and gastric candidiasis), severe fatigue.
- Immune suppression IgG subclass deficiency.

See Figure 1 for the likely mechanism of the Type III hypersensitivity reaction.

When patients were treated with the combination of medical therapy (Table 2) and environmental remediation described herein, symptoms of sinus congestion, headache, pressure, and pain, as well as the other sys-

Table 2.—Treatment for Systemic Fungal Symptoms, with or without Sinusitis

- Systemic antifungals:
 - Fluconazole (Diflucan®), itraconazole (Sporonox®), terbinafine (Lamisil®), or Voriconazole (VFEND®) \times 14–28 days.
 - Grapefruit seed extract (delayed-release [PharmaSource Int'l, Inc. {Denver, Colorado}]) 50–75 mg po bid for 3–6 mo, depending on symptom resolution.
- Nasal sprays:
 - Antifungal: amphotericin-B.
 - Leukotriene inhibitor: montelukast (Singulair®).
 - Antibiotic: clindamycin (gentamycin if infection is visible by endoscopic exam).
- Valdecocix (Bextra®) 10–20 mg \times 14–28 days.
- Saline nasal wash.
- Detoxification (e.g., drink distilled water, sauna, take mega-antioxidant vitamins with thymus).
- Antigen neutralization, and autogenous lymphocytic factor (for immune-compromised).

temic symptoms reported, generally tended to resolve within 2–8 wk after 1-hr gravity-plate fungal counts fell below 5 colonies.

Discussion

On the basis of 16 yr of clinical experience with 639 patients—using the treatment protocol described herein and monitoring with both endoscopic photography and sinus CT scans—it can be stated that “As long as fungi remain, so will the irritation and the sinusitis.” Experience has also shown that 1-hr gravity SDA agar plate exposure is a simple, reliable, and predictable method of assessing environmental fungal levels to determine human health risk. The following scale correlates with the results we obtained by comparing endoscopic sinus photos at various mold colony counts with laser air particle counts (Fig. 3 and 4): (a) a count of 0–4 total fungal colonies per room is within a normal range for sinus health, (b) a count of 5–8 colonies per room is cause for concern—illness is probable in patients with the IgG immune reaction to fungi herein described, and (c) a count of 9+ colonies per room is hazardous—illness is very likely among the CRS patient population.

Laser air particle counts below 50,000 per 0.003 m³ (0.1 ft³), at 0.3 μ m particle size, were associated with sinus mucosal health. However, environmental air particle counts in this range, with fungal colony counts greater than 4, were associated with sinus mucosal abnormalities. In other words, high fungal counts will overpower an otherwise clean air particle count and cause illness.

Key points in treatment. Removal of the antigen (fungi) from the patient and the air halts the reaction (i.e., CRS and systemic fungal symptoms). Nasal irriga-

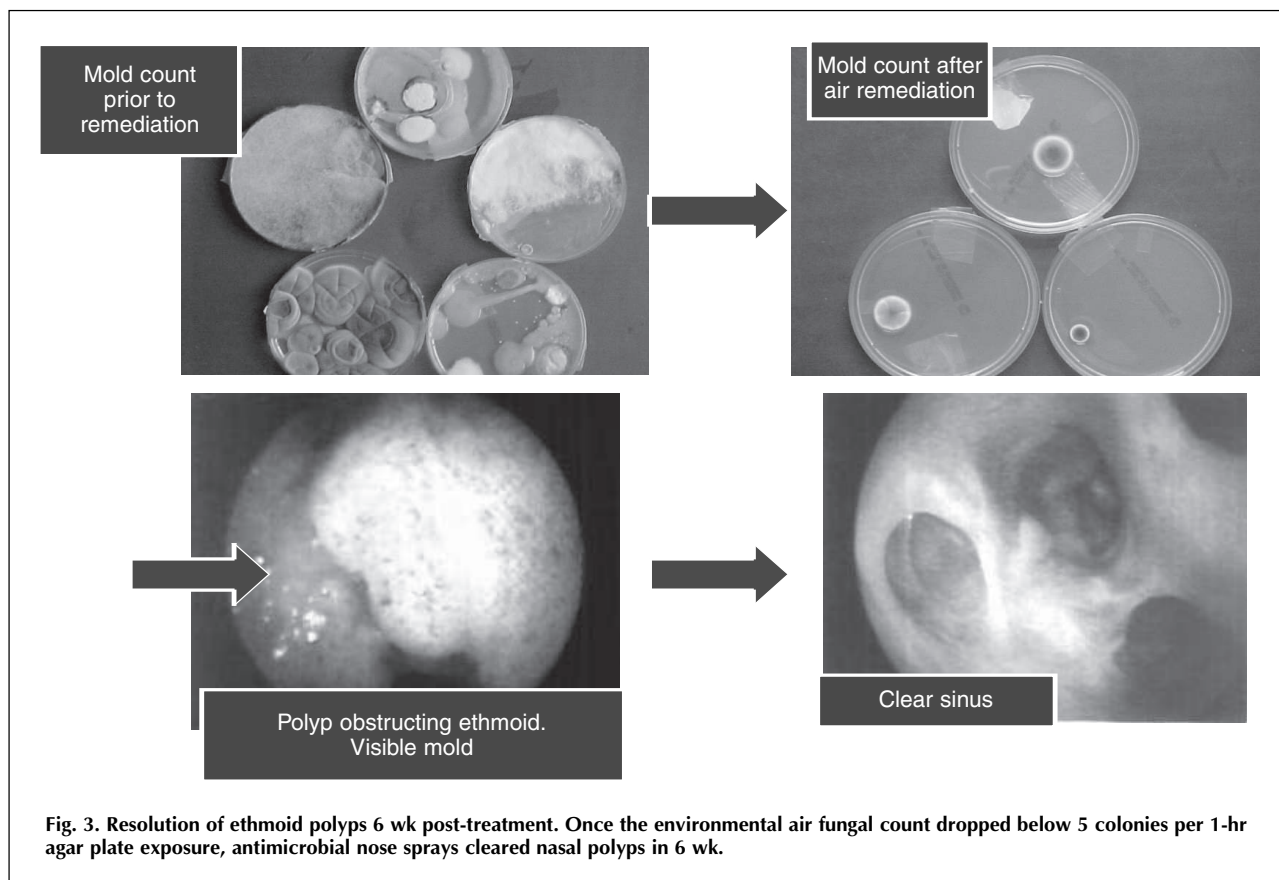


Fig. 3. Resolution of ethmoid polyps 6 wk post-treatment. Once the environmental air fungal count dropped below 5 colonies per 1-hr agar plate exposure, antimicrobial nose sprays cleared nasal polyps in 6 wk.

tion with normal saline is essential for reducing nasal antigen load and antigen-induced inflammation. Because more than 90% of patients cultured both fungi and bacteria, combined antifungal and antibiotic nasal sprays are key to long-term control of CRS. Appropriate use of oral antibiotics, antifungals (fluconazole, delayed-release grapefruit seed extract capsules, terbinafine, itraconazole, voriconazole) and antihistamine/decongestants is also recommended. Clinical experience has shown that immunotherapy for IgE- and IgG-specific molds is beneficial, with neutralization as needed. Mixed respiratory vaccine for chronic *Staphylococcus aureus* is helpful if staph is consistently cultured. Approximately 10% of patients studied had severe nasal polyposis and cultured staph. IgE to both staphylococcal enterotoxin B and dermatiaceus fungi are almost always found together in situ in hypertrophic sinus disease nasal polyps.²² Endoscopic sinus surgery is essential for patients who fail medical therapy. However, absent removal of fungus from the nose and air, bacterial sinusitis remains, regardless of immunotherapy, vaccine, or surgical intervention.

The 93% of CRS patients in the Mayo study² who had positive fungal nasal cultures also exhibited secondary bacterial infections, likely as a result of the mucosal pitting and mucus pooling that occurs when an eosinophil

binds to fungi in the nasal mucosa, ruptures, and releases major basic protein into the mucosa. This may explain our observation that antibiotic nose sprays are more effective when combined with an antifungal spray. When fungi were successfully removed from the nose and air, 94% of patients showed endoscopic sinus mucosal improvement to a normal appearance (i.e., no mucosal edema, polyps, or purulence), as depicted in Figures 3 and 4.

Treatment failure strategy. When environmental fungal counts are in the range conducive to good sinus health (0–4 colonies), endoscopic sinus surgery has been performed, all treatment has failed, and a patient still has CRS, the following approach is recommended. The patient should be referred to a hematologist/oncologist for thorough work-ups for lymphoma, all collagen vascular diseases, Immune-Deficiency Syndrome, endocrine disorders, and Chronic Fatigue Syndrome. Because mold contamination previously unidentified by history and environmental testing may be the cause of sinusitis treatment failure, patients should be asked again about potential sources of exposure (e.g., gardening and other hobbies, cleaning, construction, moving of old boxes, or use of old books). Areas involved should be tested (or retested) with SDA agar plates, and an effort should be made to eliminate these exposures.

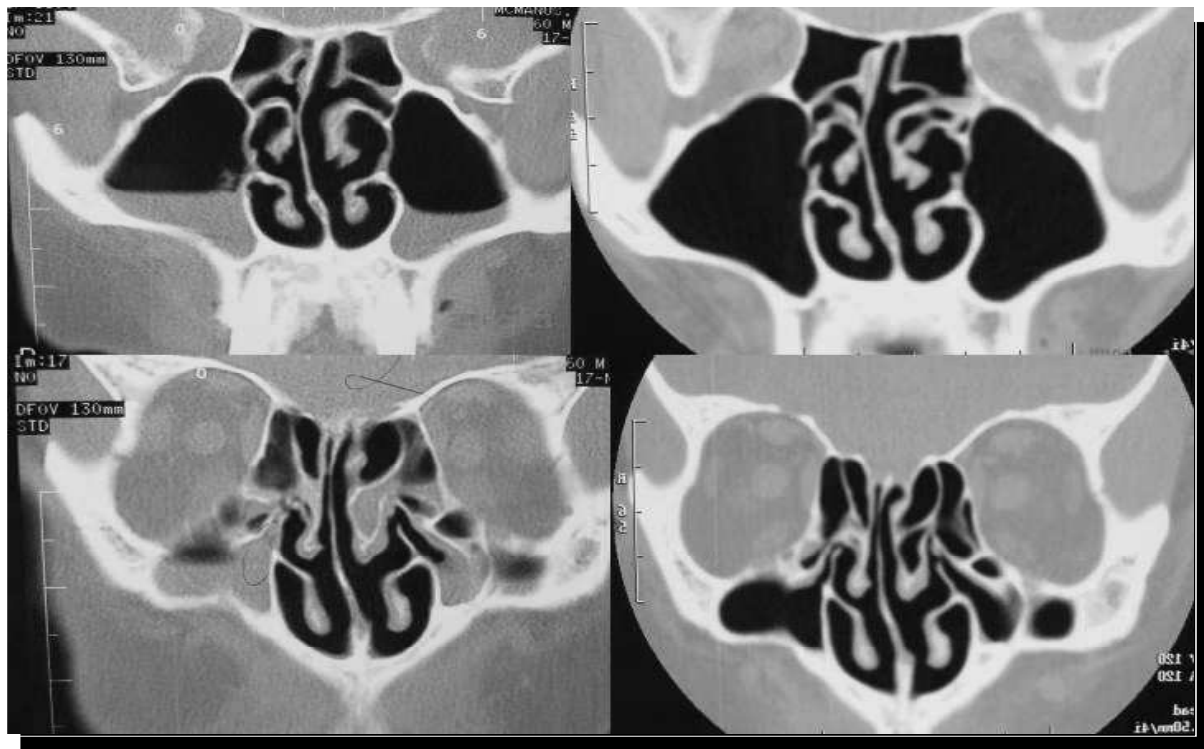


Fig. 4. Computed tomography scans of subject's sinuses pre- and post-treatment. *Left*. 2 scans showing sinusitis prior to treatment. *Right*. 2 scans showing clear sinuses 1 mo after environmental treatment protocol and use of antimicrobial (antibiotic and antifungal) nose sprays.

Conclusions

CRS and systemic fungal symptoms are likely caused by an immune response to fungal antigen. When the antigen is removed from the nose and the environmental air, the immune reaction stops; the sinus mucosal edema, polyps, and/or pus improve or resolve; and systemic symptoms improve or resolve. Fungus is likely responsible for most CRS, and for a complex of systemic symptoms, as a result of a genetic defect on the TCR Vβ site. Exceptions to this are underlying diseases, failure to find the source of the mold exposure, and permanent systemic immune damage resulting from lengthy fungal exposure. Chronic sinusitis patients who have recurring exposure to environmental air containing fungal concentrations in excess of 4 colonies per 1-hr agar plate exposure appear to have an increased risk of persistent chronic sinusitis and/or systemic symptoms, regardless of the medical treatment provided.

* * * * *

The author thanks Malcolm Wilkinson, R.Ph., for tirelessly compounding antimicrobial nasal sprays for these patients over the last 20 yr; the patients themselves for teaching him

how to help them back to wellness; and his staff for their help in assembling all the data.

Submitted for publication September 20, 2003; revised; accepted for publication November 19, 2003.

Requests for reprints should be sent to Donald Patrick Dennis, M.D., F.A.C.S., Atlanta Center for ENT and Facial Plastic Surgery, 3193 Howell Mill Road, Suite 215, Atlanta, GA 30327. E-mail: ddennis@mindspring.com

* * * * *

References

1. Kaliner MA, Osguthorpe JD, Fireman P, et al. Sinusitis: bench to bedside. Current findings, future directions. *J Allergy Clin Immunol* 1997; 99:S829-48.
2. Ponikau JU, Sherris DA, Kern EB, et al. The diagnosis and incidence of allergic fungal sinusitis. *Mayo Clin Proc* 1999; 74:877-84.
3. Braun H, Buxina W, Freudenschuss K, et al. Eosinophilic fungal rhinosinusitis: a common disorder in Europe? *Laryngoscope* 2003; 113:264-69.
4. Ponikau JU. *Chronic Rhinosinusitis: The War of the Immune System Against Fungi*. Bronx, NY: American Rhinologic Society News, January 2001. Available from <<http://american-rhinologic.org/cgi-bin/menu.cgi?m=main.menu&state=1001210000100000001000000&cite=4&f=news.0102.ponikau.phtml>>

5. Waxman JE, Sale SR, Spector JG, et al. Allergic *Aspergillus* sinusitis: concepts in diagnosis and treatment of a new clinical entity. *Laryngoscope* 1987; 97:261–66.
 6. Nelson S. Gell-Coombs Classification of Hypersensitive Reactions. Geneva, Switzerland: Health on the Net Foundation, 2001. Available from <<http://www.hon.ch/Library/Theme/Allergy/Glossary/gcc.html>>
 7. Hamilos DL. Chronic sinusitis. *J Allergy Clin Immunol* 2000; 106:213–27.
 8. Oswald MR. Basic Immunology. Kansas City, KS: University of Kansas Medical Center, 2000; 4:72. Available from <http://www.kumc.edu/instruction/medicine/pathology/ed/keywords/kw_hypersen1.html>
 9. Schubert MS. A superantigen hypothesis for the pathogenesis of chronic hypertrophic rhinosinusitis, allergic fungal sinusitis, and related disorders. *Ann Allergy Asthma Immunol* 2001; 4:181–87.
 10. Kotzin BL, Leung DY, Klapper J, et al. Superantigens and their potential role in human disease. *Adv Immunol* 1993; 54:99–166.
 11. Klapper J, Kotzin B, Herron L, et al. V β -specific stimulation of human T cells by staphylococcal toxins. *Science* 1989; 244:811–13.
 12. Choi Y, Kotzin B, Hernon L, et al. Interaction of *Staphylococcus aureus* toxin “superantigen” with human T cells. *Proc Natl Acad Sci USA* 1989; 86:8941–45.
 13. Marrack P, Kappler J. The staphylococcal enterotoxins and their relatives. *Science* 1990; 248:705–09.
 14. Krakauer T. Immune response to staphylococcal superantigens. *Immunol Res* 1999; 20:163–73.
 15. Liu B, Wang Y, Melana SM, et al. Identification of proviral structure in human breast cancer. *Cancer Res* 2001; 61:1754–59.
 16. Perron H, Jouvin-Marche E, Michel M, et al. Multiple sclerosis retrovirus particles and recombinant envelope trigger an abnormal immune response in vitro, by inducing polyclonal V β 16 T-lymphocyte activation. *Virology* 2001; 287(2):321–32.
 17. Bour H, Demidem A, Garrigue JL, et al. In vitro T cell response to staphylococcal enterotoxin B superantigen in chronic plaque type psoriasis. *Acta Derm Venereol* 1995; 75:218–21.
 18. Leung DY, Travers JB, Giorno R, et al. Evidence for a streptococcal superantigen-driven process in acute guttate psoriasis. *J Clin Invest* 1995; 96:2106–12.
 19. Valdimarsson H, Sigmundsdottir H, Jonsdottir I. Is psoriasis induced by streptococcal superantigens and maintained by M-protein-specific T cells that cross-react with keratin? *Clin Exp Immunol* 1997; 107(suppl):21–24.
 20. Paliard X, West SG, Lafferty JA, et al. Evidence for the effects of a superantigen in rheumatoid arthritis. *Science* 1991; 253:325–29.
 21. Cole BC, Griffiths MM. Triggering and exacerbation of autoimmune arthritis by the *Mycoplasma arthritidis* superantigen MAM. *Arthritis Rheum* 1993; 36:994–1002.
 22. Bachert C, Gevaert P, Holtappels G, et al. Total and specific IgE in nasal polyps is related to local eosinophilic inflammation. *J Allergy Clin Immunol* 2001; 107:607–14.
-