

# LE MORNE CEMETERY: ARCHAEOLOGICAL INVESTIGATIONS

## THE 2010 SEASON: EXCAVATION, RESULTS AND INTERPRETATION

Report commissioned by and prepared for the Truth and Justice Commission, Port Louis, Mauritius.

Prepared and submitted by *Krish Seetah*<sup>4</sup>  
From reports by *Diego Calaon*<sup>1</sup>, *Saša Čaval*<sup>2</sup>, *Joanna Appleby*<sup>3</sup> & *Emma Lightfoot*<sup>3</sup>

1. Università Ca' Foscari, Venezia; 2. Inštitut za antropološke in prostorske študije, Ljubljana; 3. McDonald Institute for Archaeological Research, Cambridge; 4. University of Central Lancashire, Preston, & The Truth and Justice Commission, Port Louis.



THE CONTENT OF THIS REPORT REMAINS THE PROPERTY OF THE AUTHORS AND IS SUBJECT TO COPYRIGHT REGULATIONS. NO PART SHALL BE USED WITHOUT PRIOR AGREEMENT AND DUE ACKNOWLEDGMENT. THIS IS TO INCLUDE TECHNICAL DETAILS.

PROJECT TEAM

Krish Seetah (Project Director)

Diego Calaon (Site Director)

Saša Čaval (Site Director)

Aleksander Pluskowski (Site Director)

SPECIALISTS

Joanne Appleby (Human Osteologist)

Emma Lightfoot (Isotope Analyst)

Will Goodwin (aDNA Analyst)

## TABLE OF CONTENTS

TABLE OF CONTENTS.....	3
LIST OF FIGURES.....	4
LIST OF TABLES.....	4
SUMMARY.....	5
ACKNOWLEDGEMENTS.....	5
FUNDING BODIES.....	5
TECHNICAL SUMMARY.....	6
RECOMMENDATIONS.....	7
1.0. INTRODUCTION.....	10
1.1. Description of the Cemetery and Graves.....	11
2. FIELDWORK PROCEDURE.....	12
2.1 Excavation Procedure.....	12
3. FIELDWORK RESULTS.....	14
3.1 Summary of Excavated Graves.....	15
4. POST-EXCAVATIONAL ANALYSIS.....	27
4.1 Post-excavational Techniques.....	28
4.1.1 Isotopic Methods.....	28
4.1.2 Osteology Methods.....	28
4.2 Post-Excavational Results.....	29
4.2.1 Results of Isotopic Analysis.....	29
4.2.2 Osteological Findings.....	30
4.2.1.1 Demography.....	31
4.2.1.2 Nutritional deficiency and non-specific stress.....	32
4.2.1.3 Dental disease and caries.....	32
4.2.1.4 Infection and trauma.....	34
4.2.1.5 Activity.....	36
4.2.1.6 Other conditions.....	37
5. DISCUSSION AND INTERPRETATION OF RESULTS.....	38
5.1 Discussion of archaeological evidence.....	38
5.2 Discussion of Isotopic Analysis.....	38
5.3 Discussion of Osteological Finds.....	40
6. CONCLUSION AND FUTURE WORK.....	45
BIBLIOGRAPHY.....	46
APPENDIX I: CATALOGUE OF ANALYSED SKELETAL REMAINS.....	49

## LIST OF FIGURES

Fig. 1: Map of Mauritius (capital starred) and site location (Google Earth©).....	10
Fig. 2: Site prior to clearance showing evidence of voodoo practice.....	11
Fig. 3: Site – prior to clearance.....	13
Fig. 4: Site – post clearance.....	13
Fig. 5: Coffin outline evident in grave no: 29, as revealed through careful excavation.....	14
Fig. 6: Layout of grave no. 1.....	15
Fig. 7: Position of both skeletons ‘in situ’, foetal body is in opposing direction to adult.....	16
Fig. 8: Basalt structure of grave no. 06.....	17
Fig. 9: Skeletons ‘in situ’.....	17
Fig. 10: Basalt structure of grave no. 07.....	18
Fig. 11: Skeleton ‘in situ’ with detail of grave goods (coins) under the cranium.....	19
Fig. 12: Basalt structure of grave no. 08.....	20
Fig. 13: Skeleton ‘in situ’.....	20
Fig. 14: Basalt structure of grave no. 25.....	21
Fig. 15: Skeleton ‘in situ’.....	21
Fig. 16: Basalt structure of grave no. 29.....	22
Fig. 17: Skeleton ‘in situ’.....	23
Fig. 18: Basalt structure of grave no. 30.....	24
Fig. 19: Skeleton ‘in situ’ showing waterlogging that occurred at hightide.....	25
Fig. 20: Basalt structure of grave no. 33.....	26
Fig. 21: Skeletons ‘in situ’ showing upper and lower individuals.....	27
Fig. 22: Bone collagen stable isotope results.....	29
Fig. 23: Enamel carbonate stable isotope results.....	30
Fig. 24: Metacarpal from Structure 1 with pseudopathology.....	31
Fig. 25: Mandible from Structure 7 showing teeth mostly destroyed by caries.....	33
Fig. 26: Periodontal disease in the maxilla from Structure 33/Lower.....	34
Fig. 27: Fused vertebrae from Structure 8.....	35
Fig. 28: Enthesophyte on right ulna from Structure 8.....	36
Fig. 29: Spondylolysis in the lumbar spine from Structure 7.....	36
Fig. 30: Os acromiale from Structure 33/Lower.....	37
Fig. 31: Height distribution of slaves from the area around Le Morne in 1826.....	42

## LIST OF TABLES

Table 1. Age and sex determinations of the individuals from the cemetery at Le Morne.....	32
Table 2. Dental pathologies at Le Morne.....	33

## SUMMARY

The report centres on the field survey undertaken between the 19<sup>th</sup> and 31<sup>st</sup> of July 2010 at the Le Morne Cemetery Site, Le Morne, Mauritius. The excavations were undertaken under the aegis and commission of the Truth and Justice Commission, Port Louis, with the express desire to gain a clear understanding of who was actually interred in the cemetery. Previous oral knowledge and conjecture regarding the site had suggested that the buried were of Malagasy origins; our principal objective was to clarify this issue given the significance of the site in relation to Le Morne UNESCO WHS. In addition to this main objective, it was anticipated that any remains recovered might be used within the framework of the 'Health Legacies of Slavery and Indenture' project directed by Mr Benjamin Moutou, with myself as team leader. The remit of this latter project was to better understand, through comparative study, the impacts (if any) of slavery and indenture on the health of the modern Mauritian population.

This site is remarkable. We have clear evidence relating to diet, health and working life. As significant, we have a unique and unparalleled insight into the life ways of an ancestral Mauritian community as it relates to death, burial and spiritualism. While it is unfortunate that in the absence of DNA evidence, we do not at this stage have conclusive evidence of the origins of those interred, we must not lose sight of the fact that this is a *first* for the Republic, and represents an invaluable step in linking the modern Mauritian population with its past.

Our main recommendations place emphasis on the need to carry out further excavation and analysis as this study has been most heavily hampered by a lack of samples. Given what this site and the interred remains represent, it is our sincere hope that further studies can be undertaken as these are essential for better understanding the site and the peoples buried.

## ACKNOWLEDGEMENTS

We must firstly acknowledge the support of the Truth and Justice Commission, particularly Prof. Alex Boraine, Dr Vijaya Teelock, Mr Benjamin Moutou, Mrs Colette Le Chartier, Mr Allan Charlot and Mr Satyendra Peerthum, all of whom provided much needed support and assistance. From the Le Morne Heritage Trust Fund (LMHTF), our sincere thanks to the Acting Chairperson, Mr Mathieu Leclé, whose support is gratefully acknowledged. Our work at Le Morne was facilitated by Mr Jean-Francoise Lafleur and Mr Stephan Dux of LMHTF, and many local participants, all of whose assistance we greatly appreciate. We are all thankful to Dr Anwar Janoo and the students of UoM, for assisting us so ably on many occasions, and Mrs Nelly Ardill and Mr Thierry Le Breton from SOS Patrimoine for both financial and logistical support. Our thanks to Mr Beebeejaun of the Mauritius Museum Council for kindly providing space for interim storage of the skeletal materials prior to analysis. We also gratefully acknowledge the assistance of Ms Sheila Thanoo of NHF for providing permissions and support throughout our venture, and Mr Choonee, Minister for Arts and Culture for quickly recognising the value of this site and immediately providing 24hr security. Our grateful thanks to Prof. Konrad Morgan, VC of UoM, for providing logistical support in storing and transporting the skeletal remains as well as providing facilities to study the remains.

## FUNDING BODIES

Funding for this seasons' work has been generously provided by, and gratefully received from: the TJC, LMHTF, SOS Patrimoine, the University of Mauritius, The British Academy, the University of Central Lancashire and the US State Office, Mauritius.

## TECHNICAL SUMMARY

Fieldwork was carried out between the 19<sup>th</sup> and 31<sup>st</sup> of July 2010 by a collaborating group of professional archaeologists from the University of Central Lancashire, University of Reading and University of Cambridge, UK; Università Ca' Foscari, Venezia, Italy and Inštitut za antropološke in prostorske študije, Ljubljana, Slovenia.

The excavation focused on the area that had previously been studied during the 2009 survey season, identified as the main cemetery site. The cemetery itself is located on a small sandy islet, which is regularly cut-off from the mainland as a consequence of tidal oscillations. Based on current evidence, the site appears to be divided into three sections, a main central burial area that is approx. 20m x 25m aligned north-south along the longest axis (with the supposed entrance due north). This is orbited by two apparent satellite areas, each considerably smaller, and measuring approx. 5m x 6m to the east and 5m x 5m to the west of the main area.

The 2009 field season deemed the cemetery site particularly suitable for geophysical survey as the graves were constructed using basalt, a highly magnetic material, set in natural sand geology that is magnetically quiet. Grids of 10 x 10 metres were laid out using a Leica 700 series Total Station. The graves themselves were delineated by basalt rock. These delineations, of varying sizes, were proportional to the interred, i.e. smaller graves denoting infants, larger graves for adults. Due to the location, but more importantly the sensitive nature of the site, no mechanical equipment was used for site clearance; a more sympathetic approach based on hand clearance was preferred.

Following excavation, 11 complete or near complete skeletons were recovered. The skeletons were in a variable state of preservation. Most were moderately well preserved, but there was some loss of the bone surfaces in all individuals and most had some erosion of articular ends. One inhumation, Structure 33, had been adversely affected by the burrowing action of the large land crabs that inhabit the sand bank. The burials were primary inhumations of intact individuals and there is no indication of any secondary practices such as disarticulation or deliberate movement of individuals after decay. The main report deals predominantly with the results from these finds. Osteological, isotopic and DNA analysis were undertaken to establish basic details relating to the age, sex, stature and physical condition of the interred. More detailed analysis also revealed aspects of occupational and physical stresses, as well as diet.

Unfortunately, the DNA analysis has proved unsuccessful. This was to be anticipated given the fact that the region is tropical, and the bones have been immersed in seawater. However, this situation has hampered our abilities to assign racial affinity; it would be highly beneficial to take further cranial measurements and carry out morphometrics investigations (recommendation 2, below) although this should be performed in tandem with further excavations, as the sample we have presently is not statistically viable.

Of the 11 skeletons recovered, six were juvenile and five were adults. This is a relatively high proportion of juvenile remains compared with adult, even taking into account the potentially higher likelihood of infant mortality in antiquity. While sexing of juvenile remains is problematic, it was possible to assign sex to the adults, with four females / possible females and one possible male.

Of the 11 individuals analysed, three were either late-term fetuses or stillbirths, whilst a further three were under five. No older children were identified. Three of the females were within their childbearing years. The individual from structure 1 was buried with a foetus between her legs and may have died in childbirth



In general, there were few indications of dietary stress; thus it can be concluded that while the diet of these individuals may well have been basic, it was adequate. This point having been made, the stature of the individuals was relatively small.

In terms of health, the highest prevalence of identifiable disease occurred as dental conditions: caries and abscesses present in the mouth. This would suggest that, in combination with a diet rich in simple sugars, oral hygiene was poor, this latter point further supported by the high incidence of calculus build up. Aside from this very specific typology of disease, one case of bone infection was noted, along with one possible case of bone breakage. This would seem to indicate an overall healthy population; however, given the small number of recovered individuals, we have to be cautious of over-emphasising the 'lack' of evidence suggestive of deleterious conditions. Further excavation and research would no doubt reveal a more detailed picture of the health of this population.

There were few indicators of working life. These usually take the form of evidence indicating over use of specific muscles; however, only two such examples were recorded from this assemblage. One further indication of a hard working life was noted from the spine of the female buried in Structure 7, which showed evidence of a healed fracture. The fact that females dominated the grouping studied may provide some explanation for the lack of heavy-work related conditions, perhaps indicating engendered work roles where women carried out less physically demanding work. Given the circumstances, this is unlikely to be the case. Women would more than likely have been involved in heavy, repetitive work. Although work division would have been based at least in part on gender, it is far more likely that we simply don't have a large enough sample to have noted the presence of work related conditions. The only male was also the oldest individual recorded, at least 40 years of age; he is therefore unlikely to be representative of the majority of male workers from the region.

Isotopic evidence was successfully studied and indicated a varied diet including both C<sub>3</sub> and C<sub>4</sub> resources. The former accounting for 95% of all plants, and includes, for example, rice. Plants from the latter tend to be adapted to arid environments and include crops such as maize, sugar cane, millet, and sorghum. Given the fact that sugar cane was not grown in the region at that time, and there is no historical evidence of millet and sorghum being grown in Mauritius at all, it would appear that maize was eaten in some quantities. This issue is not so clear-cut as these signals indicate the *protein* component of the diet; thus, we may be seeing an indication of people eating specific plants, or people eating animals that are eating these plants. Although the outcome is the same, the details are quite different. Further investigation, with larger samples, is essential to clarify this issue.

Finally, the question of whether these individuals migrated to Mauritius or were in fact born and raised on the island is still open to investigation. The evidence suggests that all individuals are from the same region; however, it is not clear precisely which region. In effect, the isotopic signal from Mauritius and Madagascar is too similar to be able to separate these regions.

## RECOMMENDATIONS

### 1. Dating:

Dating of the recovered finds should be carried out as soon as possible. Primarily, this will provide a scientific chronology for the site itself and its period of occupation in general terms. While we do have secure material evidence in the form of coins for dating, these were only recovered from one grave. Although the carbon dating curve (effectively the accuracy) is problematic for periods within the last 300 years, C14 dating would at least provide a clear date range for the sites use. Perhaps more important, dating the interred would allow us to

recognise variations in the dating profile across all the buried individuals. In other words, we would be able to study the relationship not only in terms of when the site was first used and when this ceased, but also if there is any variation in terms of *when* individuals were buried relative to each other. This may lead to a better understanding of the time frame of use of different parts of the site. However, it should be noted that this level of resolution might not be possible given the problems of dating remains from the last 300 years.

#### 2. Further osteological investigations:

Given the fact that the site, at present, appears not to have been conducive to preserving ancient DNA, it would be beneficial to carry out further, more detailed, osteological study. This should take the form of both traditional morphometrics and geometric morphometrics (the statistical analysis of shape). Traditional metric recording would potentially provide further evidence for racial affinity based on discrete measurements from the skull. Results from geometric morphometric study of the *shape* of the skulls could also potentially be used to better interpret race. These studies should be carried out as soon as feasible in order to provide this much needed evidence of racial affinity.

#### 3. Further excavation at the Le Morne Cemetery:

Considering the number of 'structures', the majority of which are likely to be graves, it is essential that further archaeological investigations of this site be undertaken. At present, we have a relatively small sample of interred individuals and it is patently clear that a numerous additional skeletons lie buried. The excavations have revealed only a small portion of the global assemblage of buried bodies, further study would help address some of the questions that have only been touched on given the small sample recovered to date, particularly those relative to health and lifestyle. At present, the recovered samples have little / no statistical validity, thus our conclusions are hampered. Additional samples would not only potentially reveal new evidence (i.e. conditions as yet unseen on bones we have recovered to date) but also add validity to current conclusions (i.e. diet requirements were sufficiently met so as not to cause detriment to health). Furthermore, with DNA in mind, excavations on another portion of the site may uncover remains that have not been subjected to waterlogging, and thus more likely to yield DNA.

#### 4. Further work within the region of the cemetery and Le Morne Brabant:

In terms of the Le Morne cultural landscape as a whole, it is strongly recommend that a large-scale survey of the area to the north and east of this site be undertaken to explore the lower slopes of the hills adjacent to the Le Morne Brabant. While the cemetery is of considerable significance with regard to the osteological evidence it has provided, it is essential that we have a clearer understanding of the cemetery's physical position within the landscape at the time of its use. We must also be aware that, even given the numbers of potential individuals buried (based on the structures revealed to date) this does not represent a large number of people. It is likely that other burial sites / settlements may be present within a relatively small radius of this site. Further geophysical survey would reveal any new settlements or archaeological features in the area, providing greater context to previous research on activity in the area.

#### 5. Excavations on sites providing comparable data:

The recovery of these finds has highlighted the need for further excavation. Of immediate relevance would be the study of sites that are likely to be contemporaneous with this cemetery, or that may provide further remains of slaves / freed slaves. Amongst these are sites such as the Jeannot Cemetery site, adjoining the Medine Sugar Estate. Following a site visit with members of the TJC and two archaeologists, myself and Dr Helen Farr, it was clear that this site had considerable potential for providing osteological finds. A comprehensive survey of the locations of these sites is essential, especially considering the fast pace of development in Mauritius. The sites themselves require in depth geophysical and field survey to record the



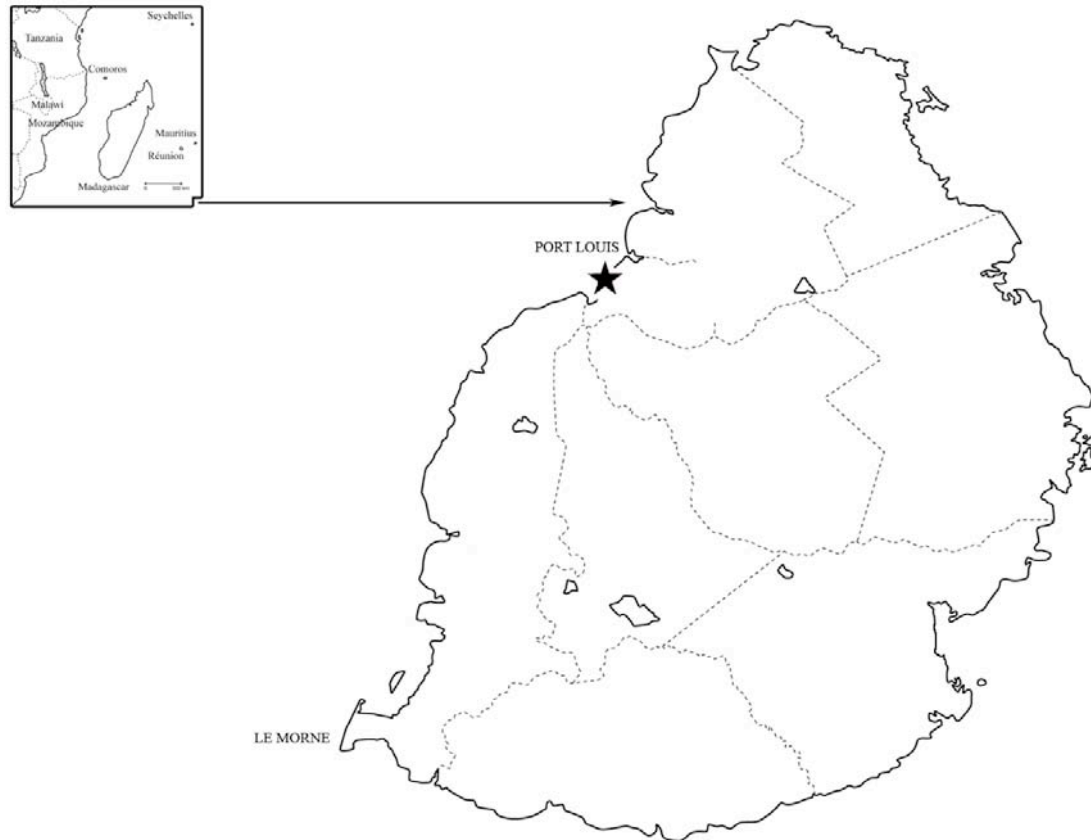
archaeological potential for each site. Excavation should then proceed to recover further evidence regarding health, diet, lifestyle and migration.

In concert with the above, it is essential that we add the ‘indentured’ component to the evidence derived from slaves. While we have not been able, at present, to categorically assign racial affinity to the interred from the Le Morne Cemetery, it is likely that this particular cemetery is the final resting place of people with either African or Malagasy origins. Given this, it is unlikely that they are representative of the majority of the modern Mauritian population. With over 70% of contemporary inhabitants brought to Mauritius as indentured labourers from various parts of India, it is thus an essential exercise to investigate the past health of this *specific* proportion of the modern society if we are to truly investigate the health consequences of slavery and indenture on the current population *as a whole*. Thus, key sites such as the cemetery at Bois Marchand should be a priority for future work so that a more complete record and understanding of Mauritius’ past population are achieved.

## 1.0. INTRODUCTION

The following report details the 2010 campaign of archaeological investigations undertaken at Le Morne Cemetery, Le Morne, Mauritius (fig. 1), under the commission of the Truth and Justice Commission, Port Louis, Mauritius.

**Fig. 1: Map of Mauritius (capital starred) and site location (Google Earth©).**



The site of Le Morne Brabant represents perhaps one of the most significant global commemorations to the memory of slave resistance. Not only does this site evidence a rich associated cultural and oral history within a local context, but it has recently been inscribed as a UNESCO World Heritage Site in 2008 precisely for its remarkable role within the maroon movement.

Fieldwork was carried out between the 19<sup>th</sup> and 31<sup>st</sup> of July 2010 by a collaborating group of professional archaeologists from the University of Central Lancashire, University of Reading and University of Cambridge, UK; Università Ca' Foscari, Venezia, Italy and Inštitut za antropološke in prostorske študije, Ljubljana, Slovenia.

The excavation focused on the area that had previously been studied during the 2009 survey season, identified as the main cemetery site. Two further 'satellite' regions were also included, which ultimately proved to be highly beneficial thanks to the identification of further interred remains.

### 1.1. Description of the Cemetery and Graves

The site could best be described as an abandoned, but not unused, cemetery. Although there are no apparent connections between the present population and the interred, the cemetery shows clear and unequivocal evidence of 'longanis' practices.

**Fig. 2: Site prior to clearance showing evidence of voodoo practice.**



The cemetery itself is located enigmatically in the shadow of Le Morne Brabant Mountain, on a small sandy islet, which is regularly cut-off from the mainland as a consequence of tidal oscillations. Based on current evidence, the site appears to be divided into three sections, a main central burial area that is approx. 20m x 25m aligned north-south along the longest axis (with the supposed entrance due north). This is orbited by two apparent satellite areas, each considerably smaller, and measuring approx. 5m x 6m to the east and 5m x 5m to the west of the main area.

Prior to excavation, and as one might expect in a tropical environment, the area was heavily overgrown with small trees, mostly acacia, shrubs and other low lying vegetation. Two larger, and considerably older, trees seemed to form a natural focal point for the central grave region. Evidence of current ritual practices was observed from remains of sacrificed chickens (fig. 2), portions of young pig, an abundance of coconuts, and copious small earthenware oil lamps. Other examples, more enduring and arguably less contemporaneous, were small dolls and bottle tops nailed into one of the larger 'focal' trees. Under the bottle tops were small pieces of cloth with the names of individuals written in ink; the ritual significance of these finds are complex, but are unlikely to have any particular connection with the interred individuals. Despite our greatest fear, only one of the graves was particularly disturbed, and none were robbed.

The graves themselves were delineated by basalt rock. These delineations, of varying sizes, were proportional to the interred, i.e. smaller graves denoting infants, larger graves for adults. This was not immediately obvious as the arrangement of stones was often disassociated and apparently ad hoc. While the majority of the graves were marked by relatively small-to-medium sized stones that showed little evidence of being tailored or fashioned (cut) in any way, the more prominent adult graves were delineated with cut basalt blocks. These were most likely brought to the site as waste building material and re-used for constructing the grave markers.

## 2. FIELDWORK PROCEDURE

The excavation procedure followed a basic hierarchical system. Individual stratigraphic units were defined as 'contexts'; a collection of associated contexts or artifacts were defined as 'features', and groups of features were defined as 'structures'. For the purposes of clarity and to facilitate recording and accession, each context was provided with a unique identifying index number (i.e. context number).

All grave fill contexts (sandy layers) were subject to 100% coarse dry-sieving, firstly through a 5mm mesh and then subsequently through a 3mm mesh. Due to logistical and time constraints it was not possible to carry out flotation for general biological analysis, although given the nature of the site this was not deemed particularly detrimental under the circumstances. All finds, including all osteological remains, were hand-collected.

### 2.1 Excavation Procedure

The 2009 field season deemed the cemetery site particularly suitable for geophysical survey as the graves were constructed using basalt, a highly magnetic material, set in natural sand geology that is magnetically quiet. Grids of 10 x 10 metres were laid out using a Leica 700 series Total Station. The station and grid points were later recorded with GPS for subsequent georeferencing. Since the common line of archaeological features (the graves themselves) were aligned roughly north west – south east, the base line was oriented east-west and the direction of traverse was north. The magnetometer survey of this site was successful in identifying surface and sub-surface archaeological features. The quiet magnetic signal of the sand in this area contrasts sharply with the dipolar anomalies created by the highly magnetic basalt stones used to construct the graves. In total, some 21 clearly defined sub-soil structures were identified following the 2009 geophysical survey.

Building on this in 2010, our first remit was to establish extent of the cemetery based on the preliminary results from the 2009 survey. This involved a concerted programme of site clearance, guided by the field archaeologists at all times, but heavily reliant on the efforts of local Le Morne and additional UoM volunteers. Due to the location, but more importantly the sensitive nature of the site, no mechanical equipment was used for site clearance; a more sympathetic approach based on hand clearance was preferred. Figures 3 and 4 demonstrate the extent and outcome of the work undertaken.



**Fig. 3: Site – prior to clearance.**



**Fig. 4: Site – post clearance.**



Following on from the site clearance a full archaeological reconnaissance of the site was undertaken, with very positive results. A further 24 ‘structures’ were discovered, bringing the total count of burial type features to 45.



The area of the excavation was set out using a Total Station Theodolite, with reference to the previous seasons survey strategy. Once georeferencing was complete, actual excavation was undertaken. The nature of the topsoil was comprised of a relatively loose amorphous substrate composed of loose-leaf litter and other vegetal matter. However, this rapidly gave way to a series of sandy layers that continued without a break through to the level in which we were able to recover osteological remains, some 90cm below topsoil level. Due to the nature of the sandy soil, all the graves were excavated in plan, where possible by context, but by spit were no clear contextual divisions were evident. Excavating by spit effectively means that soil is carefully removed by standard units (e.g. 20cm) down to the level of finds. Throughout the process a photographic log was maintained, with images taken of each skeleton whilst *in situ* before lifting.

### 3. FIELDWORK RESULTS

All 45 structures were cleared of vegetation, recorded and georeferenced; a total of eight were actively excavated resulting in the recovery of 11 entire skeletons, the analysis of which form the bulk of the remainder of this report.

Very few additional finds were made with the skeletal remains, although notable exceptions include a series of buttons, a small collection of French coins and a glass bottle. A spade and hoe were also recovered just below the topsoil layer of grave 8. There was limited remaining evidence of the actual mode of interment, although ephemeral residues of ostensibly well-constructed coffins were revealed by careful excavation (see fig. 5 below).

**Fig. 5: Coffin outline evident in grave no: 29, as revealed through careful excavation.**





### 3.1 Summary of Excavated Graves

Grave no. 01:

A rectangular 'frame' constructed of basalt and coral, and held together with a lime mortar, delineated this grave (fig. 6). A number of the basalt block, mainly those at the corners of the frame, were cut. Beneath these blocks was a dark brown layer of topsoil, which was heavily overgrown with a network of roots. The fill of the grave comprised three sandy layers, alternating from light grey to light beige in colour and with decreasing vegetal matter at lower depths. At the lowest context a coffin with the skeleton of an adult and a juvenile (neonate) were recovered (fig. 7). The remnants of a wooden coffin were visible as a darker outline, detectable in the lighter sand deposit; the remains of the metal elements of the coffin, ostensibly iron nails, were also recovered. The adult skeleton's head was positioned to the left. Some bones of the right foot were displaced from the original position otherwise the skeleton was complete. The placement of the arms of adult skeleton suggests that they were crossed at the abdomen at the time of burial. The remains of the juvenile were positioned between the legs (knees) of the adult, with the head towards the feet of the adult. The level of ossification of the juvenile bones was at an underdeveloped stage and the remains were thus very fragile and not preserved as a full complement.

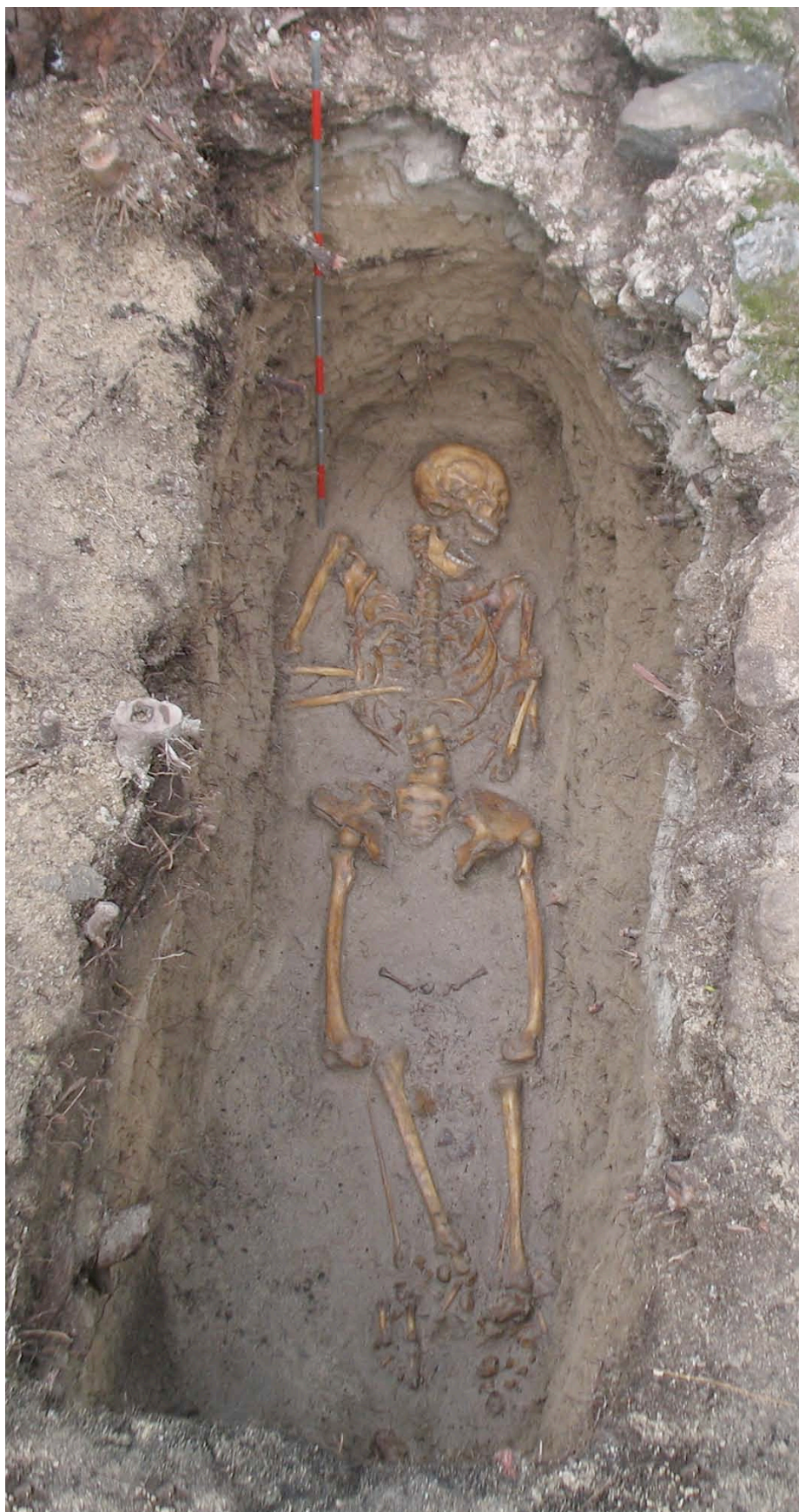The grave contained no finds other than human bones, metal remnants of the coffin and a set of round buttons made from mother of pearl, indicating that one or both of the interred individuals was clothed when buried.

**Fig. 6: Layout of grave no. 1.**





**Fig. 7: Position of both skeletons 'in situ', foetal body is in opposing direction to adult.**



Grave no. 06:

The size of the rectangular basalt stone covering the grave suggested this was a small inhumation (fig.8). Under the basalt, a dark brown layer of soil was present, overlaying three layers of sand, altering in colour (light beige to dark grey) and moisture content (dry to wet) with increasing depth. The lowest sandy layer contained two skeletons of newborn juveniles, with their head orientated to the east (fig.9). During excavation, traces of a rectangular coffin were detected as a residual variation in substrate colouration; metal finds (nails) were also recovered towards the distal (feet) end of the coffin. A stone plate was also recovered, covering the head of one of the skeletons, and possibly part of burial practice.

**Fig. 8: Basalt structure of grave no. 06.**



**Fig. 9: Skeletons 'in situ'.**





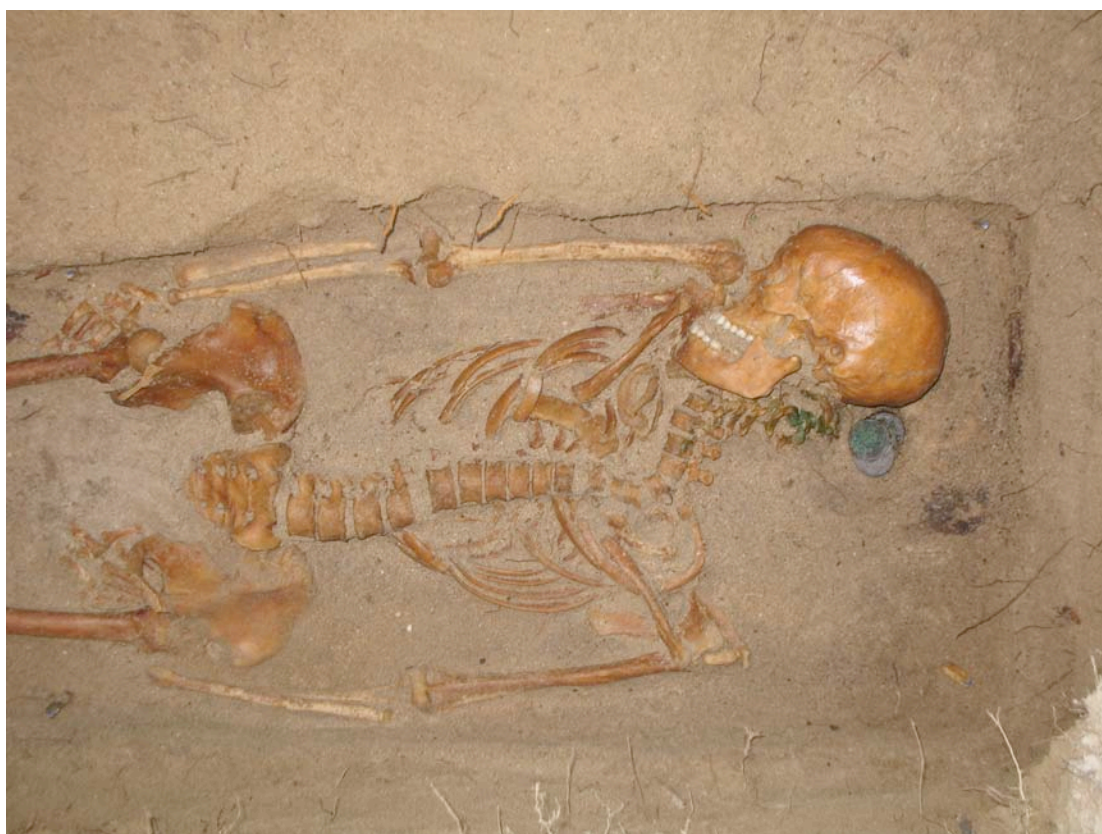Grave no. 07:

This grave was delineated by a series of four rectangular structures, all comprised of basalt, and laying at different stratigraphic levels (fig.10). Those basalt stones on the surface (contemporary structure) were lime mortared; the blocks themselves had been cut, most likely indicating that the structure was comprised from reused building material. The position of the top row of stones did not align to the position of lowest row. After the top organic dark brown soil was removed, within the stone frame of the grave, some ritual objects were found, pertaining to the modern times. Five sandy layers filled the grave, with the lowest containing the remnants of a wooden coffin, visible as a series of darker outlines within the sand deposit delineating the wooden frame of the coffin. Portions of wood from the coffin were recovered, along with eight metal elements (iron nails). The adult skeleton faced Le Morne Mountain (fig.11). The skull was turned to the right and most of the long bones were displaced from their original place, but in correct anatomical position. Under the skull a fabric bag was recovered containing four silver coins.

**Fig. 10: Basalt structure of grave no. 07.**



**Fig. 11: Skeleton 'in situ' with detail of grave goods (coins) under the cranium.**



Grave no. 08:

Based on the size of the basalt structure outlining this grave, it was assumed to be the grave of an adult. Basalt stones were positioned on the topsoil to form a rectangular outline (fig.12). The stones had no mortar linking them together, resulting in two gaps of missing stones. Under the topsoil, a sandy layer covered a second basalt grave outline. The position of this second tier of basalt was not aligned with the upper layer or directly with the inhumation. The second layer of stones was smaller, more tightly positioned, and was most likely the original surface marker of the grave. The first sandy layer under the second stone structure contained two artefacts, a shovel and a hoe, which were not part of the original grave deposits, but were placed subsequently. A second sandy layer under the second stone structure contained remnants of a coffin (evident as a darker substrate layer), six iron nails, two of which retained remnants of the wood coffin. The bones of a well-preserved adult were recovered, with the head facing Le Morne Mountain (fig.13). In addition, a set of round buttons, made from mother of pearl, was recovered which indicate that the interred was clothed when buried.



**Fig. 12: Basalt structure of grave no. 08.**



**Fig. 13: Skeleton 'in situ'.**





Grave no. 25:

A smaller rectangular basalt stone structure, next to grave no. 07, indicated that there was a child buried next to an adult (fig.14). The top organic soil covered the sandy fill of the grave, which was comprised of three sandy layers. The last sandy layer contained the remnants of a wooden coffin and a juvenile skeleton (fig.15). The bones were well preserved, although the skull was highly fragmented. Interestingly, and mimicking a number of the other graves the top stone structure lay in a completely different orientation to the interred individual. The surface structure was facing Le Morne Mountain, while the remains were orientated towards the south.

**Fig. 14: Basalt structure of grave no. 25.**



**Fig. 15: Skeleton 'in situ'.**



Grave no. 29:

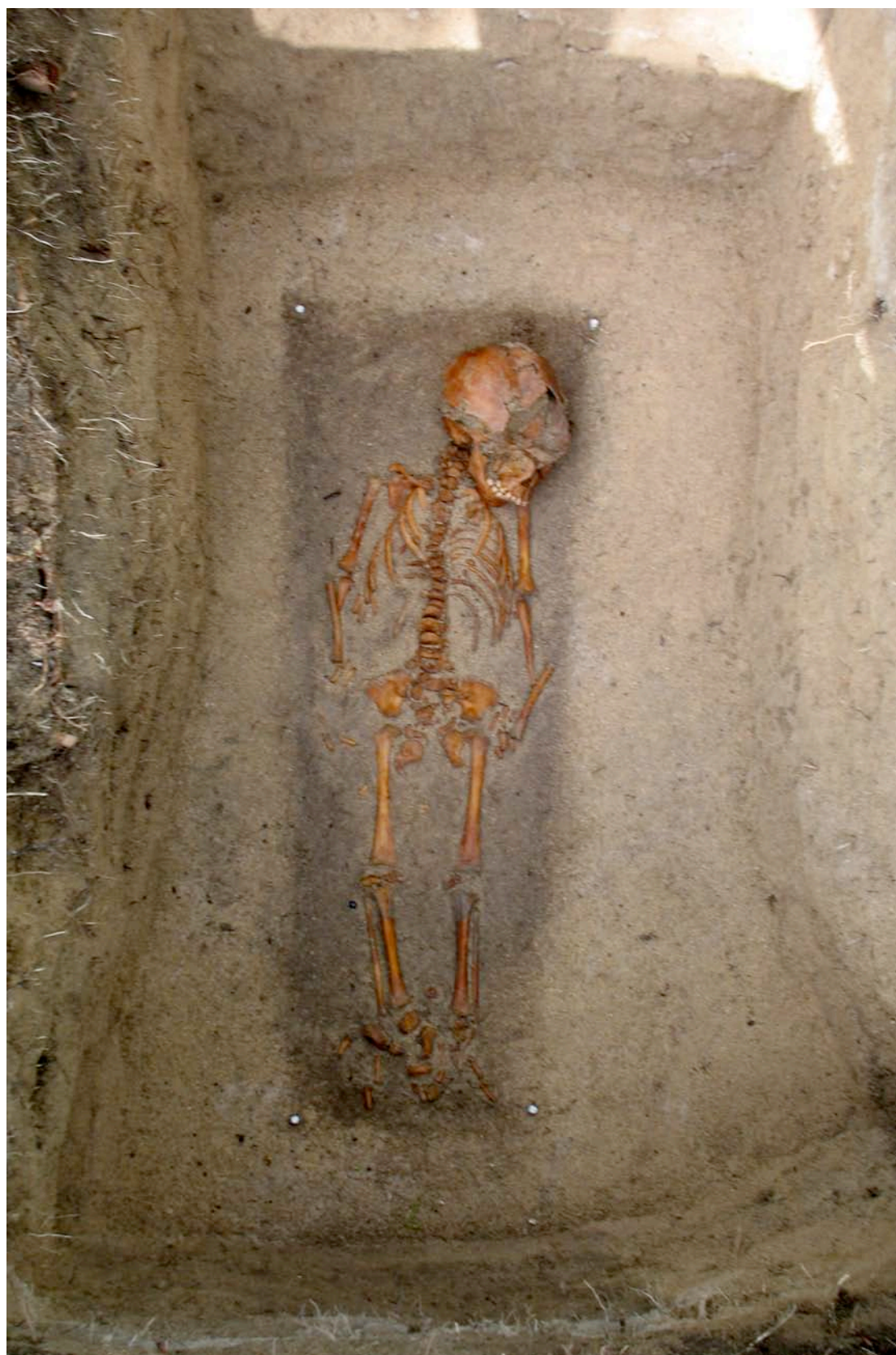A crudely oval basalt structure with two stones placed in the middle, presumably cutting it into two halves, delineated this grave (fig.16). As with many of the graves, modern coins, earthenware oil lamps, thin red and white candles, parts of sacrificed animals, and plastic bags, were spread on and around the structure, leftovers of ritual practices performed on the cemetery. Under the first stone structure was an organic, dark brown soil, which contained a network of tree roots. A second stone structure, more rectangular in shape, was noted beneath the topsoil layer. The rectangular basalt structure seemed to be composed of 2 similar parts, with a gap of 20 cm separating them. At the time of excavation this suggested that two juvenile burials were in this grave. Both parts were mortared on the tops and between the stones. Under the second stone structure was a visible cut for the grave, filled with four sandy layers. The last contained traces of a coffin (noted as a darker outline in the deposit), two iron nails and a well-preserved juvenile skeleton (fig.17). Two round, mother of pearl, buttons were also recovered.

**Fig. 16: Basalt structure of grave no. 29.**





**Fig. 17: Skeleton 'in situ'.**





Grave no. 30:

A small rectangular basalt structure on the surface suggested that this was a child's grave (fig.18). Under the basalt structure, which was disturbed by a tree trunk, a dark brown layer of soil was present. This organic layer, full of roots, covered the grave cut, which was filled with two sandy layers. The second contained a juvenile skeleton, with the head turned to the right and the arms crossed at the abdomen (fig.19). This grave was originally dug deeper than others, reaching a depth of 1.20m. Due to this greater depth, the interred was submerged at high tide, which made of this grave very difficult.

The orientation of the surface stone structure and the alignment of the skeleton differed for approximately 45 degrees. The stone structure was oriented toward west while the skeletons alignment was more toward Le Morne Mountain. Two small round buttons made from the mother of pearl were recovered from this grave.

**Fig. 18: Basalt structure of grave no. 30.**





**Fig. 19: Skeleton 'in situ' showing waterlogging that occurred at hightide.**



Grave no. 33:

The basalt structure on the surface of this grave was damaged; although it was clear that it had a rectangular shape at its origin and that it was oriented toward Le Morne Mountain (fig.20). The grave occupied what was apparently the centre of the cemetery thus making it a focus for modern ritual practices. This resulted in copious quantities of modern objects being discarded on and around the grave. As the stone structure was damaged, with numerous stones missing, it was initially suspected the grave had been looted and any remains robbed.

The first substrate layer, which in the other graves had been composed of dark brown topsoil, here contained a mixed dark brown soil and light beige sand with a considerable quantity of admixed modern material from recent ritual practices. This disturbed deposit was thick,



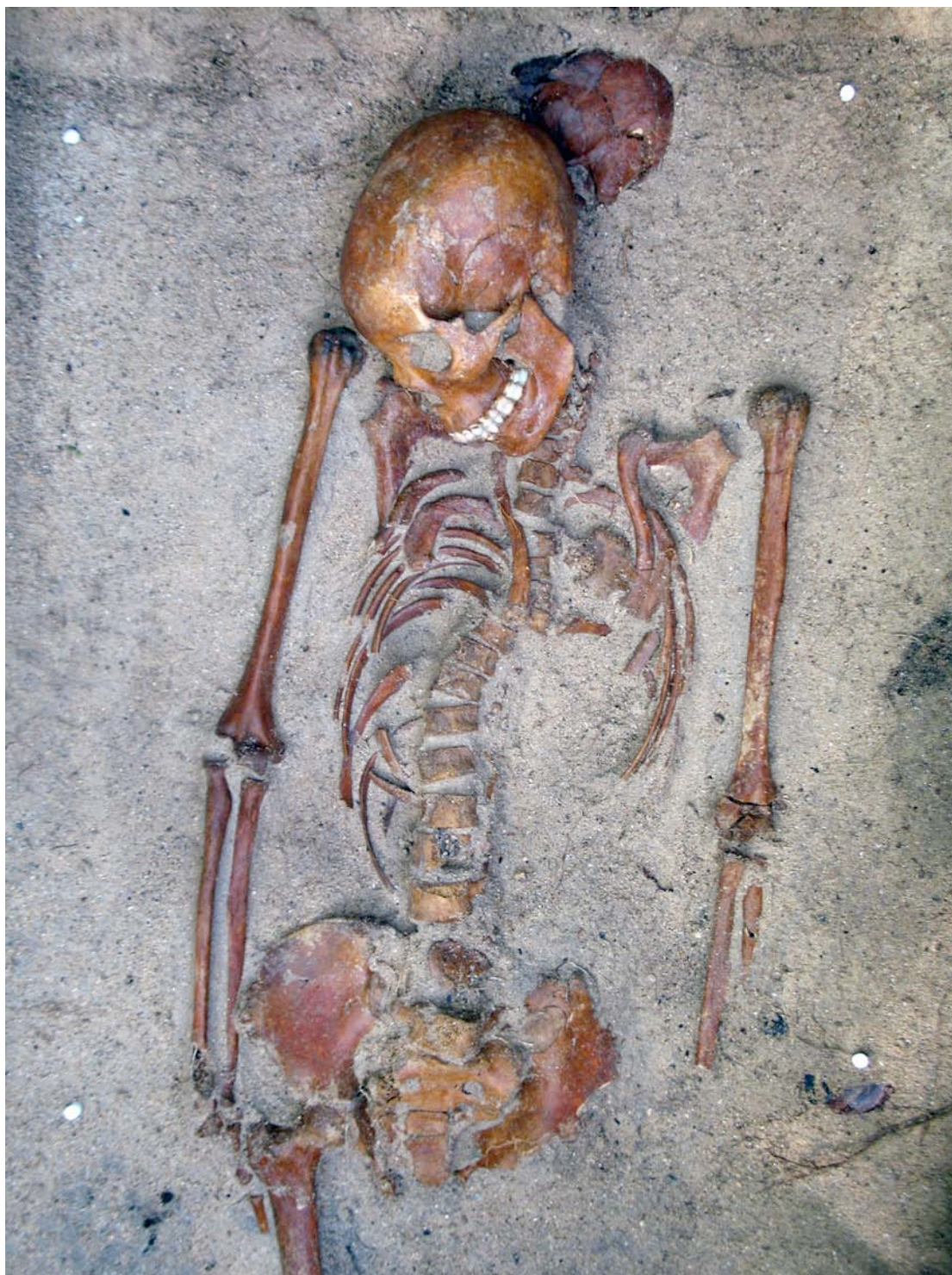reaching a depth of 50cm. Establishing who / what was responsible for the disturbed state of this grave was difficult as there was evidence of both animal (crabs) and human intervention. Under this mixed layer the cut for the grave was visible, again differing considerably from the orientation of the surface structure. The cut for the grave was filled with a sandy layer; at a depth of 90 cm from the surface an adult human skeleton was recovered, facing Le Morne Mountain. All the bones were well preserved. Under the skull was a dark green, glass bottle of unknown origin. Upon lifting of this skeleton (grave 33 UPPER), another became visible directly beneath the first (grave 33 LOWER) (fig.21). The second adult skeleton was aligned and positioned in a near identical position to the first adult, with the exception that the arms crossed on the abdomen, while the arms of the upper skeleton were positioned parallel to the body. Almost all the bones of the lower skeleton were preserved, except the long bones of the left arm, which were missing apparently as a consequence of crab activity.

**Fig. 20: Basalt structure of grave no. 33.**





**Fig. 21: Skeletons 'in situ' showing upper and lower individuals.**



#### 4. POST-EXCAVATIONAL ANALYSIS

The following details the post excavation analysis of the skeletal finds. One facet of these post excavation research, commissioned by the Truth and Justice Commission and undertaken by Dr Will Goodwin of the University of Central Lancashire, is not presented herein. The analysis of aDNA, regrettably, was unsuccessful. Tropical locations are notoriously poor at preserving ancient DNA; furthermore, the fact that the skeletons themselves would have been cyclically submerged in seawater is likely to have had a deleterious effect on any DNA.

The 11 skeletons recovered consisted of six juvenile and five adult individuals. Aside from the actual details of recovery, the most significant information regarding the skeletal finds has been derived from osteological analysis, detailing demography, indicators of health and evidence of lifestyle. Corroboratory evidence regarding diet and migration has been provided by bone collagen and enamel carbonate isotopic analysis.

#### 4.1 Post-excavational Techniques

##### *4.1.1 Isotopic Methods*

Carbon and nitrogen stable isotope analysis was carried out on the rib bones of ten individuals from La Morne cemetery and one deer mandible (a faunal component is key for providing corroboratory data). Five of the individuals were adults (2 females, 2 probable females and 1 probable male), 3 were children and 2 were peri-natal infants at the time of death (Appleby, this report). The collagen results from the peri-natal samples will reflect the diets of their mothers and are thus included in the analyses below. Collagen was extracted using the standard methodology of the Dorothy Garrod Laboratory, University of Cambridge, based on the method described in Privat et al (2002). All of the collagen was deemed to be of good quality as it fulfilled the following criteria: an atomic C:N ratio of 2.9 to 3.6 (De Niro 1985); a 'collagen' yield of >1% by mass; final carbon yields of >13%; and final nitrogen yields of >4.8% (Ambrose 1990). Each sample was analysed in triplicate and the mean results are presented below (4.2.1).

Seven of these individuals were also sampled for tooth enamel carbonate. The five adults and two of the children were sampled for tooth enamel carbonate. A variety of teeth were sampled and it should be noted that some of the samples are likely to show the fractionation effects of breastfeeding.

The sample size was too small for reliable statistical analyses.

##### *4.1.2 Osteology Methods*

Of the 11 recovered skeletons, two skeletons were initially carefully washed; however, as the matrix was largely sand, it was found that cleaning could be as effectively achieved by dry brushing, so the remainder of skeletons were cleaned using this technique by Drs Anwar Janoo and Joanna Appleby, and a team of students from the University of Mauritius. This had the advantage of reducing the potential for fungal growth on damp skeletal remains.

The skeletons were examined following the standard procedures recommended by Buikstra and Ubelaker (1994), although with some amendments. The presence and degree of completeness of all skeletal elements was systematically recorded. Age of sub-adult individuals was determined by development and fusion of the long bones and cranium, long bone length, and dental development after Ubelaker (1989). Infant age was calculated from long bone length using the linear regression equations of Scheuer *et al.* (1980). Adult age was determined following the recommendations of O'Connell (2004), with the auricular surface of the ilium recorded following the modified method of Buckberry and Chamberlain (2002). Dental wear was recorded using the Smith (1984) and Scott (1979) guidelines, but was not used to determine adult age as so little is known about wear rates in this skeletal population. Pubic symphyseal ageing followed the criteria of Brooks and Suchey (1990), although the pubic symphysis was preserved in only one individual from this assemblage. Although cranial suture closure was recorded by the method advocated by Buikstra and Ubelaker (1994), it was regarded only as a very general indicator of age. Measurement of adult remains follows the criteria of Martin (1957), whilst non-metric traits were recorded according to Buikstra and Ubelaker (1994). Juvenile measurements follow the criteria of Fazekas and Kosa (1978). Adult sex was determined by sexually dimorphic features of the pelvis and skull,

measurement of the humeral and femoral heads and general assessment of robusticity, in declining order of reliability. The sex of subadults cannot be reliably determined from the skeleton.

All pathological conditions were noted, photographed and recorded in detail. All pathological bones were examined under x10 magnification and x-rays taken wherever this would aid in interpretation. Traumatic lesions were recorded according to the criteria of Lovell (1997), whilst diagnosis of possible infectious conditions followed Rogers and Waldron (1989). Recording of arthropathies followed the recommendations of Rogers and Waldron (1987; Waldron 1995). All long-bones of individuals older than neonatal were x-rayed and examined for traces of growth interruption (Harris) lines.

Stature estimation in adult females followed the recommendations of Trotter and Gleser (1977) for Black Males and Females. Where possible, the equations for the femur were used. Where the femur was not present, equations for other long bones were used. Stature estimation of infant and children is unreliable from skeletal remains (Lewis 2007: 77) and so was not attempted for this population.

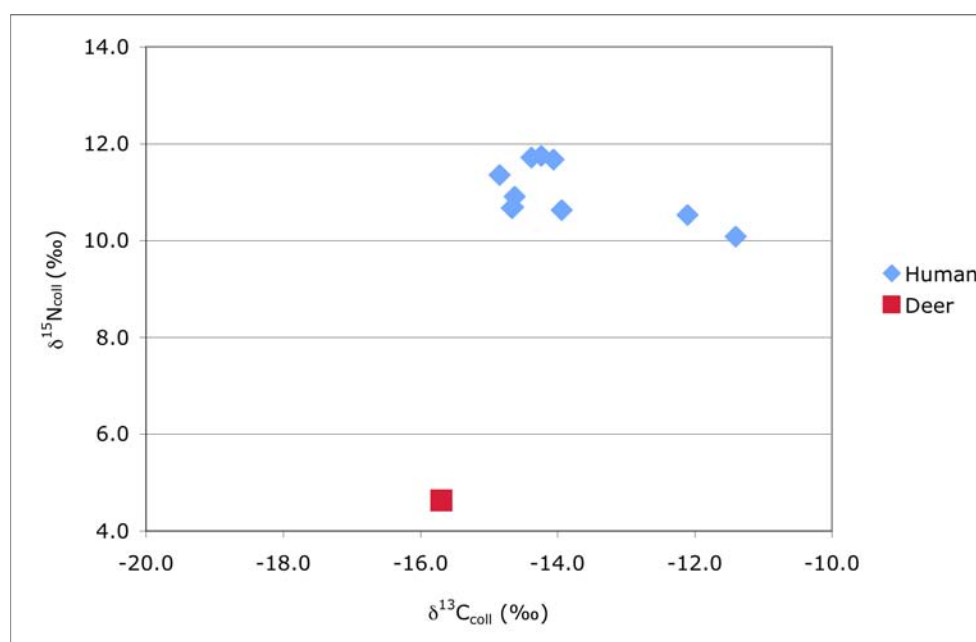
## 4.2 Post-Excavational Results

### 4.2.1 Results of Isotopic Analysis

The deer sample has collagen isotope values of  $\delta^{13}\text{C}_{\text{coll}} = -15.7\text{‰}$  and  $\delta^{15}\text{N}_{\text{coll}} = 4.6\text{‰}$ . This suggests that the deer consumed a mixed diet including both C3 and C4 plants.

The human collagen carbon isotope results range from  $-14.9\text{‰}$  to  $-11.4\text{‰}$  (range =  $3.5\text{‰}$ ) and have a mean  $\delta^{13}\text{C}_{\text{coll}}$  value of  $-13.9\text{‰}$  (sd =  $1.2\text{‰}$ ) (fig. 22). Both the standard deviation and the range of the human  $\delta^{13}\text{C}_{\text{coll}}$  results are large. Two outliers can be identified: grave 25 which lies more than 1.5 times the inter-quartile range above quartile 3; and grave 33/U which lies more than 3 times the inter-quartile range above quartile 3. When these outliers are excluded the range ( $0.9\text{‰}$ ) and standard deviation ( $0.3\text{‰}$ ) of the carbon isotope results are relatively small.

**Fig. 22: Bone collagen stable isotope results.**



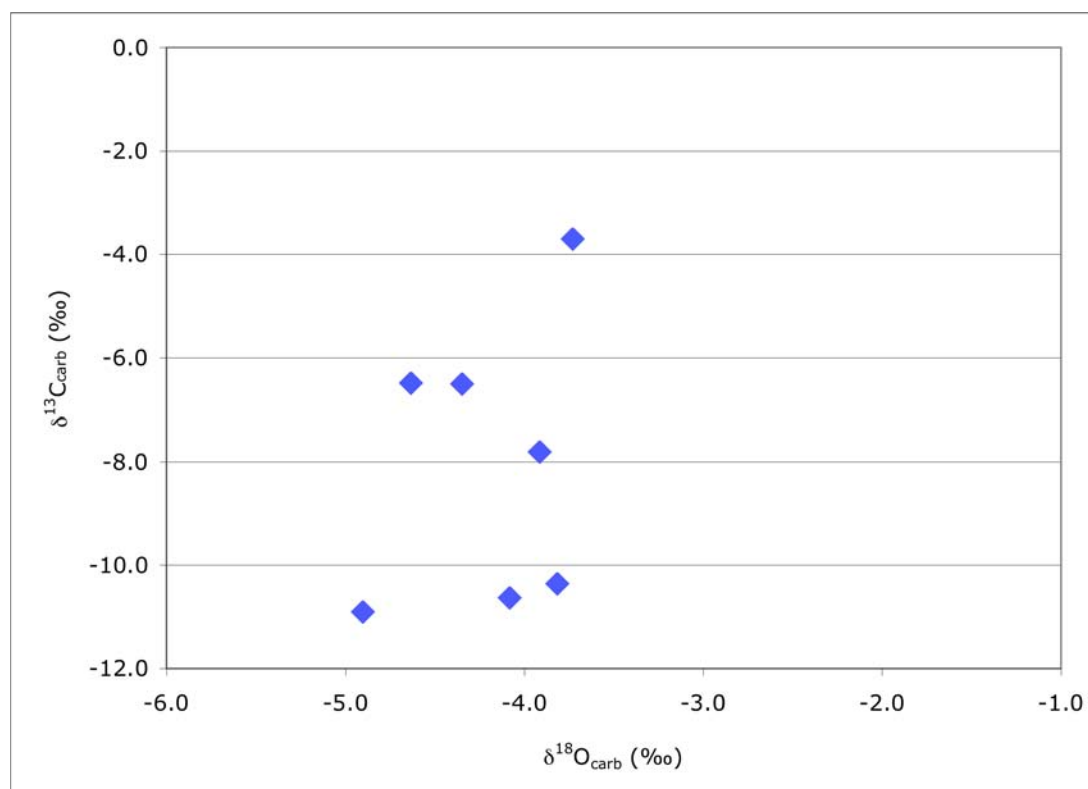


The human collagen nitrogen results range from 10.1‰ to 11.8‰ (range = 1.7‰) and have a mean  $\delta^{15}\text{N}_{\text{coll}}$  value of 11.0‰ (sd = 0.6‰). The standard deviation and range of the  $\delta^{15}\text{N}$  results are not as large as those of the  $\delta^{13}\text{C}_{\text{coll}}$  values, and decrease less when the two outliers are excluded (sd = 0.5‰; range = 1.1‰).

The tooth enamel carbon isotope results range from -10.9‰ to -3.7‰ (range = 7.2‰) and have a mean value of  $\delta^{13}\text{C}_{\text{carb}} = -8.1‰$  (sd = 2.7‰) (fig. 23). This is a notably large range of variation for a sample of this size.

The tooth enamel oxygen results range from -4.9‰ to -3.7‰ (range = 1.2‰) and have a mean value of  $\delta^{18}\text{O}_{\text{carb}} = -4.2‰$  (sd = 0.4‰).

**Fig. 23: Enamel carbonate stable isotope results.**



#### 4.2.2 Osteological Findings

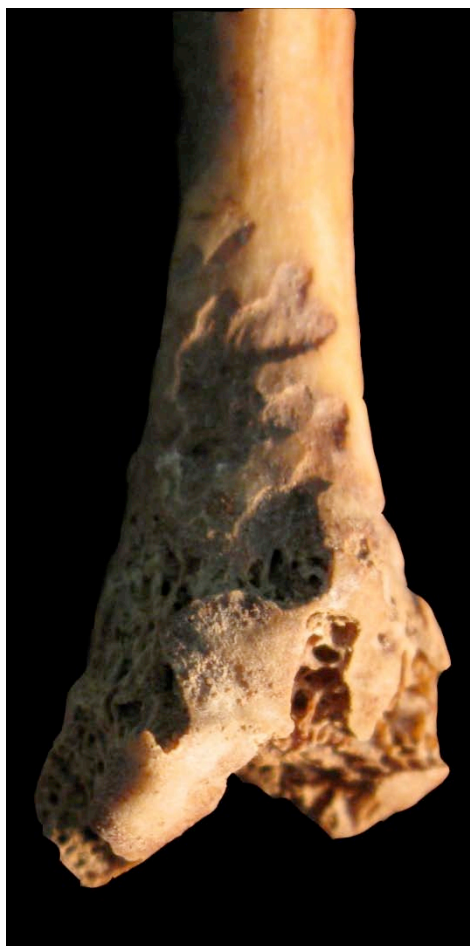
The skeletons were in a variable state of preservation. Most were moderately well preserved, but there was some loss of the bone surfaces in all individuals and most had some erosion of articular ends. Probably as a result of the thorough excavation technique and sieving, the percentage of the skeleton recovered was generally high. Where elements are missing it is probably as a result of preservational factors rather than bones being overlooked.

The burials are primary inhumations of intact individuals and there is no indication of any secondary practices such as disarticulation or deliberate movement of individuals after decay. Damage to bones can generally be attributed to in-ground soil conditions rather than human action. There are no peri-mortem or immediately post-mortem fractures.

One interesting taphonomic feature is the presence of globular-shaped destruction of the outer bone table on the surface of some bones from Structure 1/A (fig. 24). This feature initially looked like a pathological condition affecting the distal ulna and the proximal second metacarpal, but analysis under x10 magnification showed no sign of bony reaction. Similar

features were observed on the shaft of the left femur from Structure 33/Lower. Structure 33 was very disturbed by the actions of burrowing land crabs (*Cardisoma carnifex*), and it is possible that the surface damage represents scavenging by these animals.

**Fig. 24: Metacarpal from Structure 1 with pseudopathology.**



#### **4.2.1.1 Demography**

Ages and sexes of the skeletons from Le Morne are set out in table 1 (below). Although the sample size is small and it is therefore difficult to draw conclusions about population structure, there are nevertheless several features worth noting. Of the 11 individuals analysed, three were either late-term foetuses or still births<sup>1</sup>, whilst a further three were under five. No older children were identified. Of the adults, three were females in their child-bearing years. This gives an overall rate of childhood mortality of over 50%. The individual from structure 1 was buried with a foetus between her legs and may have died in childbirth (see discussion section for further comment on this individual).

---

<sup>1</sup> Ages of foetuses and neonates were calculated from the length of long bones according to techniques developed on modern Western populations. Given the small sizes of Le Morne adults, it is possible that babies in this population would have been smaller than their Western counterparts, with the corollary that the calculations are systematically under-estimating age.

**Table 1. Age and sex determinations of the individuals from the cemetery at Le Morne**

Structure No.	Approx. Age	Sex
1A	17-19 years	F
1C	33-35 weeks gestation	-
6/7	36-40 weeks gestation	-
6/8	37-41 weeks gestation	-
7	25-30 years	F
8	40+	?M
25	3-5 years	-
29	2-4 years	-
30	3-4 years	-
33/Upper	25-30 years	?F
33/Lower	Middle-older adult	?F

Stature could be calculated for four of the five adult individuals. Female and possible female stature ranged from 155 to 161 cm, whilst the possible male had a reconstructed stature of 163cm.

#### 4.2.1.2 Nutritional deficiency and non-specific stress

Conditions that might indicate dietary insufficiency or non-specific stress include scurvy, rickets, cribra orbitalia, enamel hypoplasias and Harris lines on long bones. Scurvy and rickets both result from specific vitamin deficiencies, of vitamin C and D respectively. Neither of these conditions was observed in the skeletal remains from Le Morne. Cribra orbitalia was also absent. This condition is typically associated with iron deficiency anaemia, either due to dietary insufficiency, illness or parasitic infection. Although numbers are small, the lack of these conditions may indicate a relatively good diet for this population. Despite taking x-rays of all available long bones, Harris lines, which indicate periods of growth interruption, were also absent from the Le Morne skeletons. In the older adults it is possible that Harris lines would have been obscured by skeletal remodelling, but it is to be expected that they would be visible in the younger adult and juvenile remains. Enamel hypoplasias, which like Harris lines show periods of growth interruption, but which are not subject to remodelling, were observed on the teeth of two of the younger individuals: the females from Structure 1 and Structure 7. Although none were observed in the teeth of the older individuals, this does not prove that they were originally absent in all cases as many teeth had been lost and the majority of remaining teeth had at least some degree of calculus formation which could have obscured lesions.

#### 4.2.1.3 Dental disease and caries

Dental caries results from the action of bacteria on the tooth surface which ferment simple carbohydrates from food (Roberts and Manchester 2010: 65). This process produces acids which eventually cause cavities. Caries rates are thus often used as a proxy for the levels of simple carbohydrates in the diet. At Le Morne, 7.14% of preserved adult teeth had carious lesions, distributed between three individuals (Table 2). The actual number of teeth affected by caries was probably in reality slightly higher as the two older adult individuals had both lost a considerable proportion of their teeth before death (8 in the case of Structure 33/Lower and 21 in the case of Structure 8). It is probable that a good proportion of the tooth crowns had been destroyed by caries. This process can be observed on the molars of the 25-30 year old woman from structure 7, who had three teeth where the crown had been almost entirely destroyed by caries (fig. 25). Interestingly, caries were not limited to the adult section of the population. The child from structure 29 had a carious lesion on the interproximal surfaces of both upper central incisors. These teeth had been in wear for a maximum of three years at the time of death, which suggests that the child must have had a significantly cariogenic diet.

In addition to caries, abscess cavities were observed on both of the older individuals. That on

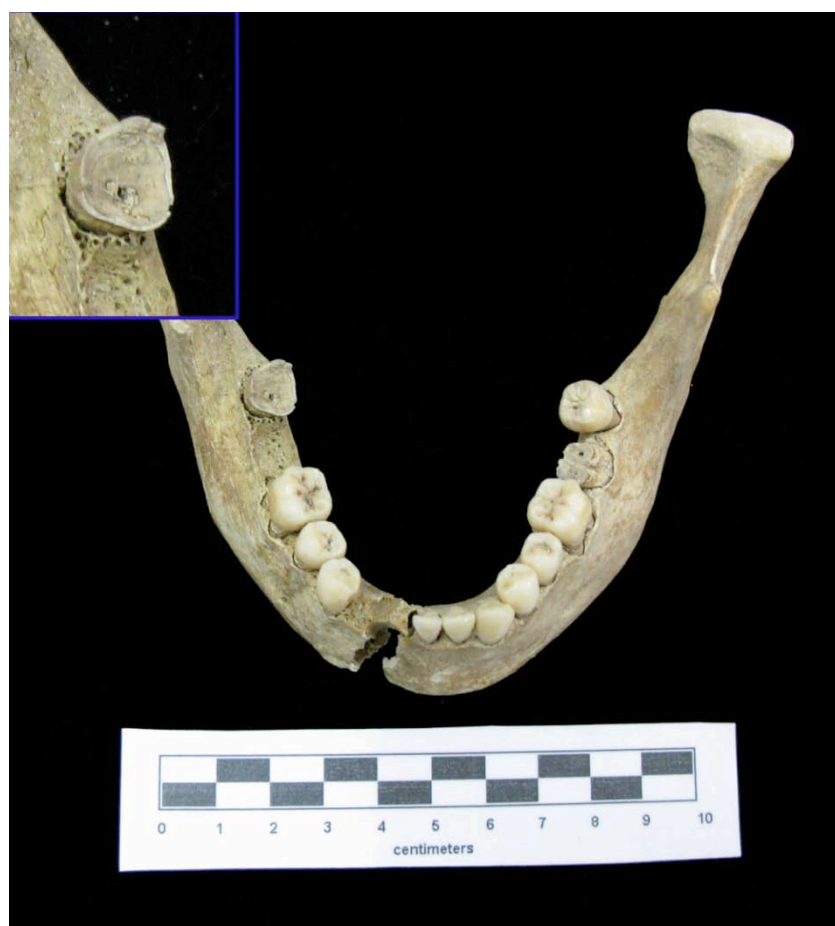

the lower individual from structure 33 showed evidence of active infection at the time of death. Calculus was also present on the teeth of all adults and on those of the 3-4 year old child from Structure 30, suggesting that dental hygiene was poor. The lower individual from structure 33, an older adult possible male, also showed evidence of periodontal disease that had caused up to 3.7mm of alveolar resorption (fig. 26).

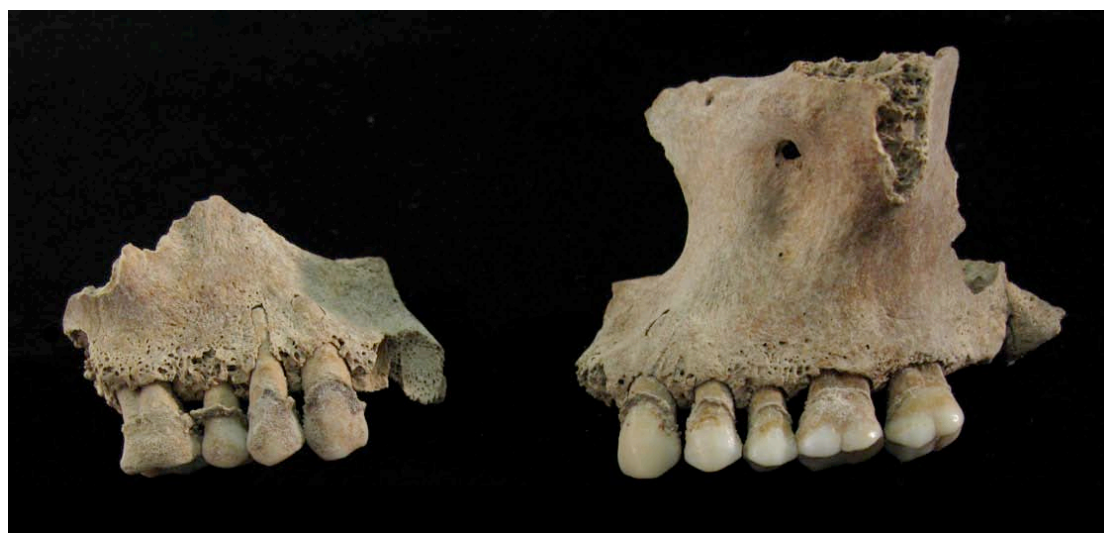**Table 2. Dental pathologies at Le Morne**

Structure No.	Age	Teeth present	Teeth lost <i>ante mortem</i>	No. of teeth with caries	No. of abscesses	Calculus	Enamel hypoplasia
1	17-19	32	0	0	0	Y	Y
7	25-30	27	2	6	0	Y	Y
8	40+	10	21	0	1	Y	N
25	3-5	18	-	0	0	0	N
29	2-4	17	-	2	0	0	N
30	3-4	17	-	0	0	Y	N
33/Upper	25-30	27	0	0	0	Y	N
33/Lower	Middle -older adult	16	8	2	2	Y	N

**Fig. 25: Mandible from Structure 7 showing teeth mostly destroyed by caries.**



**Fig. 26: Periodontal disease in the maxilla from Structure 33/Lower.**



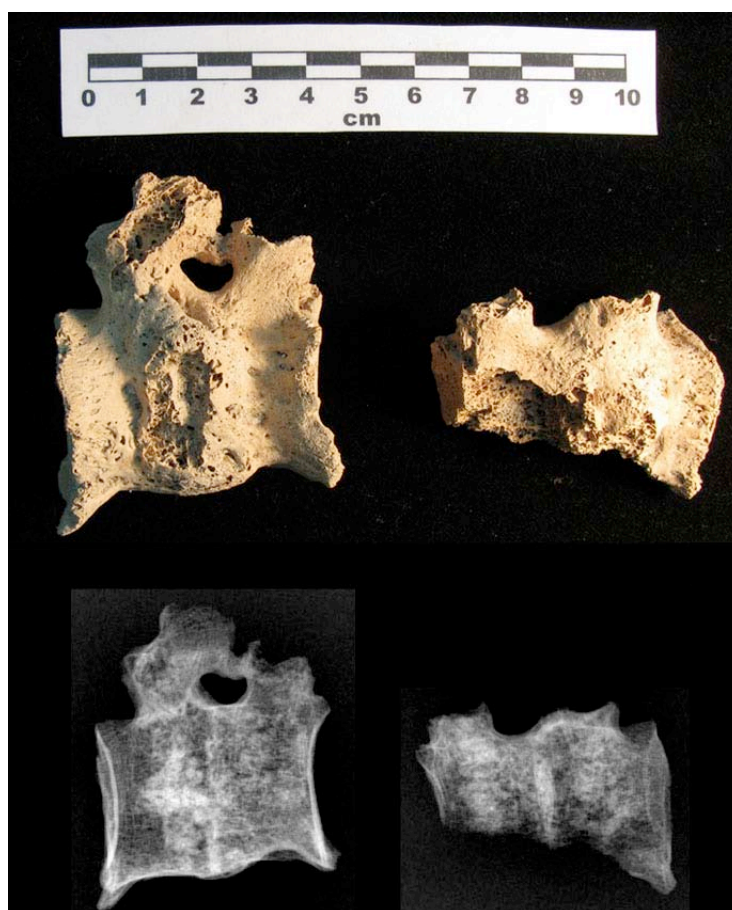#### **4.2.1.4 Infection and trauma**

Only one skeleton from the Le Morne cemetery showed traces of a bone infection: chronic osteomyelitis was identified in the lumbar spine (T12 and L1) of the individual from Structure 8. This had led to complete destruction of the disc-space and fusion of the two vertebrae. Large osteophytes had formed around the area of vertebral fusion. There was a possible cloaca in one pedicle of the first lumbar vertebrae. X-rays show slight sclerosis where the two vertebral end-plates have fused. The disc-space has been entirely destroyed.

Because the vertebrae have fractured longitudinally in the ground, it is possible to directly observe the trabecular structure of the vertebral bodies. This shows a dense trabecular pattern and demonstrates convincingly that there is no remnant of the intervertebral disc. The age of this individual, a middle to older adult, fits well with a diagnosis of vertebral osteomyelitis, which predominantly affects people over the age of 50.

Conditions that may be confused with osteomyelitis are tuberculosis, fungal infections, brucellosis and tumours. In this case, the lack of anterior bone destruction, the involvement of the pedicles and the presence of new bone formation suggests that this individual did not suffer from tuberculosis. The lack of dense sclerotic bone around the lesions makes brucellosis unlikely, whilst the specimen lacks the defined lytic lesions characteristic of metastatic cancer. Fungal infections would typically involve a 'space occupying lesion' character, which is lacking in this case. Another possible cause of conjoined vertebrae with no disk space is failure of segmentation during growth; however, in that case the vertebral end-plates fail to develop, whereas in the Structure 8 individual, residual traces of the end-plates can be observed in x-rays (fig. 27). Osteomyelitis thus seems the most plausible diagnosis.

**Fig. 27: Fused vertebrae from Structure 8.**



The right femur from the Structure 33 lower individual was bowed in an antero-posterior direction and thickened at midshaft. The bone surface appeared normal with no evidence of periostitis, sequestrum or involucrum. The shaft was broken post-mortem both proximally and distally, making it impossible to identify whether there was any shortening of the bone. The femoral head and neck were the only other portions to survive. These were of normal morphology. An x-ray showed thickening of the cortical bone and slight narrowing of the medullary cavity in comparison to the left femur. There is no indication of a fracture either of recent or longer standing. The left femur and lower leg bones appear normal.

Although the obvious explanation for femoral bowing is rickets or osteomalacia, several features suggest that this is not a likely explanation in this case. The condition is not bilateral and does not appear to have affected the tibiae. At the same time, the cortical bone is more dense and thicker on x-ray than that of other long bones. The lack of vitamin D in rickets/osteomalacia causes a loss of bone mineral and therefore the cortical bone should be relatively thin and radiolucent if this was the cause of the bowing. In fact, the right femur was noticeably heavier than the left when lifted, despite the fact that the left was more complete. Finally, the most frequent location of a bowing deformity in femora with rickets is in the proximal shaft (Brickley and Mays 2010: 400), whereas in this case the bowing was at midshaft. X-rays showed no evidence of infection.

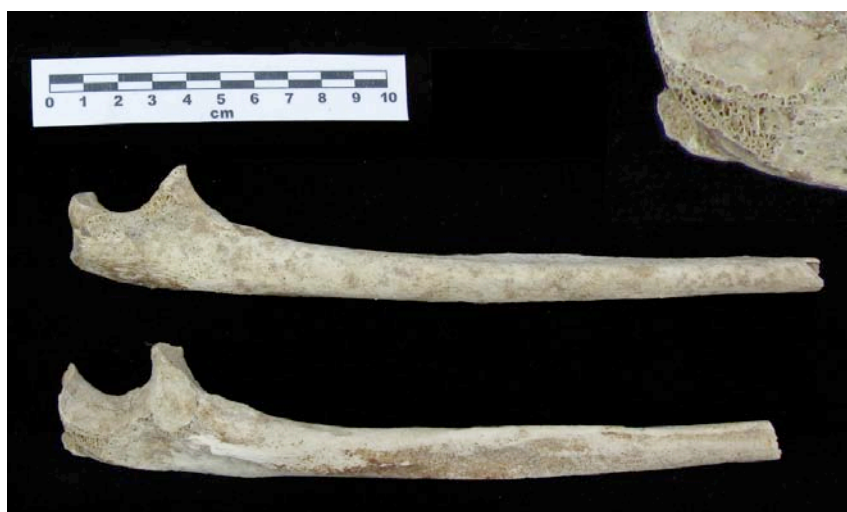Given the age of this individual, the most likely cause of the femoral bowing seems to be a greenstick fracture of the shaft suffered in childhood and since completely healed. This is, however, of necessity only a tentative diagnosis since it is one of elimination rather than of positive identification. No traces of any fracture callus remain visible on the outline of the shaft.



#### 4.2.1.5 Activity

When individuals are habitually involved in manual work, it can leave traces on the skeleton in the form of ossified muscle attachment points. The distribution of these can give some idea of which muscle groups were used most heavily. The skeletal material from Le Morne showed little indication of such activity. Only two enthesophytes were observed. One was present at the insertion of the triceps muscle at the olecranon process of the right ulna of the individual from Structure 8 (fig. 28). The second was on the radius of the lower individual from Structure 33, at the origin of the Flexor digitorum superficialis. The general lack of muscle development is interesting in light of the fact that the population may represent the remains of freed slaves. One possible reason for this lack of evidence for heavy muscle usage is that there was a gendered division of labour, with females engaged in less manual labour; however, this is not borne out by the existence of two other examples of pathological lesions. The young woman from Structure 7 had spondylolysis of the fifth lumbar vertebra (fig. 29). Spondylolysis is a form of stress fracture in which the neural arch of the vertebra separates from the body through the *pars interarticularis*. The lesion was well remodelled and healed at the time of death.

**Fig. 28: Enthesophyte on right ulna from Structure 8.**



**Fig. 29: Spondylolysis in the lumbar spine from Structure 7.**



Rather than a specific trauma, spondylolysis usually develops in response to repeated strain over long time periods (Merbs 1996). In modern contexts it is frequent in individuals who are involved in manual labour, and seems to be particularly associated with vigorous and repetitive movements involving the lower back (Roberts and Manchester 2010: 106). It is only observed in humans and is thought to relate to the adoption of an upright posture. Although involving a fracture and separation of the body and neural arch of the vertebra, spondylolysis is not usually associated with long-term pain, and Merbs (1996) has even suggested that it might be an adaptive response, giving a greater degree of flexibility.

Os acromiale was identified on the right scapula of the older possible female from Structure 33 (fig. 30). This occurs when there is a failure of fusion of the acromion process of the scapula due to stresses placed on the scapula during development. Very high frequencies of this condition were observed in the skeletal remains from the Mary Rose (Stirland 2005), and it has been suggested that this resulted from training with the medieval long-bow during adolescence. The Le Morne example was restricted to the right shoulder, with the left appearing normal.

**Fig. 30: Os acromiale from Structure 33/Lower.**



Both of these conditions have been associated both with heavy labour and with congenital defects that make the bone more liable to fracture (Larsen 1997: 190-191; Roberts and Manchester 2007: 151-152). The small numbers in the present sample means that any assessment of prevalence would be insecure, but the very fact that both of these conditions occur in such a small sample is of interest.

One skeleton from Le Morne (Structure 1A) also had squatting facets on the distal tibia. These extensions of the joint surface typically develop when the ankle joint is habitually in a flexed position as is the case in squatting. This may indicate that this person commonly adopted a squatting posture when at rest, or alternatively that she regularly carried out activities that required a squatting position.

#### **4.2.1.6 Other conditions**

A button osteoma was observed on the skull of the young woman from Structure 7. This benign lesion is observed in about 1% of autopsies (Ortner and Putschar 1981: 368). It has no clinical impact and the individual would probably have been unaware of its existence.

## 5. DISCUSSION AND INTERPRETATION OF RESULTS

### 5.1 Discussion of archaeological evidence

A number of points are worthy of further discussion from the archaeological evidence itself, relative to understanding issues of lifestyle and who may or may have been interred.

Principal amongst these issues is an attempt at defining the religious affiliation of those buried, and by analogy, those individuals who buried their dead. This ties in directly with our desire to understand the origins of those interred. In this instance, one might assume that the interred, of slaves or freed slaves, would have followed a Christian religious life. However, in the case of this cemetery, there is no evidence linking the burial traditions of the buried with Christianity. In fact, the opposite would appear to be the case. The bodies are, in the main, orientated to face (predominantly) west, which – whether by design or serendipity – also faces Le Morne Brabant, and Madagascar. This is the reverse of Christian doctrine. In addition to this, the presence of both the glass bottle (grave 33/U) and coins (grave 7) would be more in keeping with traditional African burial practices as opposed to Christian. Finally, there is no evidence of consecration of this area. Although difficult to determine, the fact that at least three very young juveniles, effectively neonatal or newborn, are buried within the cemetery – individuals that could not possibly have been baptised – indicates that the religious practice adhered to was not a Christian one.

Looking at the graves, their construction, the evidence for the types of coffin used and the mode of delineation of the grave, again, a number of points are worth further exploration.

It would appear that whether on an individual, or community level, those burying the dead were not without means. The coffins themselves, although certainly not exemplary are far from being rudimentary examples. While it must be remembered that a death and subsequent burial are social occasions that draw on community strength and resources, and that craftsmanship (for constructing coffins for example) could well be provided for a minimal cost basis, nonetheless, we should not ignore the fact the evidence points to products of reasonably good quality. Furthermore, the almost ubiquitous recovery of mother-of-pearl buttons, from infant and adult burials alike, suggests that bodies were not simply interred in a shroud, but in cloths of some finery.

At least for some of these graves there is clear indication that the specific (if not always the precise) location of the individual grave was noteworthy and part of social memory. This is indicated by the fact that the grave outlines were reconstructed, in one case on four separate occasions; invariably the reconstruction phase resulted in the use of larger, often cut, basalt blocks. The earlier levels more often than not use small, uncut basalt stones, serving as a relatively simple grave outline. These reconstructions are very important as they speak of a period, perhaps decades long, where the cemetery's purpose is sovereign, undergoing little change, and known as the final resting place of ancestral populations by those using it. This clearly points to an enduring memory within the context of landscape and land use.

While time and funding prohibited, at this stage, radiocarbon dating to determine the period of use and the temporal relationship between the interred, the coins found with grave 7 dated the grave to the first third of the 19th century. The fact that some of the graves show evidence of being buried at a time when the local substrate was considerably lower (as evidenced by reconstruction of the surface outline) would seem to indicate that the site was in use for some considerable period of time.

### 5.2 Discussion of Isotopic Analysis

The human bone collagen isotope results suggest that the protein component of the analysed individuals' diets during the last years of life were based upon a mixture of C<sub>3</sub> (i.e. wheat) and



C<sub>4</sub> (i.e. maize) resources. The two outlying individuals (grave 25, a 3 to 4 year old child; and grave 33/U, a 25 to 30 years old probable female) consumed a diet with a higher proportion of C<sub>4</sub>-derived protein than the other nine analysed individuals. With the exception of these outliers, the individuals within the population consumed similar diets in terms of the amount, trophic level (i.e. plant, herbivorous animal or omnivorous animal) and the C<sub>3</sub>/C<sub>4</sub> status of their protein intake. As the deer isotope results indicate that it consumed a diet containing both C<sub>3</sub> and C<sub>4</sub> plants, it is not possible to determine whether the human collagen isotopes reflect the consumption of C<sub>4</sub> plants or the consumption of animals that consumed C<sub>4</sub> plants. However, the large difference in  $\delta^{15}\text{N}$  values between the deer and the mean human value indicates that this deer is not representative of the protein consumed by the analysed humans. A larger faunal sample is necessary for a more accurate baseline for comparison, particularly as the deer deposition may not be contemporary with the human burials.

The tooth enamel carbonate carbon isotope results show a wide range of variation, indicating that during childhood these individuals ate significantly different diets. Tooth enamel carbonate primarily reflects the carbohydrate component of the diet, indicating that, regardless of the C<sub>3</sub> or C<sub>4</sub> status of any animal protein consumed, during childhood some of the individuals did consume C<sub>4</sub> plants. The amount of C<sub>4</sub> plants consumed during childhood varies from little or none (grave 8, grave 30 and grave 33/U) to a large proportion of the carbohydrate portion of the diet (grave 33/L).

Two edible C<sub>4</sub> plants are known, historically, to have been available to the people of Mauritius – sugar cane and maize (Allen 1999); although this evidence needs to be used with caution as sugar, for example, was not grown in the Le Morne region in the 1830s. There is no historical evidence for the importation of the other African C<sub>4</sub> staple plants, sorghum, finger millet and pearl millet, to Mauritius. Given the low protein content of sugar cane, and that it was produced for export, it is likely that the C<sub>4</sub> signal seen in the bone collagen isotope values reflects either the consumption of maize or the indirect consumption of C<sub>4</sub> resources via animal protein. The tooth enamel carbon isotope results show a human diet that included varying amounts of maize and/or sugar cane at least during childhood. Given the abundant coastal / sea resources, as well as produce such as sweet potato, it is likely that these formed part of the diet also.

The difference in range of variation of bone collagen results (excluding the two outliers) and tooth enamel carbon isotope results is striking. While the carbohydrate component of childhood diet varied substantially, during adulthood (Hedges et al. 2007) the protein components of their diets were similar. It is possible that this pattern reflects the diets of a group of people who during childhood lived in multiple locations but later in life came to live, and eat, together. Further evidence is needed to support this hypothesis, particularly more information regarding the temporal spread of the burials.

The bone collagen results show that two outliers, grave 25 and grave 33/U, were consuming a diet that during life would have been noticeably different from that of the other analysed individuals. There are several potential explanations for this. Firstly, these individuals may have lived with the other buried individuals but eaten a distinct diet, perhaps in order to maintain a separate social status or identity. Secondly, the outlying individuals may have been newcomers to the community, such that their isotope results reflect a mixed signal of two distinct diets. Thirdly, the outlying burials may not be contemporary with the other analysed burials and reflect a temporal change in subsistence practice. Radiocarbon dating results would clarify this issue.

The oxygen isotope results show a range of variation consistent with a population that drank water from the same source during childhood. However, it is possible that some or all of these individuals migrated to Mauritius from a place where the drinking water was not isotopically distinguishable from that of Mauritius, i.e. Madagascar, which has a similar isotopic

composition to that of Mauritius ( $\delta^{18}\text{O}_{\text{ppt}}$  estimations obtained from [www.waterisotopes.org](http://www.waterisotopes.org), March 2011). These individuals may well have derived from Madagascar as the isotopic signal for Mauritius falls within the range that one finds from Madagascar. However, precisely because of this, there is no isotopic reason to assume that any of these individuals were long-distance migrants.

### 5.3 Discussion of Osteological Finds

The excavation and analysis of the human remains has prompted three key questions that will be discussed in more detail here. Firstly, and perhaps most significantly in light of the World Heritage status of Le Morne Brabant is the question of whether the skeletons are of slaves or ex-slaves, or whether they represent other portions of the Mauritian population. Secondly, there is the question of the neonatal twins from Structure 6: is infanticide an option or were they natural deaths. Thirdly, what is the significance of the double burial in Structure 1? Is it simply a double burial or does it represent either death in childbirth or a ‘coffin birth’ where the baby is delivered after death due to the decomposition process?

#### 1. Could the skeletons represent the remains of slaves or ex-slaves?

Dating evidence from coins and other material culture suggests that the cemetery at Le Morne was in use up to the mid 1830s, the period when slavery came to an end in the country. The area has since become famous for its association with Maroons – groups of escaped slaves who took advantage of Le Morne Mountain’s inaccessibility. The question of whether the skeletons are of slaves is therefore of extreme cultural significance. To address this, it is necessary to examine evidence of lifestyle and to ask whether this evidence is compatible with a slave origin.

Osteological studies of slavery have so far been largely confined to slaves of considerably earlier periods such as the Roman Empire and to the Caribbean and North America. Of these, it is likely that the plantation-based slavery of the Caribbean and North America will have more relevance to the present case than examples from the ancient world. Studies of New World slavery have identified a number of characteristics that are commonly associated with slave populations, but it must be acknowledged that there is considerable variability, meaning that a ‘shopping list’ approach to the osteology of slavery is to be avoided. Given this caveat, some features that might be relevant in the present case are evidence of nutritional deficiency, the development of skeletal features related to heavy manual labour and evidence of high levels of non-specific infections and skeletal trauma. The last three of these are, of course, dependent on the form which slavery takes. Household slaves would have been involved in different kinds of activities to agricultural slaves and this would have been reflected in the kinds of risks to which they were exposed and hence the kinds of conditions that are visible in the skeleton. A further characteristic of slavery in Mauritius was the over-representation of males. Kuczynsky (1949, cited in Benedict 1976) has calculated that male slaves outnumbered women by two to one until 1826, when the proportion of females began to increase (Benedict 1976: 140). The 1826 registration data records five female slaves and 27 males belonging to the Le Morne Brabant estate (Teelock *et al* 2009.). Interestingly, these were all adults. The demographic characteristics of the Le Morne sample may therefore also cast some light on this question.

Nutritional deficiency is commonly associated with slave populations because slaves eat a relatively monotonous diet of low-value foods. Whilst it is necessary for slaves to have sufficient food to be able to work, owners are frequently reluctant to invest more than necessary in the provision of a varied diet. This is reflected in both evidence of specific dietary deficiencies and in evidence of childhood stress such as enamel hypoplasias.

Rates of enamel hypoplasia vary considerably between published skeletal slave samples from the US and Caribbean. At a slave cemetery in South Carolina 92% of males and 70% of females had enamel hypoplasias (Rathbun 1987) and in the Newton cemetery in Barbados the figure was 98% (Handler and Corruccini 1983), testifying to very severe stresses placed on the slaves through factors such as calorie or nutrient deficiency or disease. These figures are clearly very high compared with the Le Morne figure of 40% of adults. In contrast, levels were much lower in a series of pooled skeletal samples from Virginia and the Carolinas, at 56% in the eighteenth century and only 29% in the nineteenth century component (Kelley and Angel 1987).

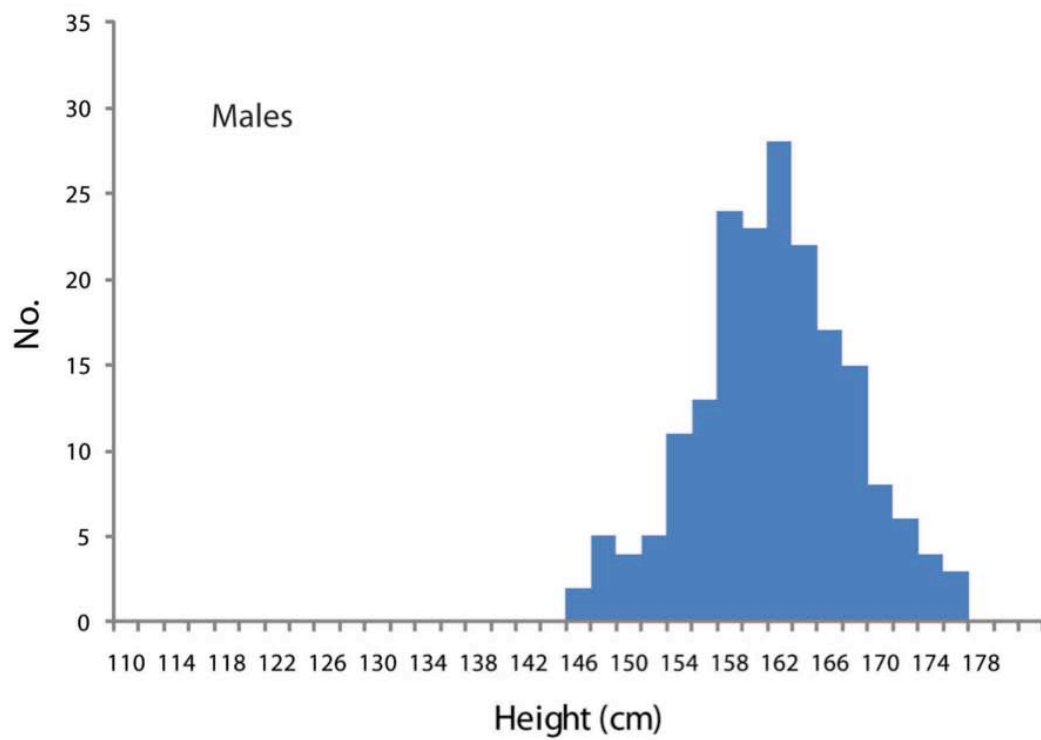
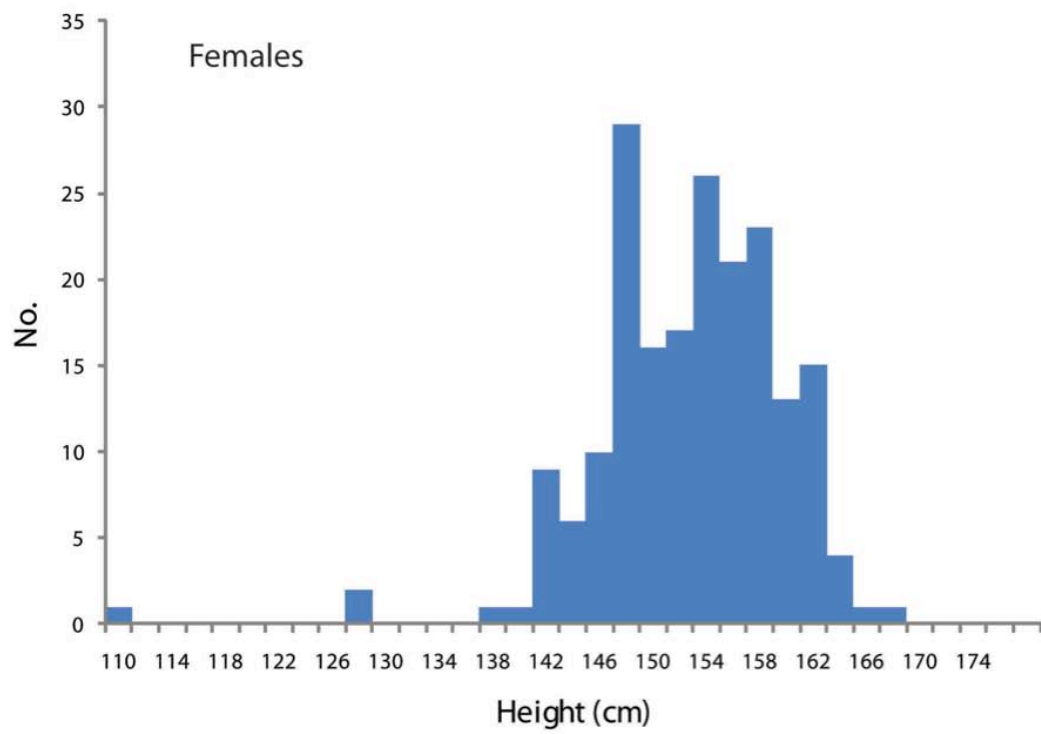
The two most commonly observed specific nutritional deficiencies in human skeletal remains are rickets and scurvy. Both are absent from the Le Morne skeletons. Although one femur (from Structure 8) was bowed, the lack of bilateral involvement and the form of the bowing are not consistent with rickets and must represent some other process. The former is not altogether surprising. Although rickets is typically associated with low-status populations, it is generally found amongst industrial populations where people did not have adequate exposure to sunlight. Given that Mauritian slaves are likely to have spent considerable periods of time working outdoors, evidence for rickets would have been surprising. The similar lack of scurvy suggests that the diet must have included sufficient vitamin C. There is some suggestion that slave diet in Mauritius was based around maize consumption (Grant 1801, cited in Benedict 1976: 139) and this is supported by the results of isotopic study of the Le Morne skeletons. Maize contains a relatively high proportion of vitamin C when harvested as a mature plant (around 1/3 the amount in orange juice, measured gram for gram (Esselen *et al* 1937: 507)) and this may explain the lack of evidence for scurvy in this population.

A further indication of poor health and nutrition is stature and it is noticeable that the reconstructed statures of the Le Morne individuals were low. Female heights were around 155-160 cm, whilst the reconstructed height of the possible male was 163cm. Although these figures would be seen as markedly low were they to appear in a modern population of European ancestry, they cannot necessarily be seen as abnormally low for those populations that have contributed to the Mauritian population. Modern figures from Malawi, which contributed to the slave population of Mauritius, give mean heights of 155 for females and 166 for males (Msamati and Igbibi 2000). These populations are themselves subject to problems of inadequate diet and poor healthcare and we must therefore acknowledge that such conditions are not limited to slave populations.

It has been possible to compare the reconstructed heights of the Le Morne skeletons to heights of slaves in the southern portion of the island recorded in the registration of 1826 (fig. 31; data kindly provided by Vijaya Teelock of the Truth and Justice Commission (Teelock *et al* 2009)). From this it can be seen that the Le Morne skeletons fall right into the middle of the height distribution of the slave population.



**Fig. 31: Height distribution of slaves from the area around Le Morne in 1826 (data from Teelock *et al* 2009.).**



In summary, the Le Morne skeletal population appears to have been reasonably well nourished and to fit with the expected statures of the populations that have contributed to the Mauritian population, but shows evidence of over-use of certain parts of the skeleton. Whilst the lack of evidence of stress and nutritional inadequacy differentiates the Le Morne skeletons from slave samples from the New World, this does not mean that the Le Morne cemetery does not contain slaves. Rather it seems to suggest that the conditions of slavery in the south of Mauritius would have been different to those on the large plantations of the New World. Plantation slavery was certainly common on Mauritius, but the area of Le Morne Brabant is not suitable for such cultivation methods due to its aridity. Instead, subsistence farming with some livestock appears to have been the main activity in this area, and the diet was probably supplemented by hunting and fishing (Teelock, pers. comm.). Such an interpretation is supported by the slave registration of 1826 (Teelock *et al* 2009.), in which occupations include fisherman, hunter and guardian of cattle as well as the more familiar categories of labourers and servants (although these latter categories dominate the sample).

## 2. What is the significance of the twin burial?

The two babies buried in Structure 6 are of great interest. The arrangement of the bodies so close to one another and the lack of evidence of disturbance of the remains strongly implies that the two burials were contemporaneous. Calculating age from the length of preserved long bones gives figures of 36-40 weeks and 37-41 weeks gestation respectively, indicating that these infants died at around the point of birth. As they are almost exactly the same size and were buried at the same time in the same grave, it seems likely that these two babies were in fact twins.

In many African societies, including Madagascar, twins were frequently subject to infanticide and therefore this must be regarded as a possibility for these two individuals. Unfortunately, this is very difficult to prove from dry bones. Neonatal bones are relatively undeveloped so that methods that can be used to identify cause-of-death in adults may not be applicable. For example, strangulation may be identified in adults by fracture of the hyoid bone, but in neonates the hyoid has barely commenced ossification (Lewis 2007: 95). Even in modern forensic cases, it is usually possible to prove only the lesser offence of 'concealment of birth' when neonatal remains are skeletonised (*ibid.*).

Death around the point of birth can, of course, take place for a variety of reasons. Babies may be still-born or get into difficulties during the birth process. This is especially true where no doctors are present to assist the mother, as is likely to have been the case at Le Morne. It is likely that the surroundings in which women gave birth in the rural and relatively remote area of Le Morne were not particularly clean and so babies may also have died from infections within days of birth. Infanticide is thus only one possible explanation.

In the case of the 'twins' from Le Morne, the bones themselves show no traces of violent treatment. All fractures are consistent with in-ground, dry-bone breakage. As death seems to have occurred around the point of birth, there is also no evidence for healing injuries, as might be expected if they had been ill treated but survived for several weeks after birth. The question of infanticide must therefore remain unanswered, suggested only by the co-incidence of two identically aged neonates buried alongside one another.

## 3. How can the double burial in Structure 1 be understood?

Structure 1 contains the bodies of a young woman and a late term foetus/neonate. Whilst the woman is placed in the normal supine position with her head to the east, the foetus is placed between her legs, with the head facing up and away from the woman (fig. 7).

It is the only body in the cemetery not to have its head to the east. Although the baby was found outside the body, calculations of its age from long bone lengths suggest that it was approximately one month premature, giving rise to a number of possibilities. The possible explanations for this unusual burial positioning are as follows:

- i. The two individuals were unrelated but died at the same time and were buried together
- ii. Both mother and baby died during childbirth and were buried together
- iii. The mother died in the latter stages of pregnancy and the foetus was found between the legs due to a 'coffin birth'

Sadly, due to the preservational characteristics of foetal bone, it has not been possible to establish whether the mother and foetus were directly related to one another through the use of DNA evidence. Distinction between the first two possible scenarios is therefore only circumstantial.

Double burials occur in three of the eight excavated structures at Le Morne. Structure 33 contained the remains of two adult females, whilst Structure 6 contained two neonatal babies. Structure 1 is the only grave to contain an adult and a child buried together, but given the small sample size, this does not prove that this was a unique treatment in the cemetery. The young female buried in Structure 1, at between 17 and 19 years old, is certainly in an age group that we might expect to be having children and it is therefore plausible that she was the mother of the baby.

The small size of the foetal remains found in the coffin and their positioning between the legs of the young woman means that it is necessary to examine the possibility that the mother died before giving birth and that the baby was only found outside the body due to the processes of decomposition. So-called 'coffin births' have occasionally been reported in the forensic literature since the early 20<sup>th</sup> century and written references to such occurrences go back at least as far as the 18<sup>th</sup> century (Jungmichel and Musick 1940). They occur when the gases produced during decomposition force the body of the baby through the birth canal, simulating a process of birth that occurs after death. Documented cases of coffin birth from the German language literature show that the position of the baby is very variable in such cases. Some report only a partial 'birth' in which the head of the baby appears between the legs (Schultz *et al* 2005), whereas in others the baby appears to have been fully delivered (Panning 1941). Whilst the foetus from Structure 1 has the head quite far down the legs of the potential mother (between the proximal tibiae), it is not so different to a case from 1940s Poland where the head of the baby was at the level of the mother's knees (Panning 1941: 259). It is also possible that the foetus may have moved within the coffin if the coffin was partially waterlogged or contained decomposition fluids. Evidence of a waterline on the skull of the woman suggests that this may have been the case, but it is impossible to ascertain how soon after burial such waterlogging may have begun. The woman's body shows evidence of having decayed within a void – the femurs have fallen outwards and the pelvis has flattened – but there is no evidence that her bones have been moved by water, so waterlogging may have occurred after the coffin had decayed and the space been infilled with sand. This would prevent movement of the bones.

One reason for suggesting coffin birth as a possibility is the small size of the foetus/neonate, which suggests that it was pre-term at death and may not have been delivered; however, it is also worth considering what the implications of size are in this population. The adult skeletons excavated from Le Morne are all small, and this fits with the height distribution of slaves from the 1826 registration (Teelock *et al* 2009; fig. 31). In a population with small adult height, low birth-weight babies may also have been common and this means that ages calculated from equations developed for babies from European contexts may be too low. If



this is the case, the double burial in Structure 1 may merely represent the remains of a mother who died in childbirth and her baby.

Analysis of the bones themselves and their distribution within the grave cannot provide conclusive proof one way or another about the burials in Structure 1, but it is interesting to note that if it was a genuine double burial then it shows some interesting foetus. If the baby was placed between the legs of the mother then it would in some way appear to mimic the process of birth.

## 6. CONCLUSION AND FUTURE WORK

This excavation and subsequent analyses have proven to be highly informative in terms of unravelling some of the details of the Le Morne Cemetery during its period of use. From the archaeology itself, particularly in terms of grave 'construction' the most interesting facet is the re-laying of grave outlines – which clearly took place on a number of occasions over a period of many years, perhaps even decades. This is truly remarkable and speaks of the nature of the site, its prominence within the minds and cognition of those who used the site, and their reverence for both their dead and their burial site. From the extensive and detailed osteological evidence it is apparent that hard work and heavy toil were the norm; however, we must use this evidence cautiously given the nature of 'work' at the time in question. From both the isotopic and osteological evidence it is also apparent that the dietary needs of the buried individuals were met, with no clear indications of dietary deficiency.

In addition, and again turning to the recovered finds, it would appear that the dead were buried in relatively well constructed coffins, clothed, and with clearly delineated grave outlined constructed in their memory. These lines of evidence would seem to indicate that the interred were freed 'peoples', but whether initially slaves or not is hard to decipher. Thanks to the isotopic analysis we can be clear that they were all from the *same* region geographically; however, at this stage it is unclear whether the interred arrived, within their lifetime, from further afield or were born and raised in Mauritius.

What is clear, and what we cannot ignore, is the seemingly unequivocal importance of Le Morne Brabant itself. While we are still left with pressing questions of *who* and *when*, we can learn a great deal about the *why*. It would appear that, as in the modern day, the site and sheer impressive magnitude of Le Morne Brabant has been a focal point for specific practices and indeed, the creation of a remarkable burial site.

In the absence of aDNA results, it is unfortunately the case that a definite answer to the question of racial affinity and origins is not possible at this time. This points leads to potential avenues for further study. At present, where osteological and scientific analysis are concerned we are most hampered by a lack of samples. In the absence of DNA for example, excavations on another portion of the site may uncover remains that have not been subjected to waterlogging, and thus more likely to yield DNA. Also, with a larger sample it may be possible to assign racial affinity based on metrical and morphological criteria. This kind of evidence is at its most persuasive when large numbers of individuals are present and results can be subject to rigorous statistical analysis. The current sample size of five adults and six children can only hint at the community life of these people and it is greatly to be hoped that this sample can be increased in the future.

This report has been kept relatively brief, presenting limited archaeological details. This has been done with the express desire to emphasis the *results*. This is a remarkable site, primarily for the local and wider Mauritian population. The site and the recovered remains are the first such finds for the Republic of Mauritius and would seemingly provide some of the most tangible links to a collective ancestral population. The purpose of archaeology is to connect

modern with ancient: the site of the Le Morne Cemetery allows us, for the first time ever, to *visualise* the use, reuse, and reverence that this cemetery held for an enigmatic ancestral Mauritian community. While so much of Mauritius' past is intertwined within paradigms of slavery and indenture, hardship and toil, at least this aspect appears free of that; we should do all we can to learn more about this facet of past lives.

#### BIBLIOGRAPHY

- Allen RB. 1999. *Slaves, Freedmen, and Indentured Labourers in Colonial Mauritius*. Cambridge: Cambridge University Press.
- Ambrose SH. 1990. Preparation and Characterization of Bone and Tooth Collagen for Isotopic Analysis. *Journal of Archaeological Science* 17(4):431-451.
- Benedict, B. 1976. Slavery and Indenture in Mauritius and the Seychelles. In Watson, J.L. (ed) *Asian and African Systems of Slavery*, pp.134-168. Berkeley and Los Angeles: University of California Press.
- Brickley, M. And Mays, S. 2010. Evaluation and Interpretation of Residual Rickets Deformities in Adults. *International Journal of Osteoarchaeology* 20(1): 54-66.
- Brooks, S. And Suchey, J.M. 1990. Skeletal Age Determination Based on the Os Pubis: a comparison of the Acsadi-Nemeskeri and Suchey-Brooks methods. *Human Evolution* 5(3): 227-238.
- Buckberry, J.L. and Chamberlain, A.T. 2002. Age Estimation from the Auricular Surface of the Ilium: A Revised Method. *American Journal of Physical Anthropology* 119: 231-239.
- Buikstra, J.E. and Ubelaker, D.H. 1994. *Standards for Data Collection from Human Skeletal Remains*. Arkansas Archeological Survey Research Series 44. Fayetteville: Arkansas Archaeological Survey.
- De Niro MJ. 1985. Postmortem Preservation and Alteration of in Vivo Bone Collagen Isotope Ratios in Relation to Paleodietary Reconstruction. *Nature* 317(6040):806-809.
- Esselen, W.B., Fellers, C.R. and Isgue, 1937. Vitamins A, C and D in maize as affected by variety and stage of growth. *Journal of Nutrition* 14(5): 503-511.
- Fazekas, I.G. and Kósa, F. 1978. *Forensic Fetal Osteology*. Budapest: Akadémiai Kiadó.
- Handler, J.S. and Corruccini, R.S. 1983. Plantation Slave Life in Barbados: A Physical Anthropological Analysis. *Journal of Interdisciplinary History* 14(1): 65-90.
- Hedges REM, Clement JG, Thomas DL, and O'Connell TC. 2007. Collagen Turnover in the Adult Femoral Mid-shaft: Modelled from Anthropogenic Radiocarbon Tracer Measurements. *American Journal of Physical Anthropology* 133:808-816.
- Jungmichel, G. and Musick, N. 1941. Über Sarggeburts. *Deutsche Gesellschaft für Gerichtliche Medizin* 34: 236-256.
- Kelley, J.O. and Angel, J.L. 1987. Life Stresses of Slavery. *American Journal of Physical Anthropology* 74: 99-211.
- Lewis, M. 2007. *The Bioarchaeology of Children. Current Perspectives in Biological and Forensic Anthropology*. Cambridge: Cambridge University Press.

Lovell, N.C. 1997. Trauma Analysis in Paleopathology. *Yearbook of Physical Anthropology* 40: 139-170.

Martin, R. 1957. *Lehrbuch der Anthropologie in Systematischer Darstellung*. Revised third edition. Stuttgart: Gustav Fisher.

Merbs, C.F. 1996. Spondylolysis and Spondylolisthesis: A Cost of Being an Erect Biped or a Clever Adaptation? *Yearbook of Physical Anthropology* 39: 201-228.

Msamati, B.C. and Igbigbi, P.S. 2000. Anthropometric profile of urban adult black Malawians. *East African Medical Journal* 77(7): 364-8.

O'Connell, L.O. 2004. Guidance on recording skeletal age at death in adults. In Brickley, M. And McKinley, J.I. (eds.), *Guidelines to the Standards for Recording Human Remains*, 18-20. IFA Paper 7. Southampton/Reading: BABAO/Institute of Field Archaeologists.

Ortner, D.I. and Putschar, W.G.J. 1981. *Identification of Pathological Conditions in Human Skeletal Remains*. Washington: Smithsonian Institution Press.

Panning, G. 1941. Sarggebur. *Deutsche Gesellschaft für Gerichtliche Medizin* 34: 257-264.

Privat KL, O'Connell TC, and Richards MP. 2002. Stable isotope analysis of human and faunal remains from the Anglo-Saxon cemetery at Berinsfield, Oxfordshire: Dietary and social implications. *Journal of Archaeological Science* 29(7):779-790.

Rathbun, T.A. 1987. Health and Disease at a South Carolina Plantation: 1840-1870. *American Journal of Physical Anthropology* 239-253.

Reid, D.J. and Dean, M.C. 2000. Brief Communication: The Timing of Linear Hypoplasias on Anterior Human Teeth. *American Journal of Physical Anthropology* 113: 135-139.

Roberts, C. And Manchester, K. 2010. *The Archaeology of Disease*. Third Edition. Stroud: The History Press.

Rogers, J., Waldron, T., Dieppe, P. and Watt, I. 1987. Arthropathies in Palaeopathology: The Basis of Classification According to Most Probable Cause. *Journal of Archaeological Science* 14: 179-193.

Rogers, J. And Waldron, T. 1989. Infections in Palaeopathology: The Basis of Classification According to Most Probable Cause. *Journal of Archaeological Science* 16: 611-625.

Scheuer, J.L., Musgrave, J.H. and Evans, S.P. 1980. The estimation of late fetal and perinatal age from limb bone length by linear and logarithmic regression. *Annals of Human Biology* 7: 257-265.

Schultz, F., Püschel, K. and Tsokos, M. 2005. Postmortem Fetal Extrusion in a Case of Maternal Heroin Intoxication. *Forensic Science, Medicine and Pathology* 1: 273-276.

Scott, E.C. 1979. Dental Wear Scoring Technique. *American Journal of Physical Anthropology* 51: 213-218.

Smith, B.H. 1984. Patterns of Molar Wear in Hunter-Gatherers and Agriculturalists. *American Journal of Physical Anthropology* 53: 39-56.



Stirland, A. 2005. *The men of the Mary Rose: Raising the Dead*. Stroud: Sutton.

Teelock, V. and University students. 2009. Dataset of Slave registration returns for 1826 compiled for the Origins Project by PI Vijaya Teelock and University students.

Trotter, M. And Gleser, G.C. 1977. Estimation of stature from long bones of American Whites and Negroes. *American Journal of Physical Anthropology* 10: 463-514.

Waldron, T. 1995. *A Field Guide to Joint Disease in Archaeology*. Chichester: John Wiley and Sons.

Wood, J.W., Milner, G.R., Harpending, H.C. and Weiss, K.M. 1992. The Osteological Paradox: Problems of Inferring Prehistoric Health from Skeletal Samples. *Current Anthropology* 33(4): 343-70.

Ubelaker, D.H. 1989. *Human Skeletal Remains*. Second Edition. Washington: Taraxacum Press.

APPENDIX I: CATALOGUE OF ANALYSED SKELETAL REMAINS

Structure 1A

*Age:* Young adult (17-19)

Iliac crests fusing; vertebral bodies fusing; medial clavicle unfused bilaterally; spaces between bodies 1 and 2, 3 and 4 and 4 and 5 of the sacrum.

*Sex:* Female

Skull sex: female

Pelvis sex: female

*Completeness:* Complete. Skull 100% complete. Long bones 90% complete.

*Preservation:* Generally good surface preservation of skull. Some dark discolouration of left temporal and parietal region probably related to burial position. Slight post-mortem damage to some long-bone extremities. Delamination of proximal and distal left ulna and proximal left femur. Distal right ulna and hand show pitted surface modification possibly reflecting disturbance by crabs. Some long-bone shafts exhibit black spotting. This is probably fungus growth post processing of bone.

*Dentition:*

Right														Left	
PE	P	P	P	P	P	P	P	P	P	P	P	P	P	P	NE
18	17	16	15	14	13	12	11	21	22	23	24	25	26	27	28
48	47	46	45	44	43	42	41	31	32	33	34	35	36	37	38
P	P	P	P	P	P	P	P	P	P	P	P	P	P	P	P

*Stature:* 155 cm (femur)

*Non-metric traits:*

Cranial: See table 3

Post-cranial: True septal perforation on right humerus (trait absent left). Squatting facet on latero-anterior aspect of distal left tibia (trait absent right).

*Skeletal Pathologies:* None observed

*Dental Pathologies:* Mild calculus on buccal aspect of both upper first premolars, upper first molar and lower right first incisor; lingual aspect of both lower second premolars, first molars and second molars and on both buccal and lingual aspects of lower right first and second incisors and canine. No caries or abscesses. Linear enamel hypoplasia on upper right canine at 2.8 and 4.4mm from CEJ, on upper first incisors at 3.01 and 3.57mm and on upper right second incisor at 4.8mm from CEJ. These correspond to ages of formation of 2.7-2.9, 2.9-3.3, 3.4-3.9, 2.9-3.4 and 3.7-4.1.

*Notes:* None

Structure 1C

*Age:* Foetus, 33-37 weeks gestation

Linear regression of humeral length (right) = 35.2 ±2.33 gestational weeks

Linear regression of radius length (left) = 33.6 ±2.29 gestational weeks

Linear regression of femur length (left) = 34.7 ±2.08 gestational weeks

*Sex:* Unobservable

*Completeness:* 75+ % complete but cranium is very fragmentary.

*Preservation:* The skeleton is generally well preserved, but there is some erosion of the ends of the long bones. The cranium is highly fragmented.

*Dentition:* None recovered

*Stature:* N/A

*Pathologies:* None observed

*Notes:* None

Structure 6/7

Age: Neonate (36-40 weeks gestation)

Linear regression from reconstructed tibia length (left) = 38 ±2.12 gestational weeks

Sex: Unobservable

Completeness: 75+ % complete, but cranium is highly fragmented

Preservation: Generally good surface preservation. Long bones are slightly fragmentary; the cranium is highly fragmented.

Dentition: Single incisor tooth bud and unidentified fragment of tooth bud.

Stature: N/A

Pathologies: None observed

Notes: None

Structure 6/8

Age: Neonate (37-41 weeks gestation)

Linear regression of humerus length (right) = 39.1 ±2.33 gestational weeks

Linear regression of ulna length (right) = 38.5 ±2.20 gestational weeks

Linear regression of femur length (right) = 38.2 ±2.08 gestational weeks

Linear regression of tibia length (right) = 39.0 ± 2.12 gestational weeks

Sex: Unobservable

Completeness: 75+ % complete

Preservation: Generally well preserved, although slight erosion of some long bone diaphyseal ends. Skull and ribs highly fragmented.

Dentition: Single tooth bud present. Right maxillary deciduous first incisor with cusp outline complete.

Stature: N/A

Pathologies: None observed

Notes: None

Structure 7

Age: Young adult (25-30)

Medial clavicle completely fused; Space between first and second sacral segments only; jugular process fusing; Auricular surface stage three; third molars erupted and in wear.

Sex: Female

Skull sex: female

Pelvis sex: female

Completeness: Complete

Preservation: Considerable surface abrasion of entire skeleton involving loss of bone surface and resulting 'chalky' appearance. Long bones and ribs essentially complete but fragmentary.

Dentition:

Right																Left
X	P	P	P	P	P	P	P	P	P	P	P	P	P	P	P	A
18	17	16	15	14	13	12	11	21	22	23	24	25	26	27	28	
48	47	46	45	44	43	42	41	31	32	33	34	35	36	37	38	
P	X	P	P	P	/	P	/	P	P	P	P	P	P	P	P	P

From the position of the tooth sockets, it appears that the lower right anterior teeth were originally misaligned, with the canine situated anterior to and between the first and second incisors and rotated through 90°. All of these teeth are missing post-mortem.

Stature: 156 cm

Non-metric traits:

Cranial: See table 3

Post-cranial: None observed

Pathologies:

Dental: Mild calculus formation on maxillary left first second incisor and first molar, and on mandibular left incisors, canine, first premolar and first molar. Two maxillary and five



mandibular teeth have carious lesions. Occlusal surface caries are present on the upper left second molar, lower left third molar, lower right second premolar and lower right first molar. Large caries that have destroyed the majority of the crown are present on the upper left second molar, lower left second molar and lower right second molar. A linear enamel hypoplasia is visible on the maxillary right first incisor at 6.1mm above the CEJ and on the mandibular right second incisor at 3.02mm above the CEJ, corresponding to ages at formation of 2.4-2.8 for the latter.

Cranial: A small bony nodule on the sagittal suture, close to Lambda, may be a button osteoma; however, it is not very clearly defined; there is no evidence of abnormal bone reaction or resorption.

Postcranial: Spondylolysis of the fifth lumbar vertebra involving complete separation of the neural arch and lamina from the body and pedicles. The inferior articular facets are normal, whilst the fracture interrupts the inferior margin of the superior articular facets; this is associated with only minimal osteophyte formation. Smooth lamellar bone indicates that the lesion is healed and of long standing.

Notes: Green discolouration is present on the first three cervical bodies, indicating that a copper alloy object or objects had been lying against the neck in the grave.

### Structure 8

Age: Middle to older adult (40+)

Auricular surface stage V

Sex: Possible male

Skull sex: indeterminate

Pelvis sex: male

Completeness: Almost complete (>75%)

Preservation: Extensive destruction of surface of long bones and posterior cranium exposing white subsurface cortical bone, with the lower limbs the most severely affected.

#### *Dentition:*

Right											Left					
-	-	P	X	X	X	X	X	X	X	X	X	X	P	L	-	
18	17	16	15	14	13	12	11	21	22	23	24	25	26	27	28	
48	47	46	45	44	43	42	41	31	32	33	34	35	36	37	38	
X	X	X	X	P	P	P	P	X	P	P	P	X	X	X	X	

Stature: 160cm (femur)

Non-metric traits:

Cranial: See table 3

Post-cranial: Possible lumbarisation of first sacral vertebra, although extreme fragmentation of specimen means that this interpretation is not absolutely secure.

#### *Pathologies:*

Dental pathologies: Abscess cavity at level of upper right first molar. The lesion is located within the alveolar process and perforates the healing edge of the alveolar bone at the location of the resorbing first molar root cavity. The lesion appears to have been active at death. Mild calculus is present on all remaining teeth. Alveolar resorption around the anterior mandibular dentition, associated with a porous and irregular alveolar margin, indicates that this individual suffered from periodontal disease. Periodontal disease had caused exposure of the tooth roots by 4 to 6.6 mm. This was clearly of long standing as calculus had developed on the root surfaces. No caries were observed on the remaining teeth, but this may be a function of the large proportion of teeth that had been lost ante mortem.

Post-cranial pathologies:

Osteoarthritis: Osteophytes were observed in the following locations: both scapulae (glenoid process); right humeral head (left unobservable); right humerus medial condyle (left unaffected); both proximal ulnae; both acetabulae; both femoral heads; left distal femur (right unobservable); left patella (right unobservable); right and unsided pedal phalanges (together with pitting and sclerosis).

Vertebral pathology: marginal osteophytes on lower cervical, lower thoracic and lumbar vertebrae; osteophytosis of L4, L5 and lumbarised sacral vertebra superior articular facets. Intervertebral disc disease of C3-6 and L3-S1.

Notes: None

Structure 25

Age: 3-5 (tooth development)

Dental age: 3-5

Fusion age:

Metric age: Unobservable

Sex: Unobservable

Completeness: Moderately complete (50-75%)

Preservation: Moderately well preserved. Significant fragmentation of most skeletal areas. Surface preservation is variable, being good in preserved lower limbs (although the talus and calcaneus are very abraded) but with marked surface erosion in the upper limbs, especially the right arm. Most long-bone articular ends are abraded.

Dentition:

Right					Left				
P	P	P	P	/	P	P	P	P	P
55	54	53	52	51	61	62	63	64	65
85	84	83	82	81	71	72	73	74	75
P	P	P	P	/	P	P	P	P	P

Stature: N/A

Pathologies:

Cranial: None observed

Dental: Interproximal non-carious pit between upper first incisors.

Post-cranial: None observed

Notes: None

Structure 29

Age: 2-3 years

Dental age: 2-4 years

Fusion age: 1-2 years. Neural arches of cervical vertebrae unfused (under three); neural arches of thoracic and lumbar vertebrae fused to each other but not to bodies (one to three years).

Metric age: 2 years. Femur length 170mm

Sex: Unobservable

Completeness: Complete (missing only some smaller bones, especially of extremities)

Preservation: Moderately well preserved. Cranium is fragmentary but well preserved with little surface damage. Long bones generally well preserved anteriorly and eroded on posterior surfaces. Extensive surface destruction of posterior surfaces leaving white, pitted surface. Lower limb diaphyseal ends of long bones and ischial tuberosities eroded. The vertebral column is well preserved.

Dentition:

Right					Left				
P	P	/	P	P	P	P	/	P	P
55	54	53	52	51	61	62	63	64	65
85	84	83	82	81	71	72	73	74	75
P	P	P	P	/	P	P	P	P	P

Stature: N/A

Pathologies: None

Notes: None

Structure 30

Age: child (3-4 years)

Dental age:

Fusion age: All neural arches are fused to each other (>2 years); cervical and some lumbar neural arches are fused to centrum (>3); thoracic neural arches remain unfused to the centrum (<5 years).

Metric age: Unobservable

Sex: Unobservable

Completeness: Partial skeleton (25-50% complete)

Preservation: Highly fragmented with no complete long bones and significant abrasion of all preserved epiphyses. Extensive surface damage is visible on the long bones, leaving a white chalky surface appearance. The vertebral column is highly fragmented but surface preservation is good. Although refitting of skull fragments was carried out, many fragments were too small to be placed. Minor surface erosion covers c. 70% of the skull surface, but is not sufficiently severe to inhibit observation of any pathological conditions. Root etching is present on the left temporal bone. The rib cage and os coxae are highly fragmented.

Dentition:

Right					Left				
P	P	P	P	P	P	P	P	P	P
55	54	53	52	51	61	62	63	64	65
85	84	83	82	81	71	72	73	74	75
P	P	/	/	/	P	P	P	P	P

Stature: N/A

Pathologies:

Dental: Mild calculus was observed on the distal surfaces of both upper deciduous first molars.

Cranial: None observed

Post-cranial: None observed

Notes: None

Structure 33/Upper individual

Age: Young adult (25-30)

Medial clavicle in late stages of fusion; auricular surface stage I-II, third molars in occlusion and worn.

Sex: Probable female

Skull sex: Probable female

Ossa coxae sex: Probable female

Completeness: Moderately complete (50-75%). N.B. Material from the two individuals in Structure 33 was curated together. A bag containing the bones of the left upper arm was not labelled and it is therefore not certain to which individual this belonged. From analysis of the excavation records it seems most likely that this belonged with the upper individual and this is assumed to be the case here, although the bones have been kept physically separate. Several loose teeth bagged with material labelled as 'Structure 1 upper' did not fit into their correct positions within the tooth row and are therefore assumed to belong with another individual.

Preservation: Moderately to poorly preserved. Shallow surface erosion of around 50% of long bones and 20% of skull. Most articular ends are damaged or destroyed. The ribs and vertebral column are generally well preserved, with occasional root etching, although many vertebral transverse processes were lost during excavation.

Dentition:

Right														Left	
P	/	P	P	P	P	/	P	/	P	P	P	P	P	P	/
18	17	16	15	14	13	12	11	21	22	23	24	25	26	27	28
48	47	46	45	44	43	42	41	31	32	33	34	35	36	37	38
/	P	P	P	P	P	P	/	/	P	P	P	P	P	P	/



*Stature:* 161cm (humerus)

*Non-metric traits:*

Cranial: See table 3

Post-cranial: None observed

*Pathologies:*

Dental: Slight to moderate calculus development on all preserved teeth with the exception of the lower right second molar. Both lingual and buccal surfaces affected on lower teeth, but buccal surfaces only were affected on upper teeth. Although no enamel hypoplasias were noted, they may have been obscured by calculus development.

Cranial: None observed

Post-cranial: None observed

*Notes:* None

*Structure 33/Lower individual*

*Age:* Middle to older adult

Most sutures completely fused. Considerable degenerative arthritis of vertebral column. Many molars lost ante-mortem, some with complete resorption of root space.

*Sex:* Possible female

Skull sex: Possible female

Ossa coxae sex: Possible female

*Completeness:* Moderately complete skeleton (50-75%). N.B. Some elements curated with this individual have been removed as they overlapped with preserved areas and therefore cannot have originated from the same person. At least one extra proximal manual phalange is present (presumably from the upper individual), but as it cannot be ascertained which this is, none have been removed. Several loose teeth could not be refitted into the maxilla or mandible and also seem not to have been associated with the upper individual. They have therefore been excluded from the analysis. No attempt has been made to side manual or pedal phalanges.

*Preservation:* Moderately to poorly preserved. Most skeletal elements are fragmented to some degree and shallow surface erosion covered 25-75% of preserved long bones. Damage to the midshaft region of the left femur may have been caused by the action of burrowing land crabs (*Cardisoma carnifex*).

*Dentition:*

Right																Left
A	X	P	P	P	P	/	X	X	/	P	P	P	P	P	A	
18	17	16	15	14	13	12	11	21	22	23	24	25	26	27	28	
48	47	46	45	44	43	42	41	31	32	33	34	35	36	37	38	
A	X	X	P	/	P	P	P	/	/	/	X?	/	X	X	A	

*Stature:* Unobservable

*Non-metric traits:*

Cranial: See table 3

Post-cranial: bilateral septal aperture

*Pathologies:*

Dental pathologies: Periodontal disease of both mandible and maxilla with pitting and resorption of the alveolar process. All mandibular molars were lost ante-mortem with almost complete resorption of the alveolar bone. A possible remnant abscess cavity is visible on the lingual surface of the left mandibular body at the position of the first molar. This is in the later stages of healing and is therefore hard to diagnose with certainty. A second possible abscess cavity is present on the lateral right mandibular body at the position of the first premolar, which has been lost a relatively short time ante-mortem. The cavity has sharp margins and is porous internally. All teeth remaining in the alveolar process are affected by

dental calculus. The maxillary left first and second molars are both affected by carious lesions.

Osteoarthritis: Osteophytes were observed at the following locations: right medial clavicle (with pitting; left is unaffected); left sacro-iliac joint (right unobservable); right and left acetabulae.

Spinal osteoarthritis: Osteophytosis of all observable vertebral bodies, often accompanied by pitting. Few articular facets preserved, but T6, and one of two preserved lumbar vertebra articular facets show osteophytosis, pitting and sclerosis.

Postcranial:

There is a minor exostosis 1 cm above the nutrient foramen on the right radius.

Abnormal curvature of right femur shaft, with antero-posterior curving and thickening of the diaphysis at midshaft. No evidence of abnormal bone formation or resorption at surface and no cloacae. No evidence of fracture callus. The distal epiphysis is not preserved, so it is not possible to assess possible shortening. The femoral head appears normal. Left femur appears normal, making it unlikely that this individual was suffering from rickets. Probable healed childhood shaft fracture.

The right scapula exhibits os acromiale, or non-fusion of the acromion process probably due to over-use of the shoulder in adolescence and early adulthood. The left scapula is normal.

*Notes:* None