

Oral Board Review: Cardiac

Rich Hallett, MD

April 2012

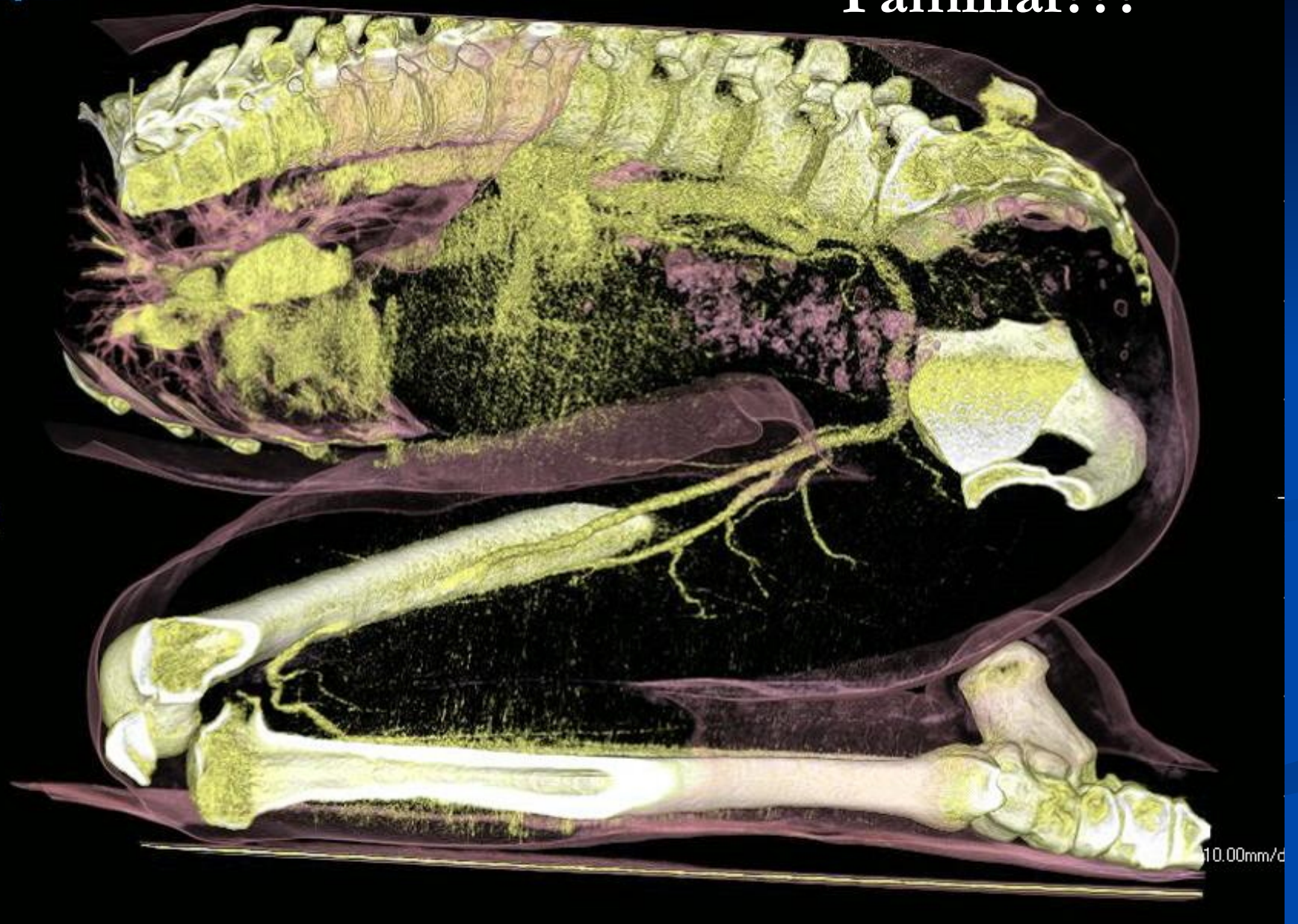<http://www.stanford.edu/~hallett>

Choose folder “Mayo”

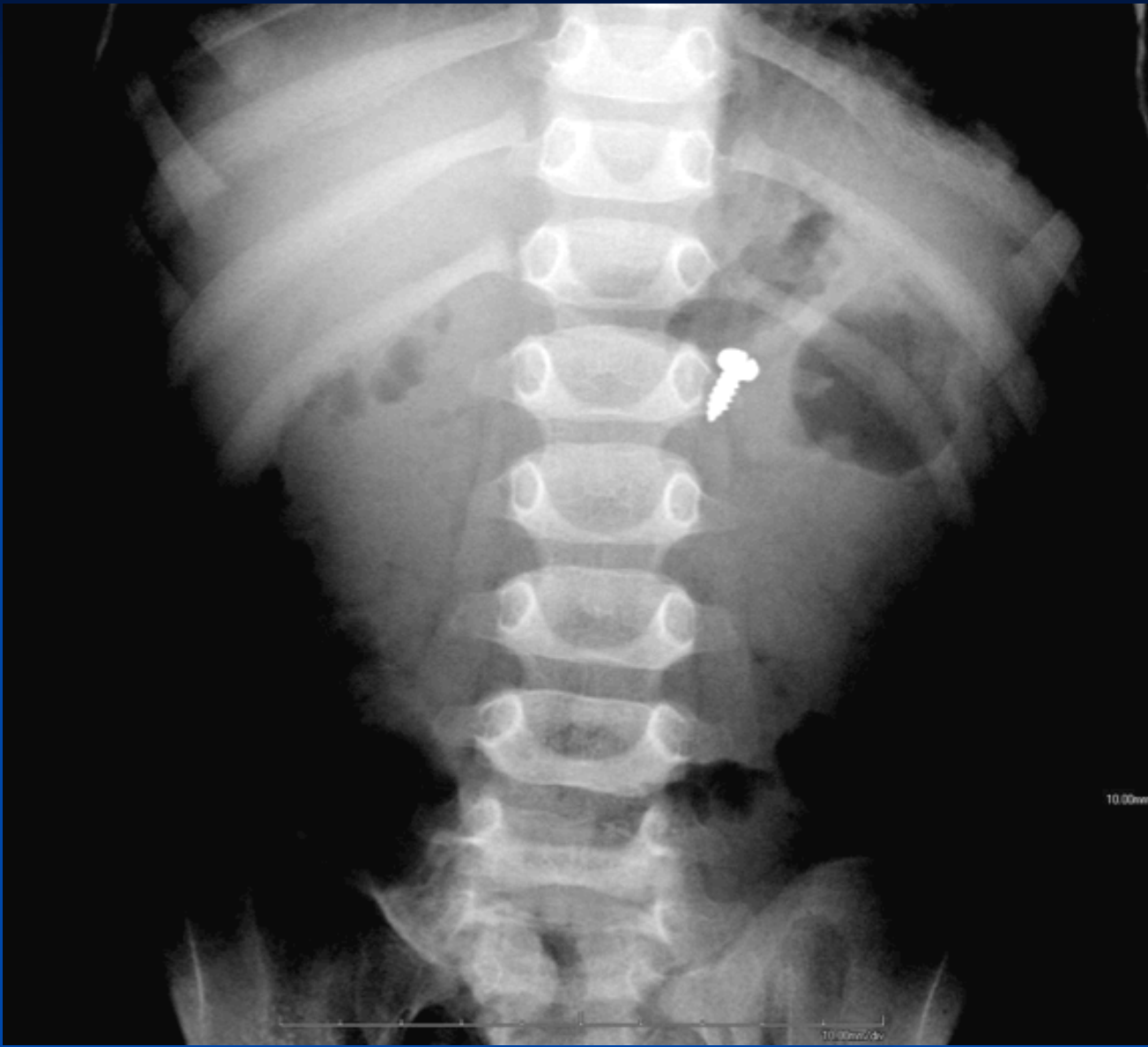xraydoc97@yahoo.com

Mag: 1.00

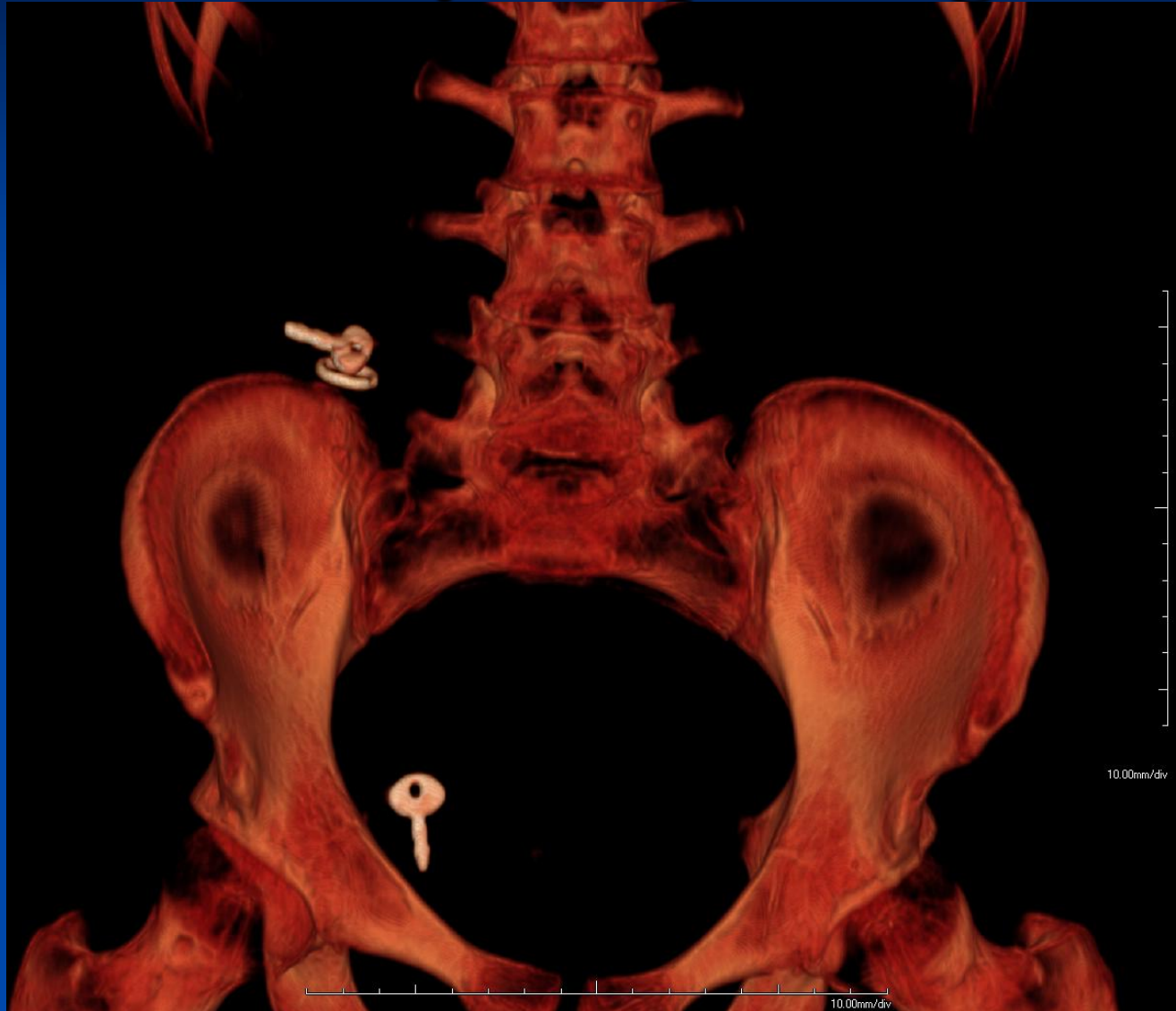Familiar???



10.00mm/d



The keys to passing:

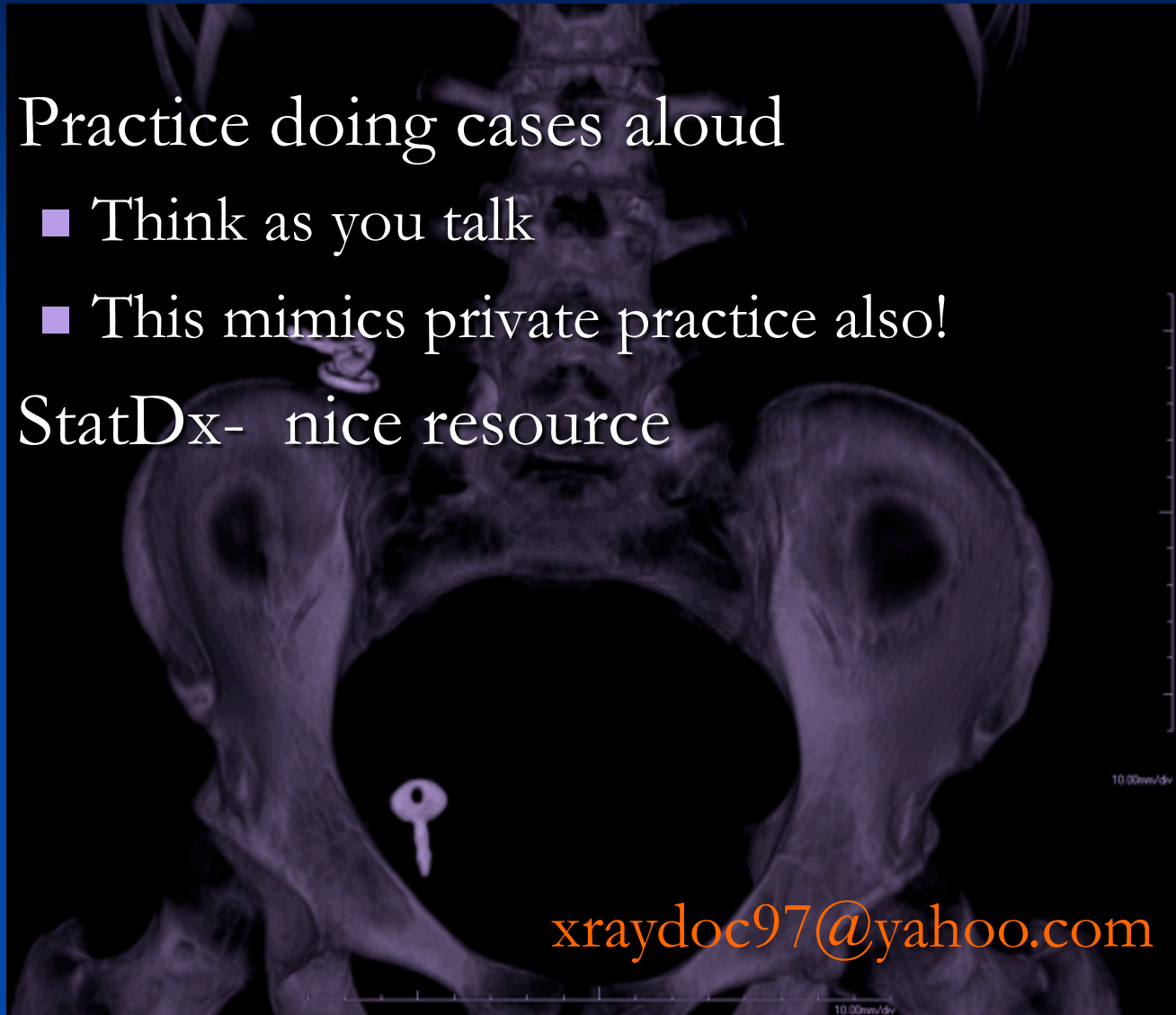


Pearls

- You have studied enough
- You know enough
- I am not here to fail you
- I am here to help (You must ask)
- You will NOT fail if you miss a case
- **BUT: You MIGHT fail if you lose your cool**
- “You can be dumb if you aren’t stupid”.

Pearls

- Practice doing cases aloud
 - Think as you talk
 - This mimics private practice also!
- StatDx- nice resource



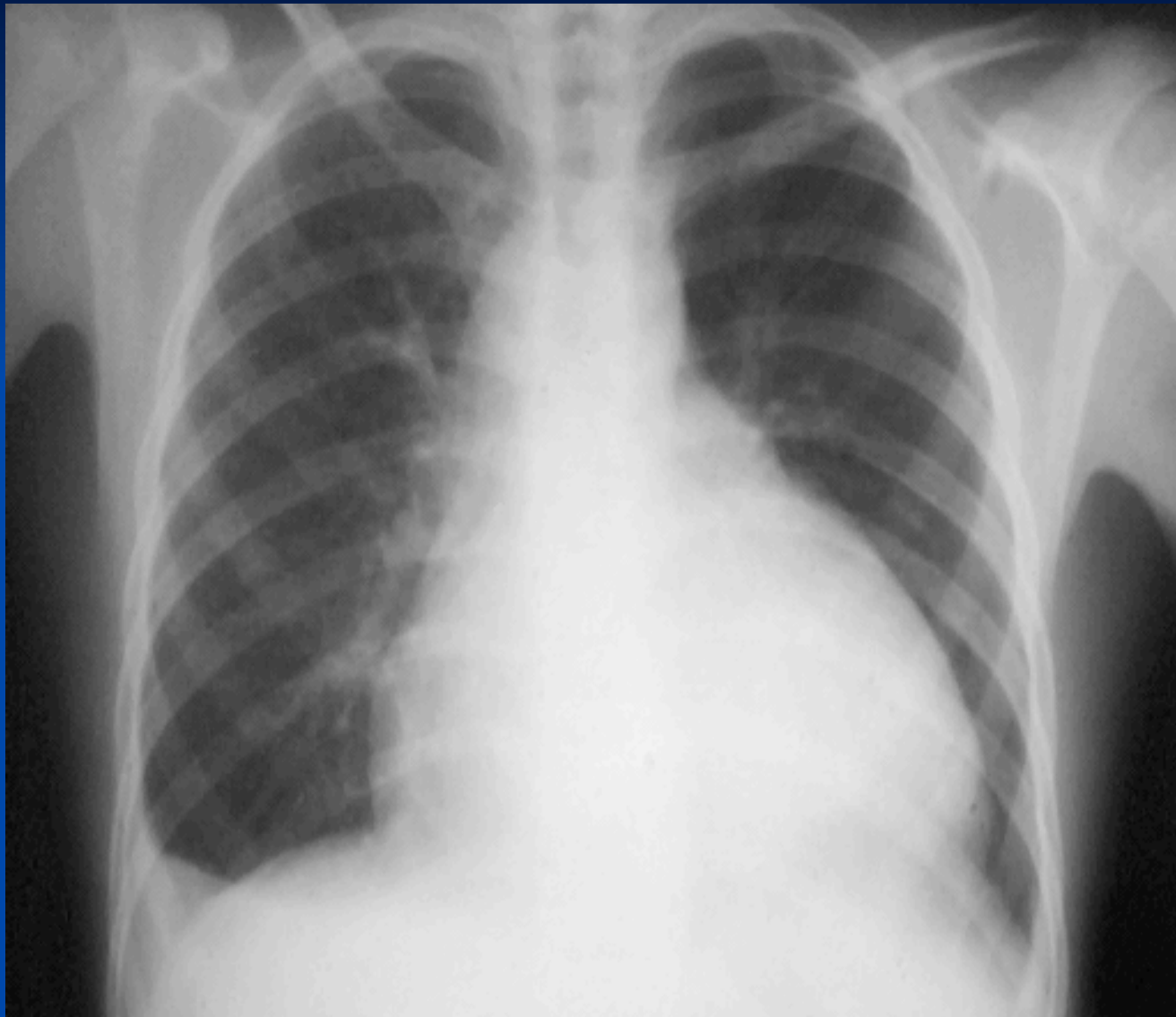
“Virtual” Cardiac Section

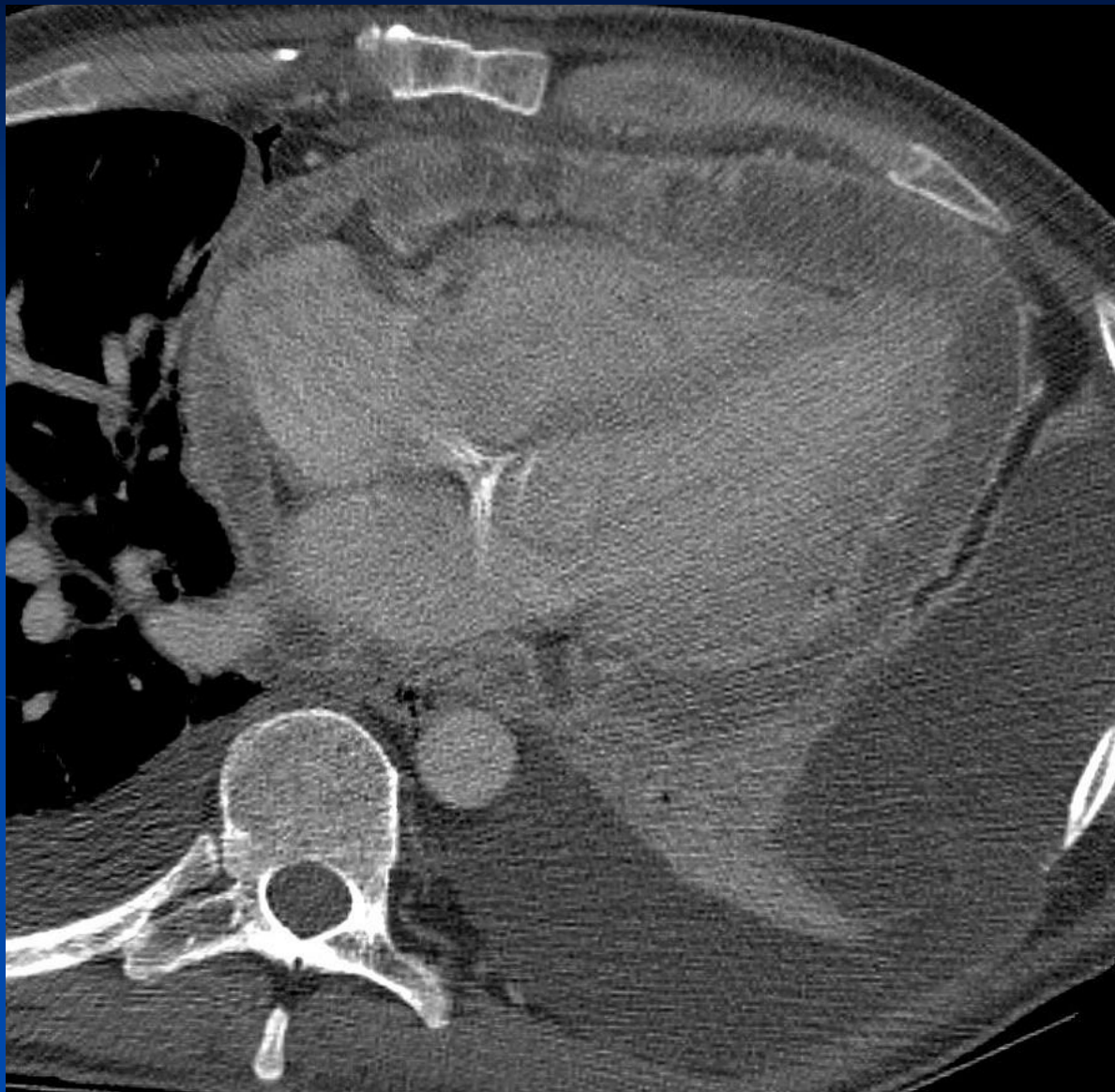
- Will see cases in several sections
- Chest, Peds, Interventional
- I will give you the section you’re in, and some images

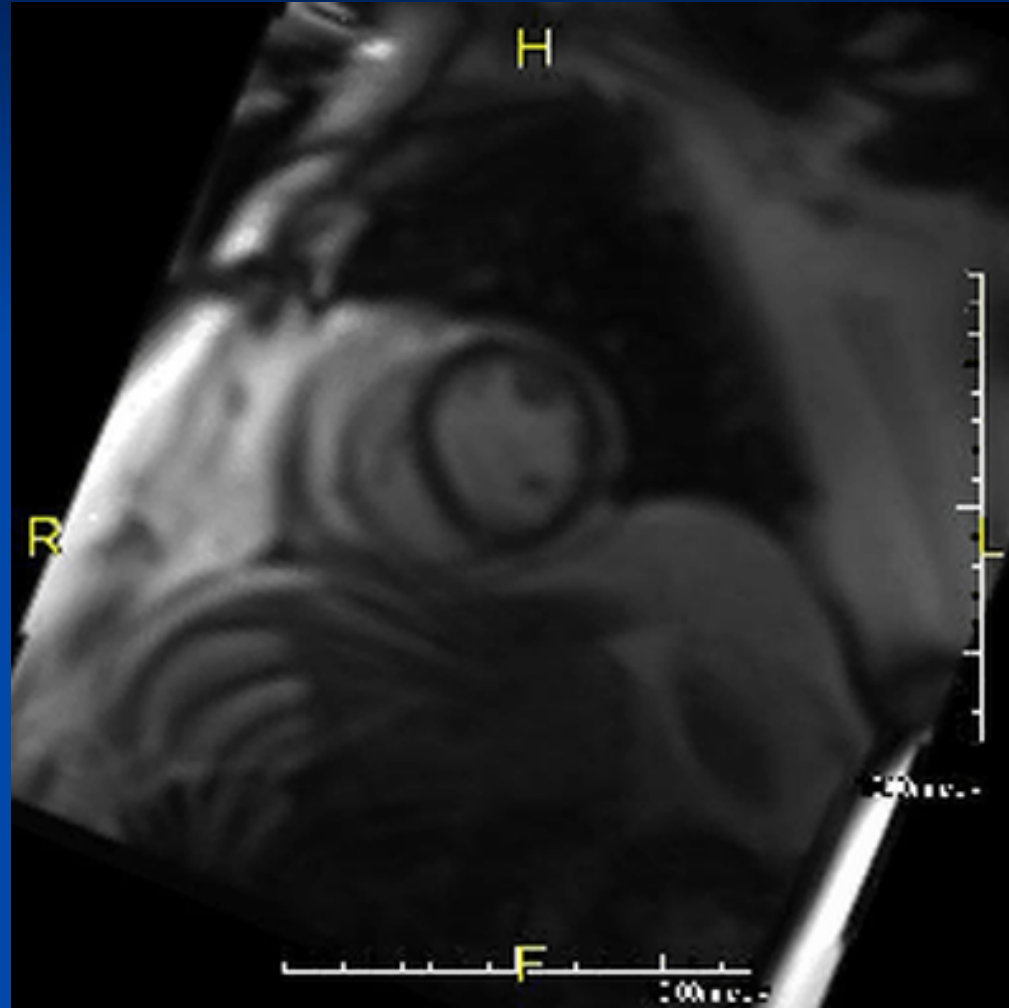
<http://www.stanford.edu/~hallett>

Choose folder “Mayo”

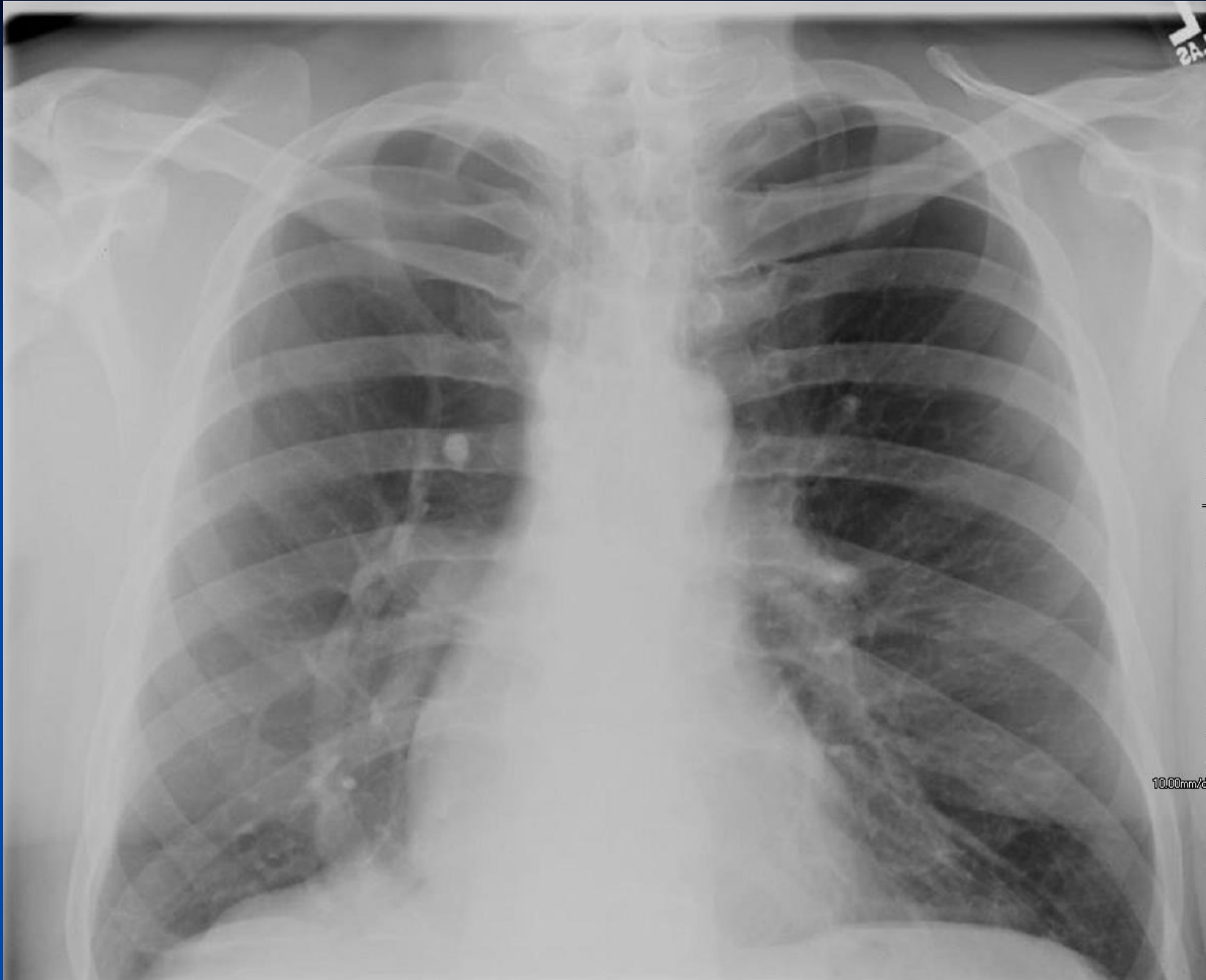
Chest

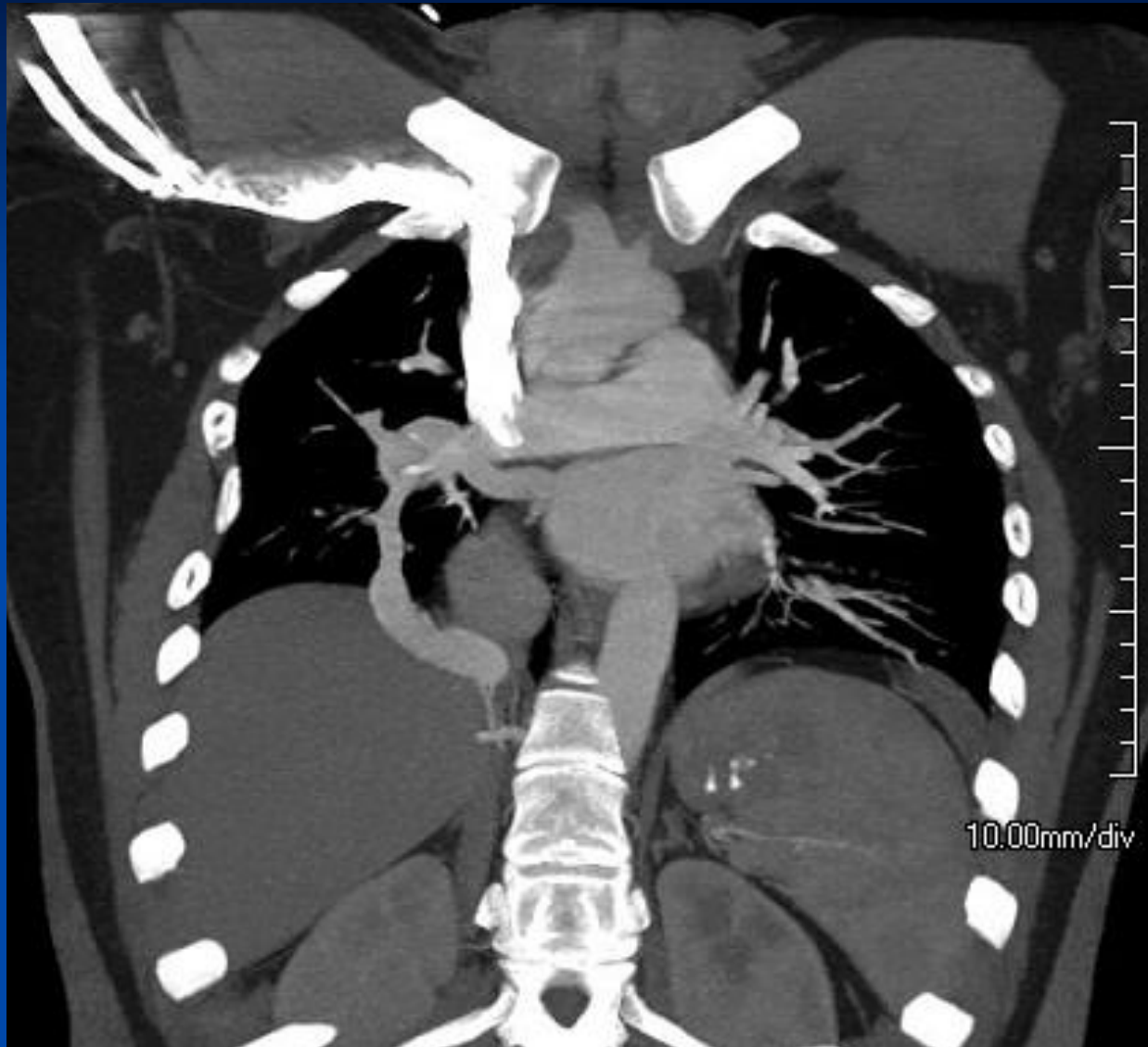




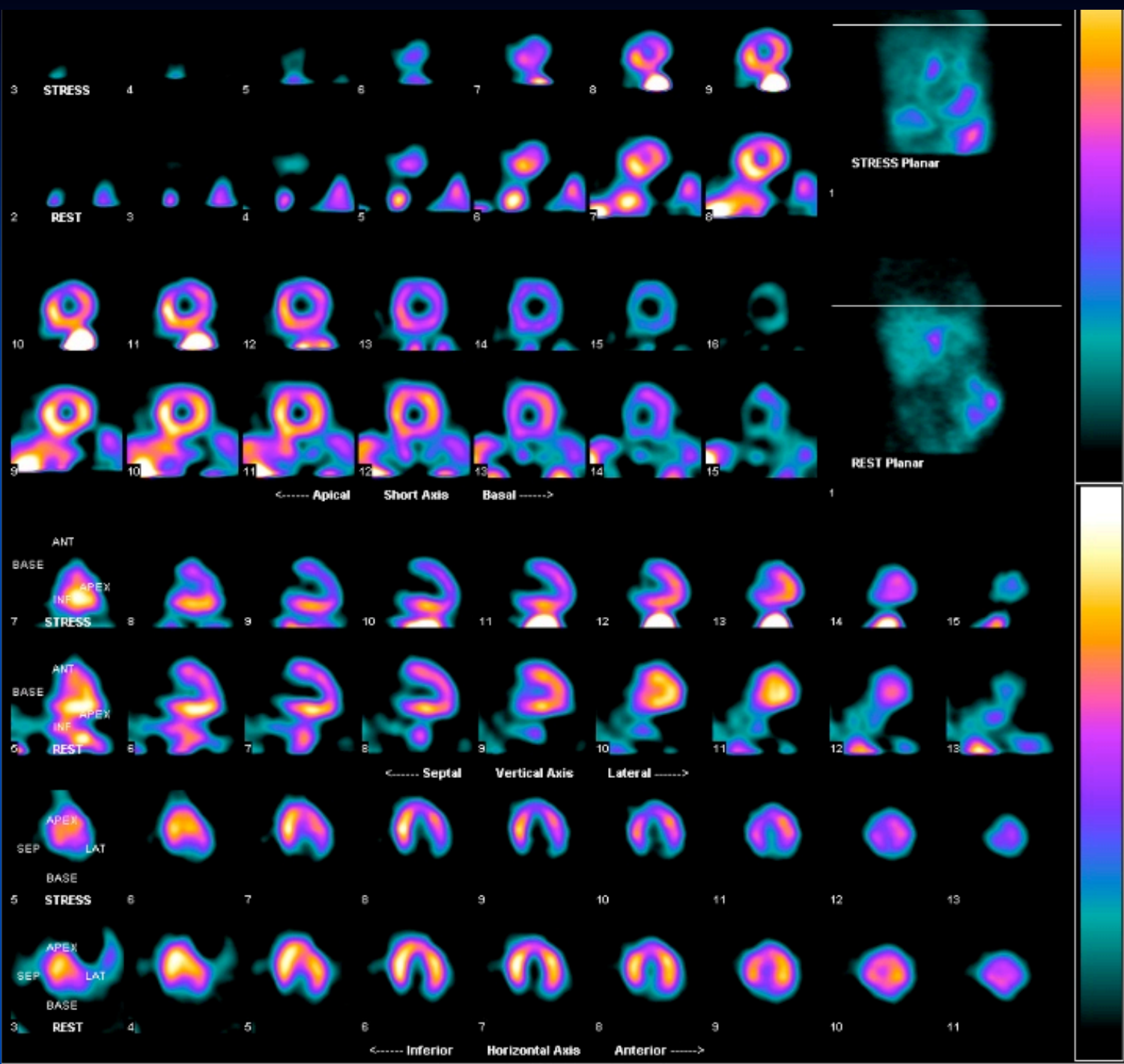


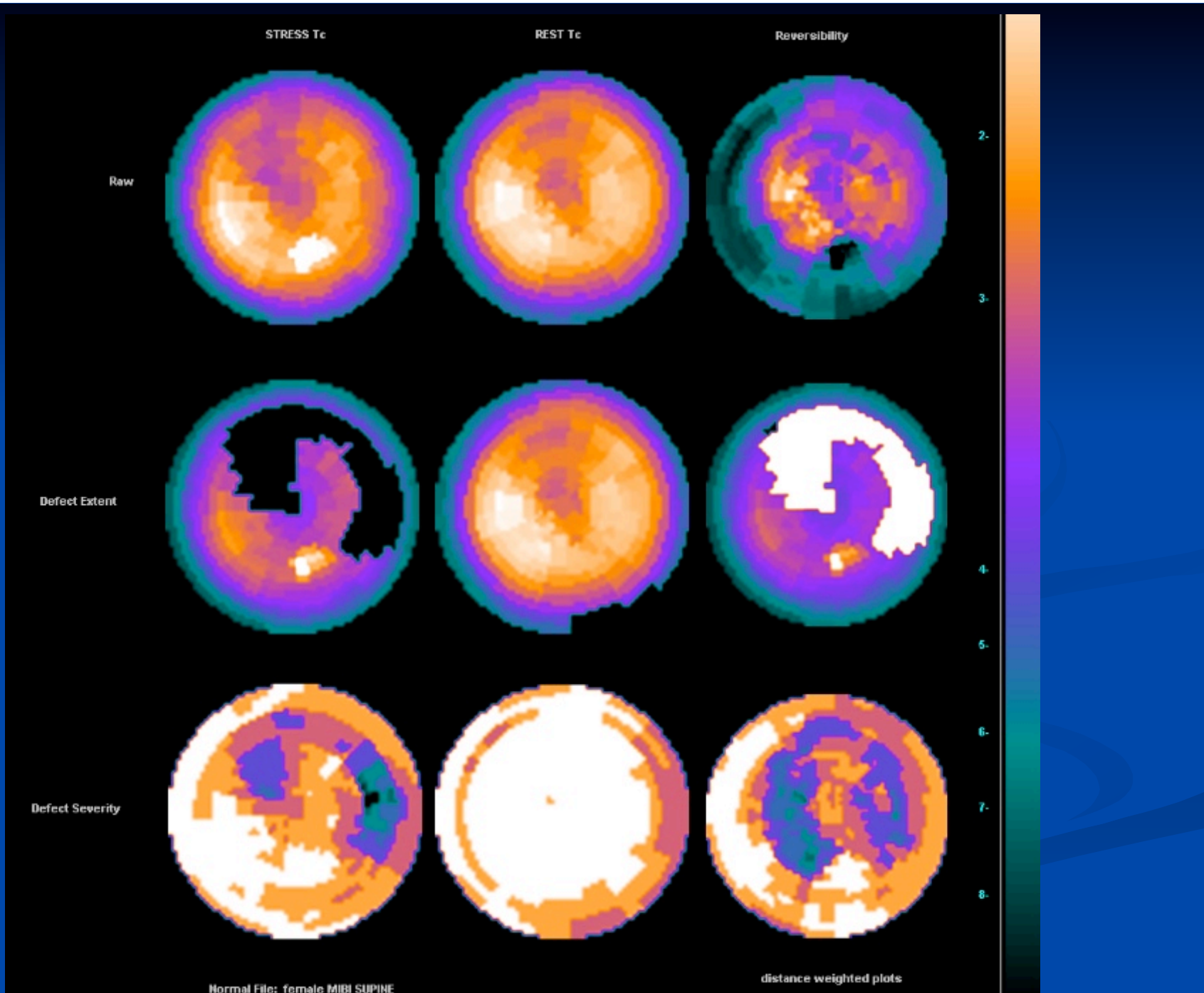
CHEST



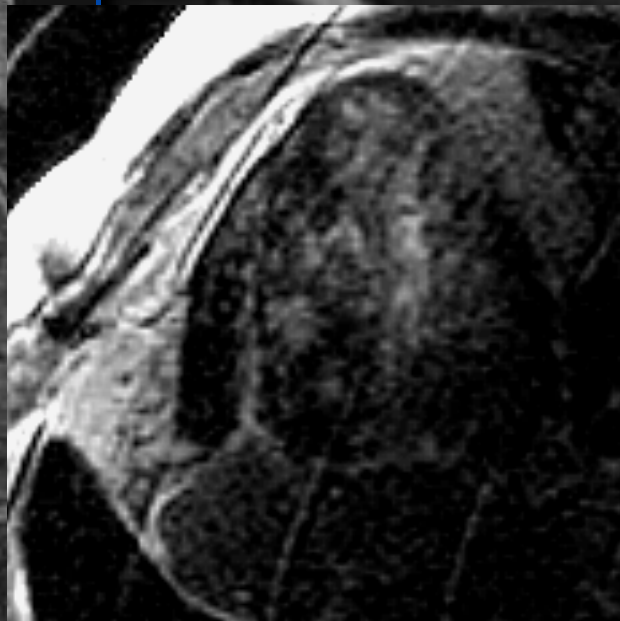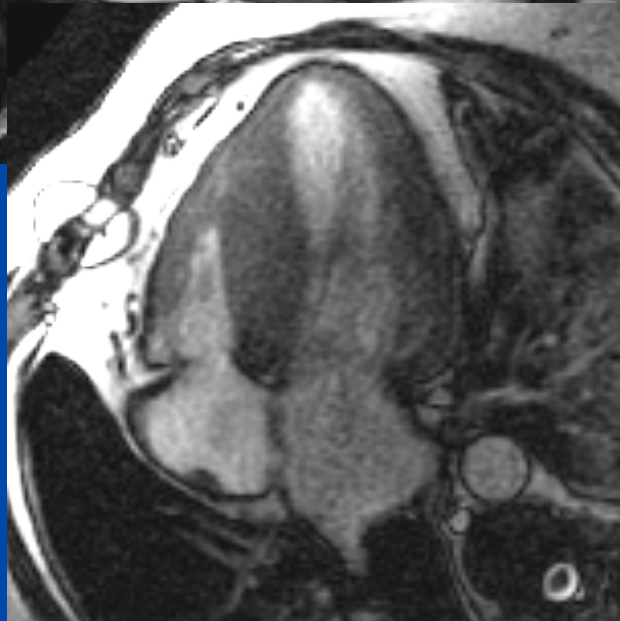
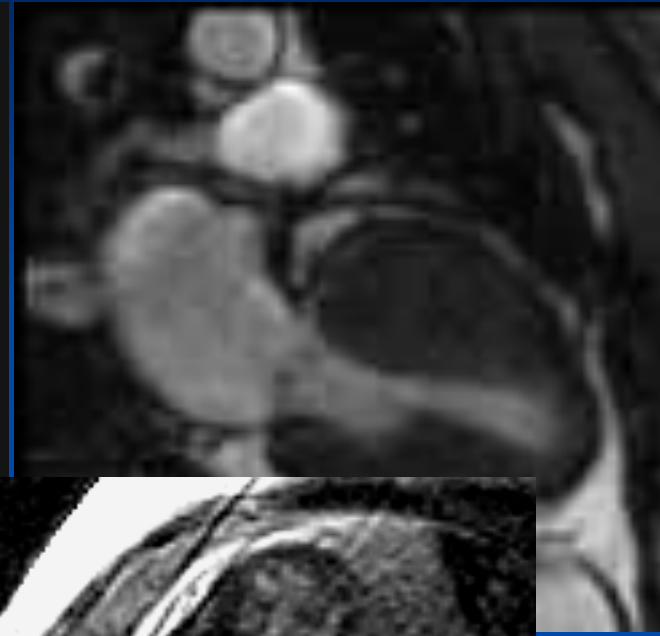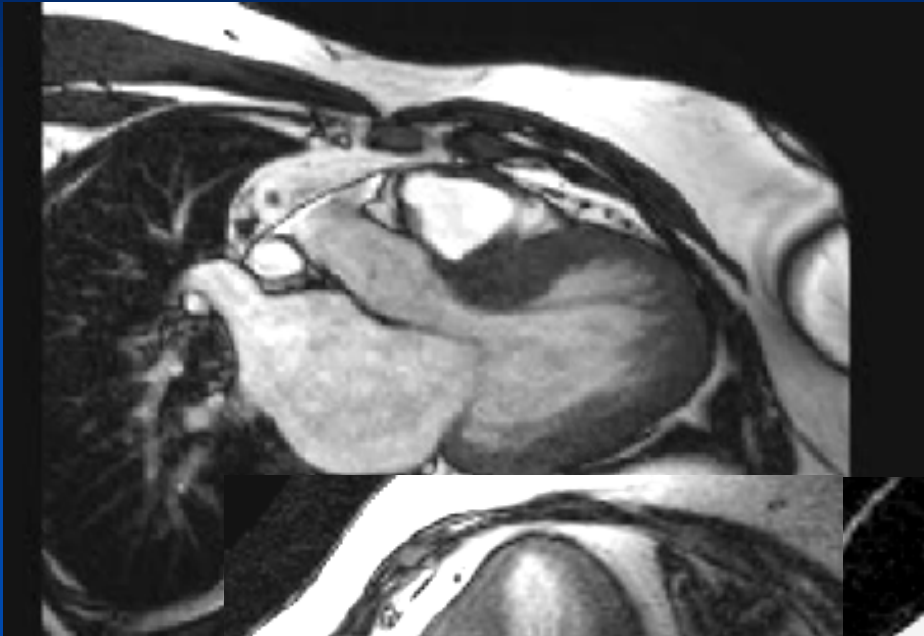


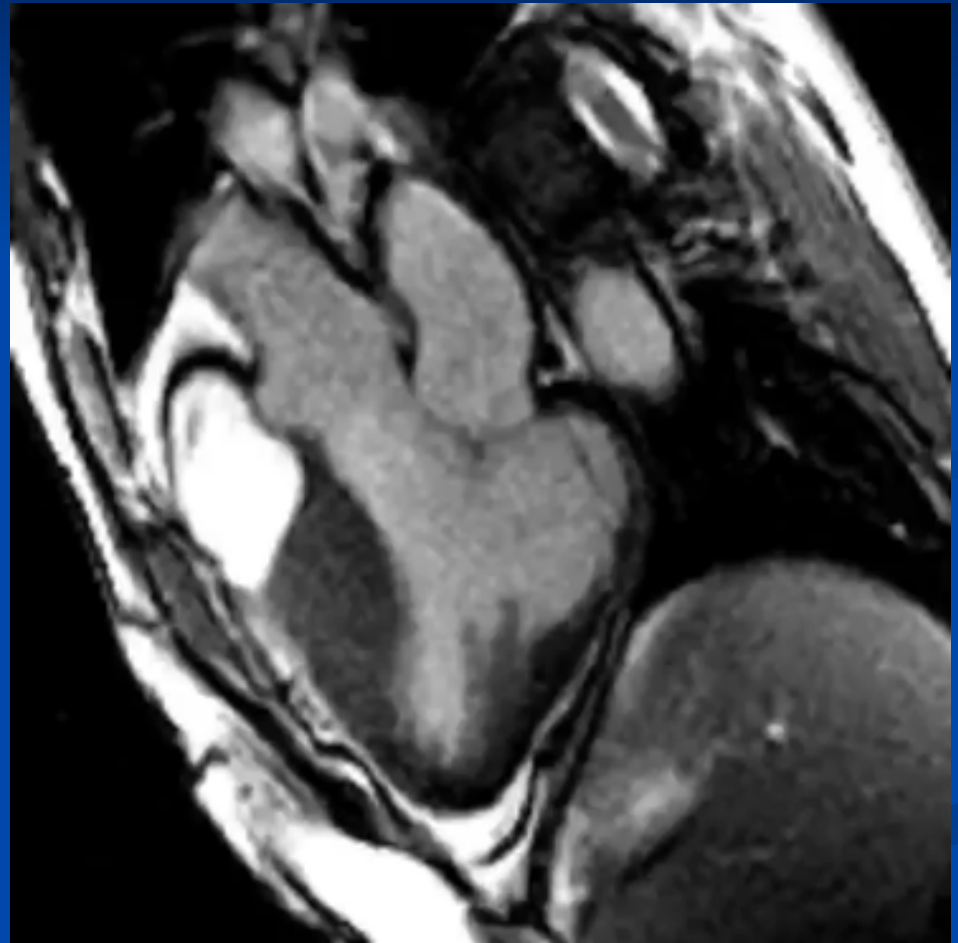NUCS



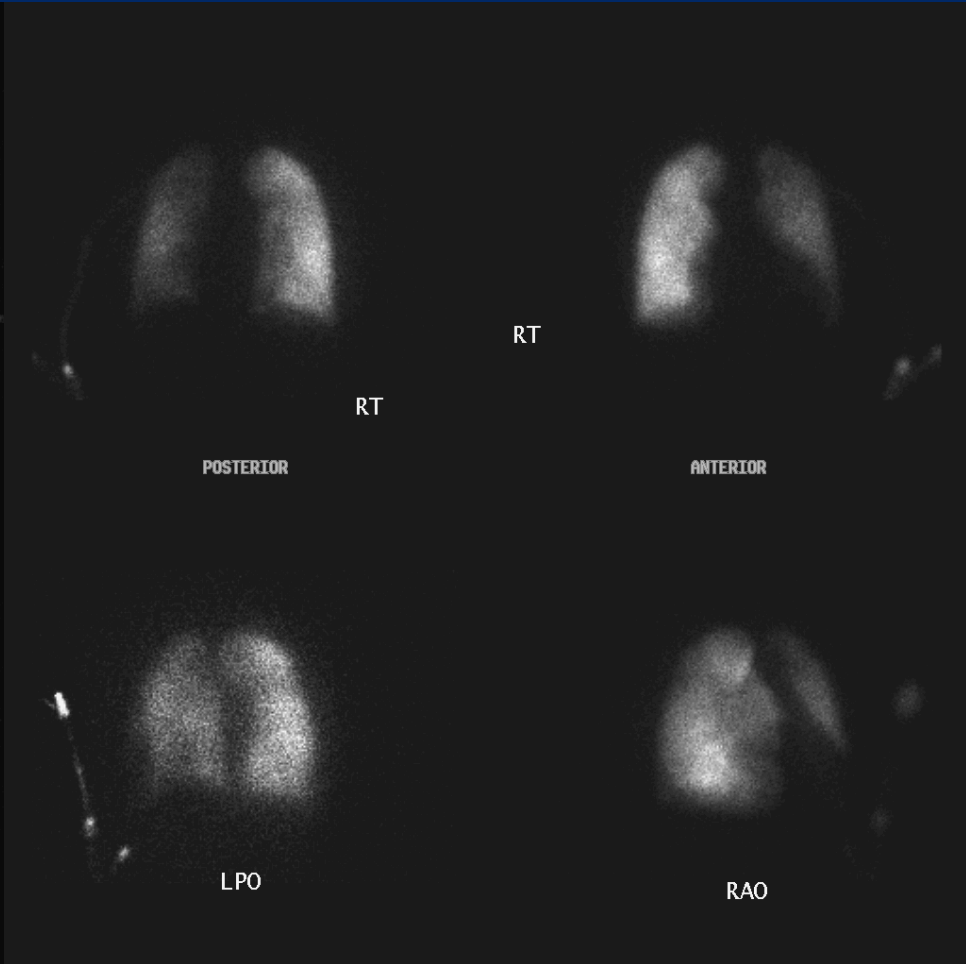
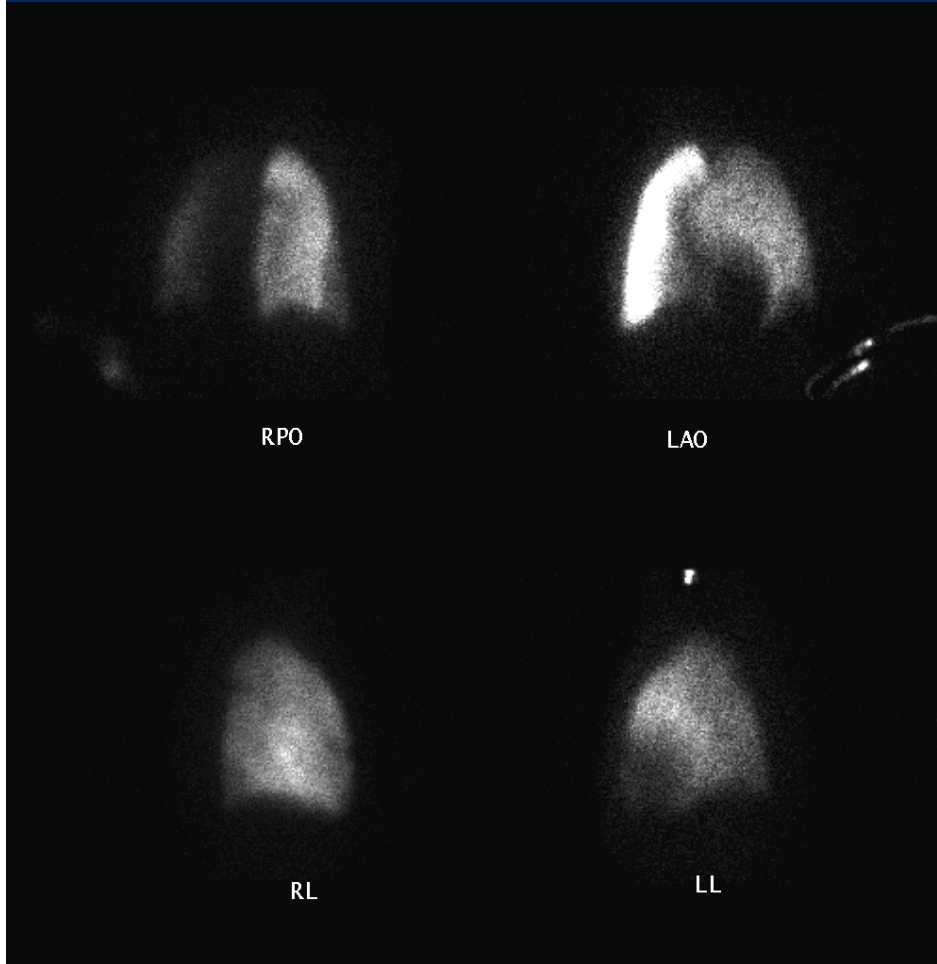


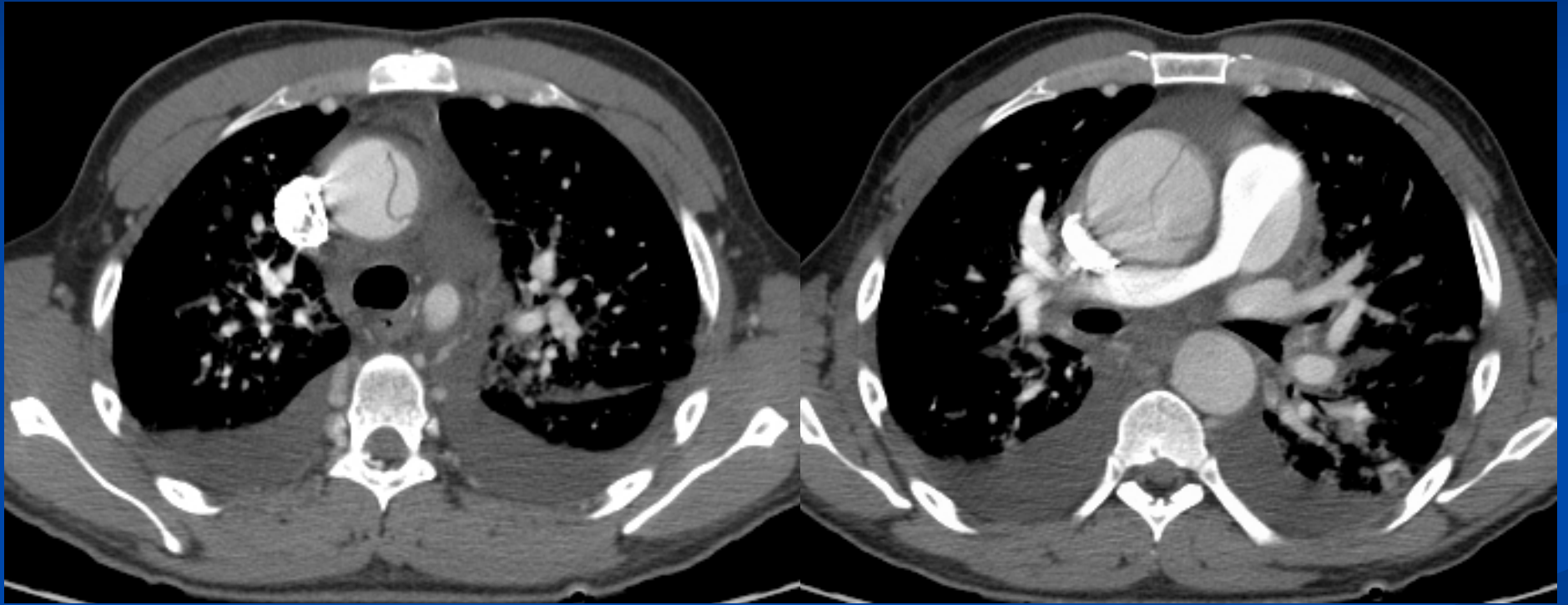
Chest



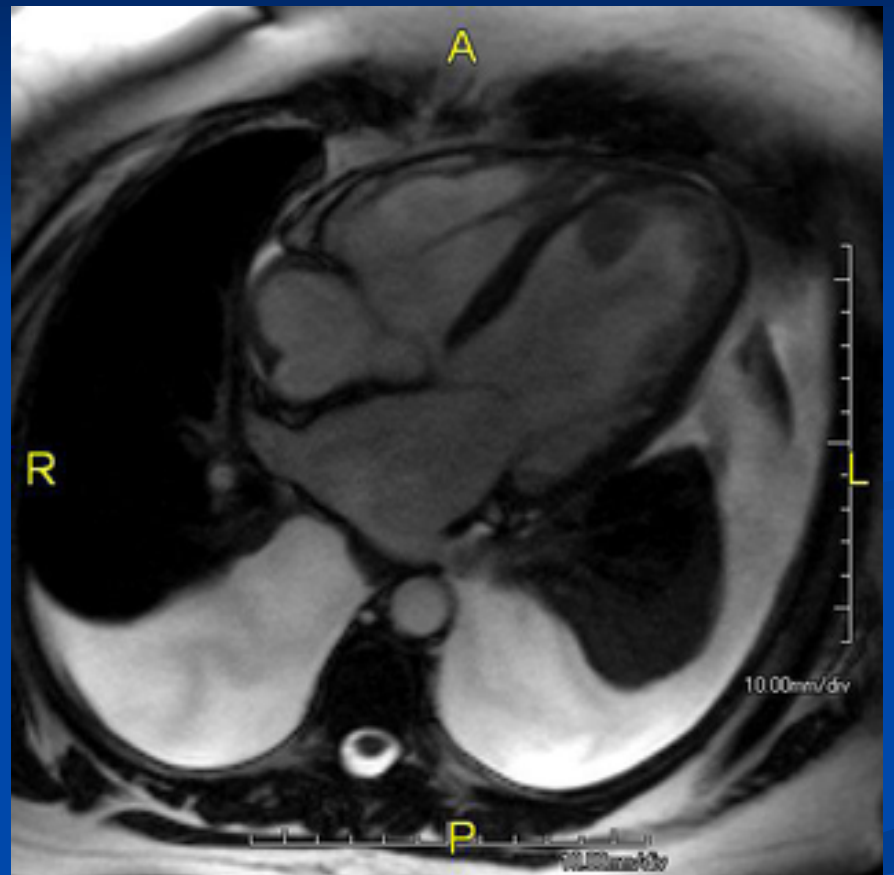
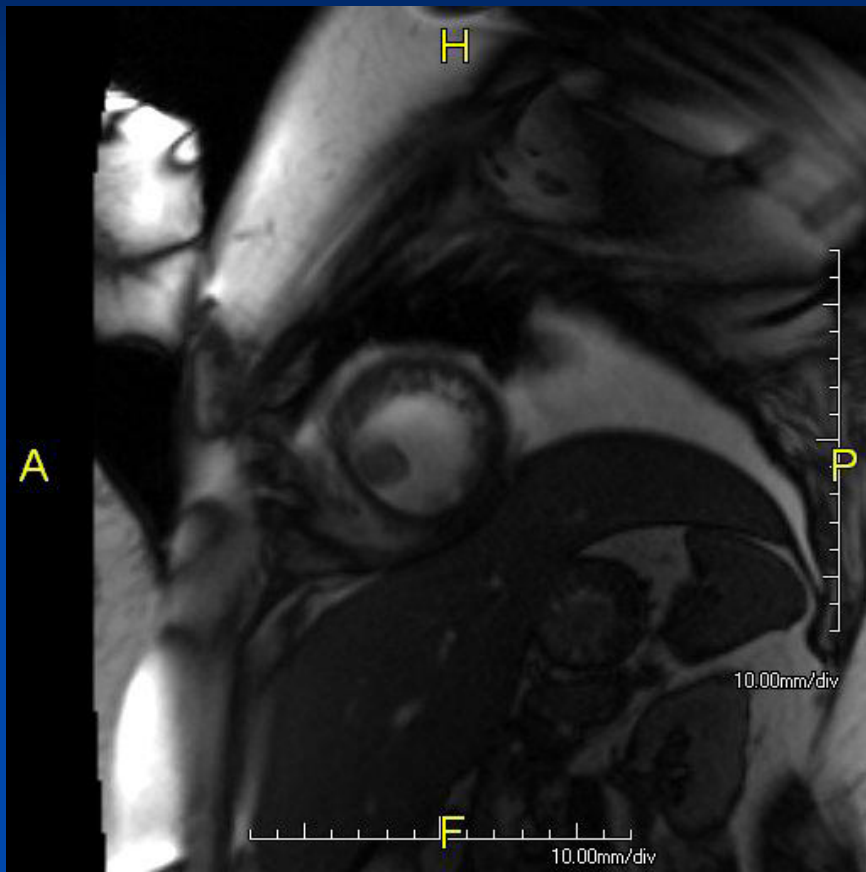


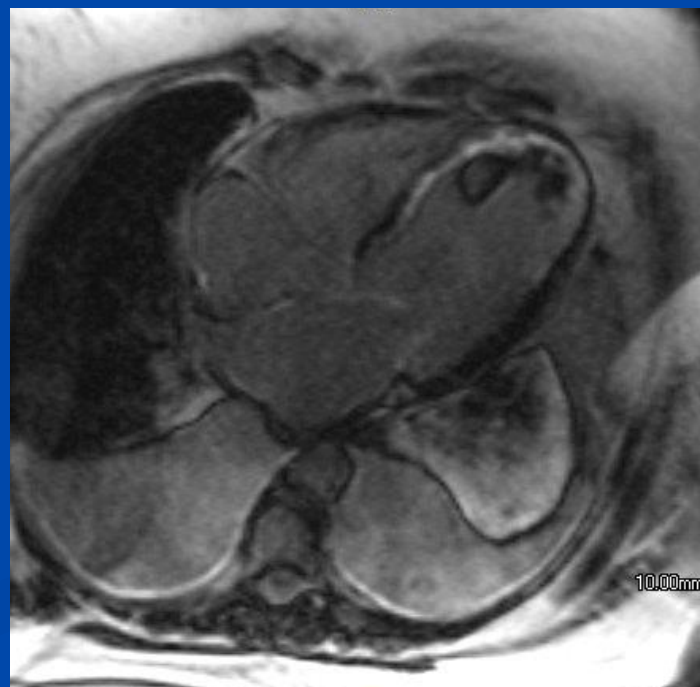
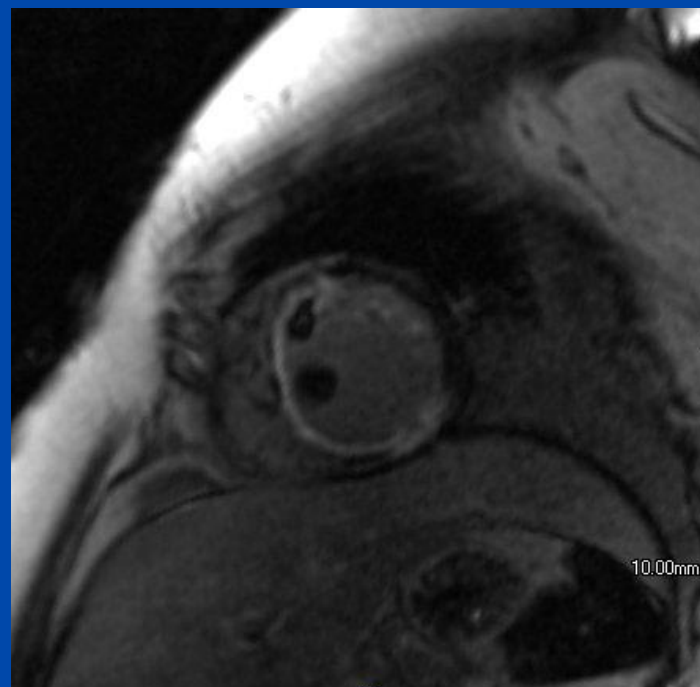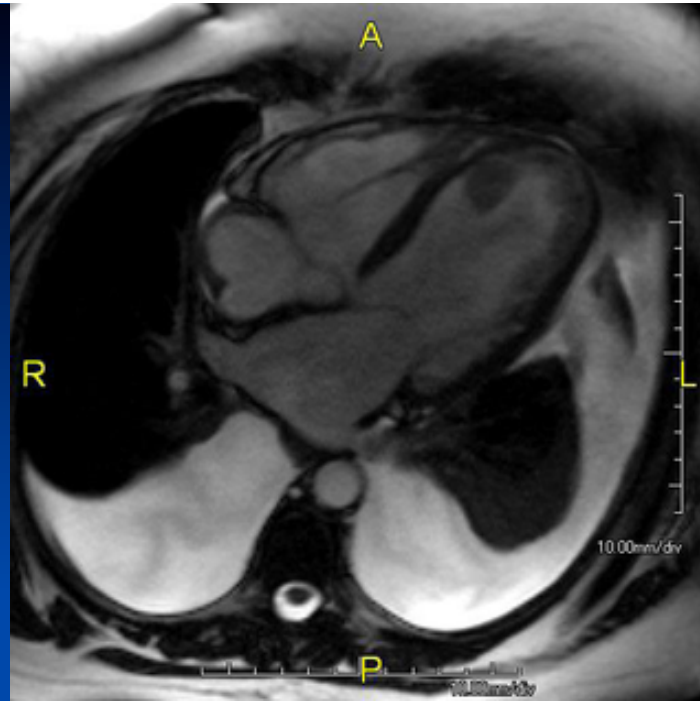
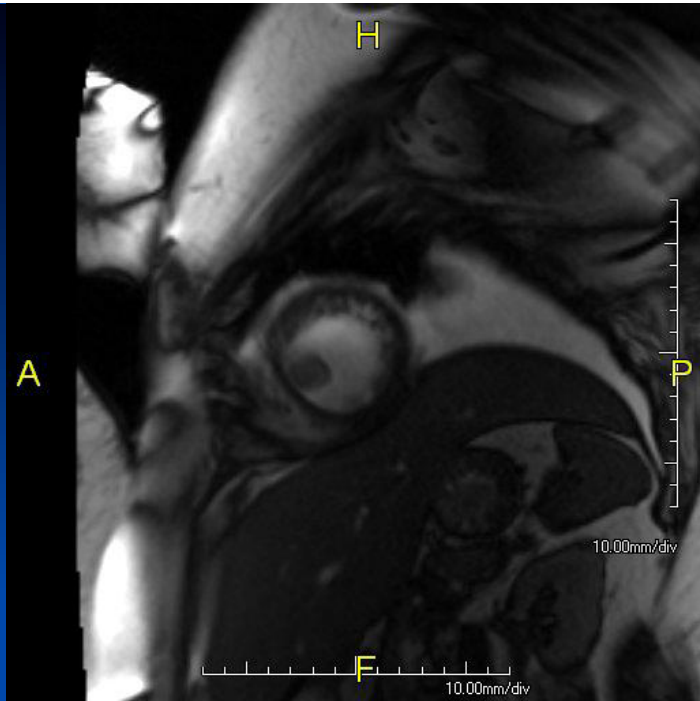
NUCS



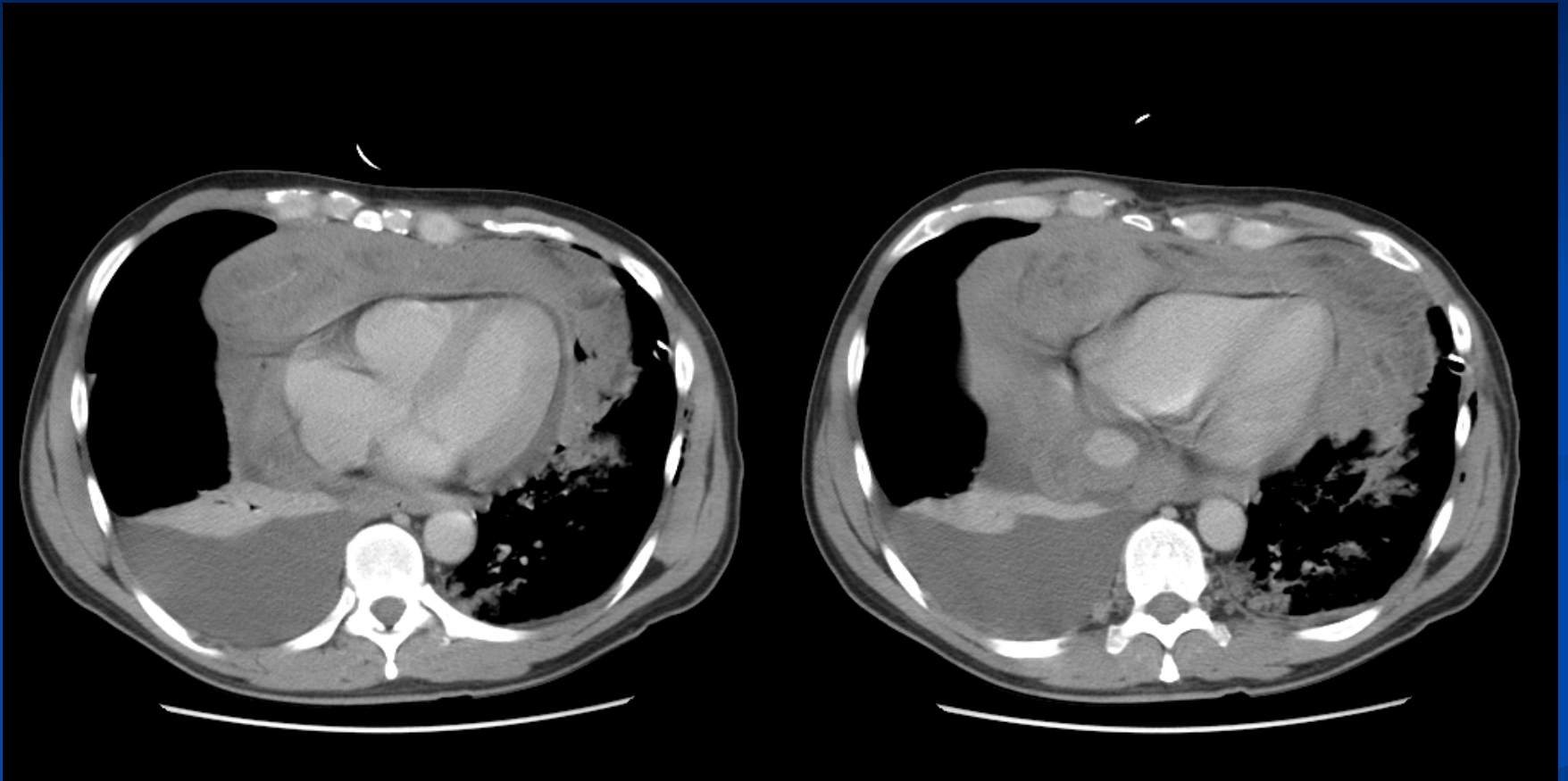


CHEST

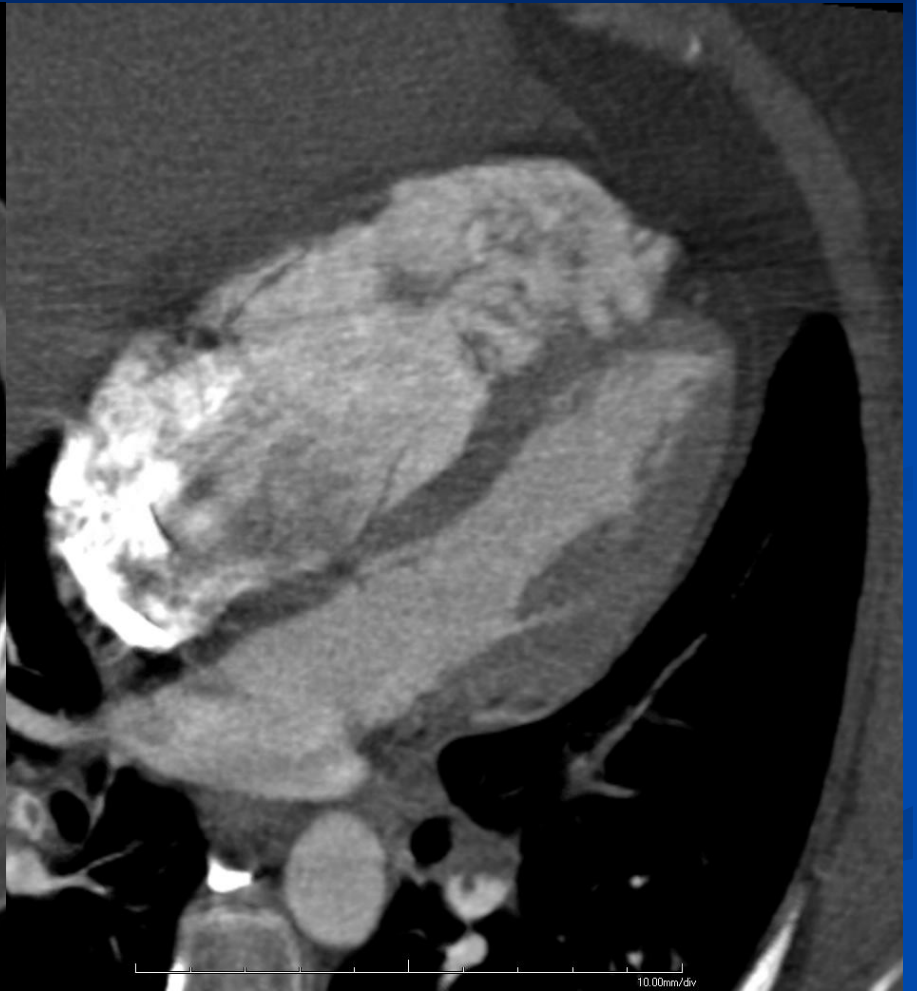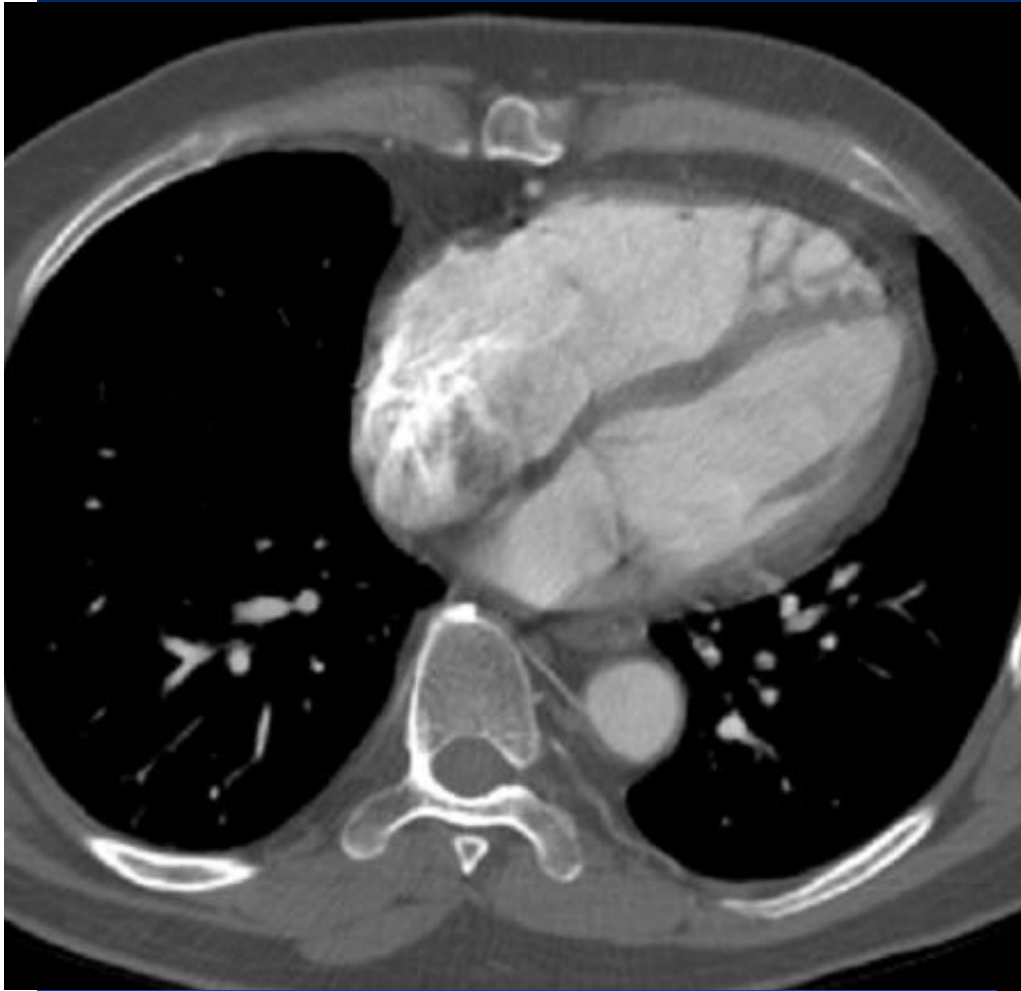


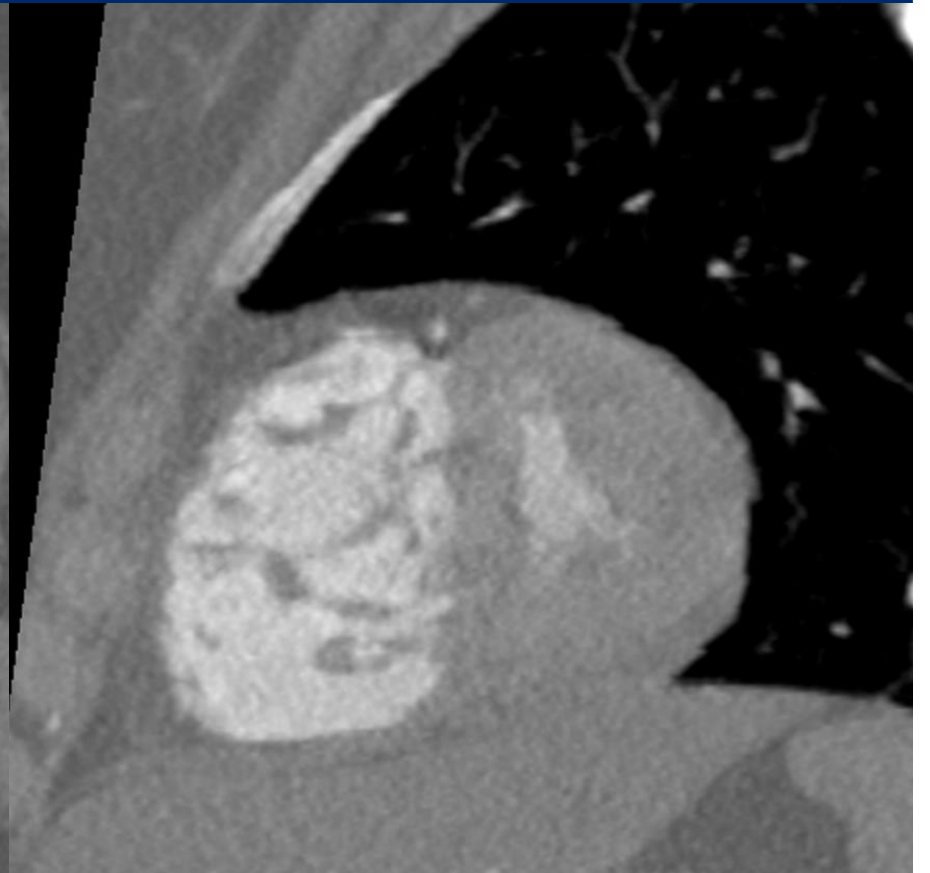
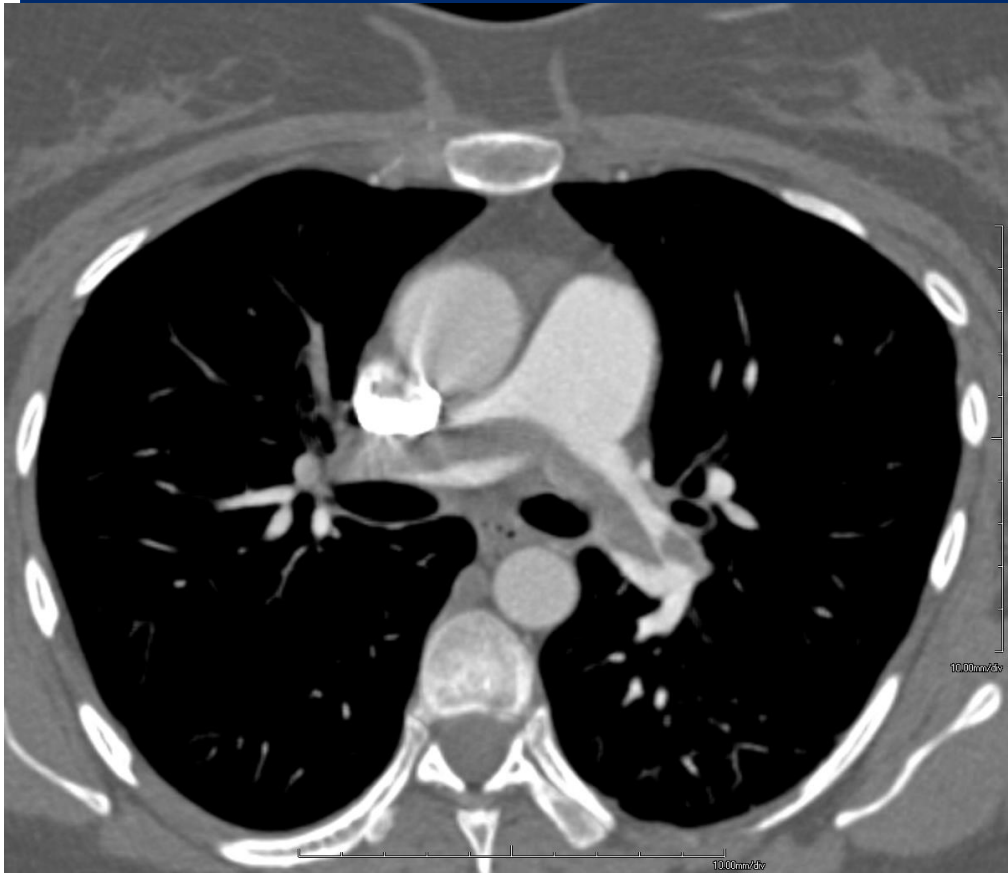


PEDS



CHEST

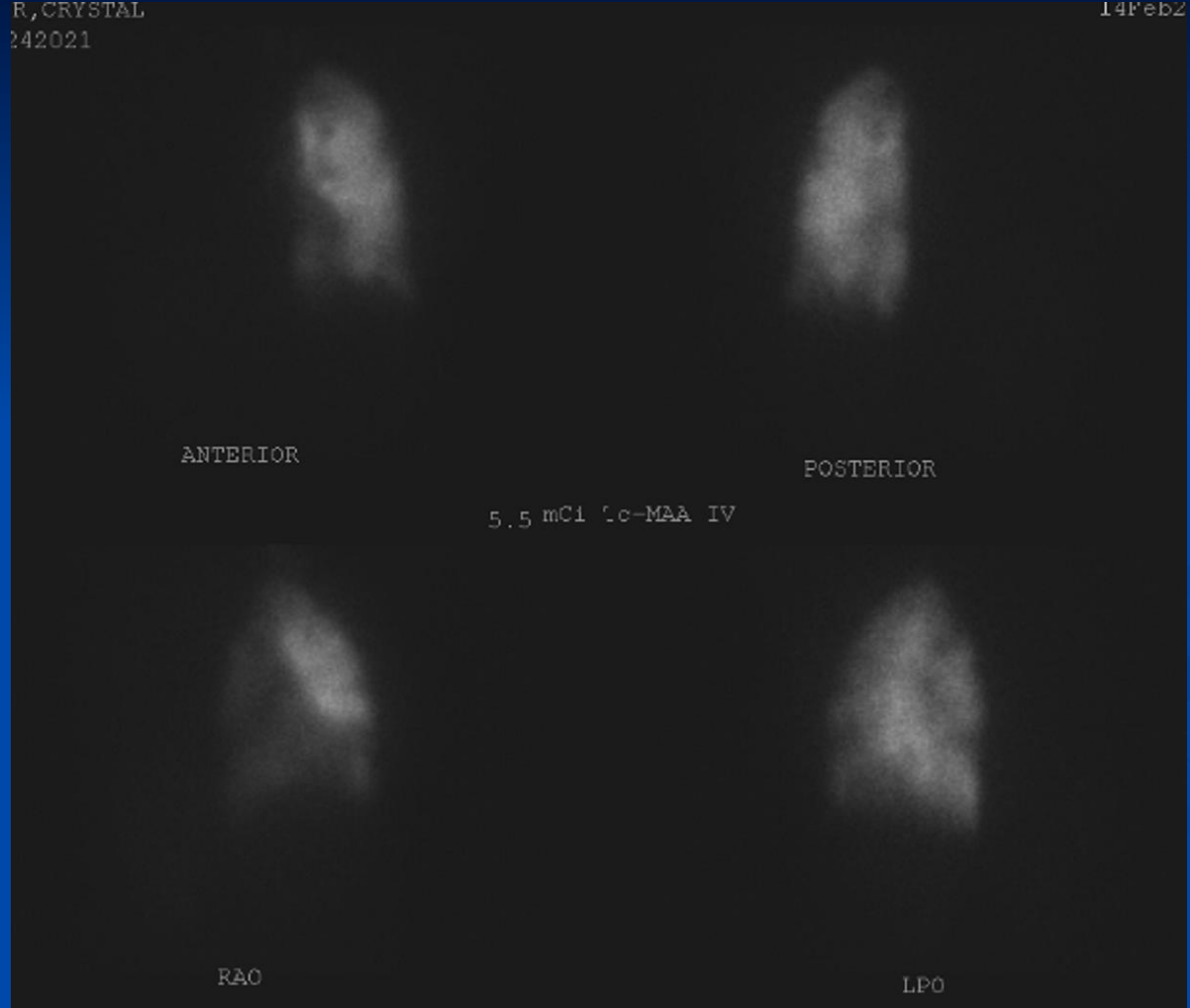




NUCS

R, CRYSTAL
242021

14Feb2



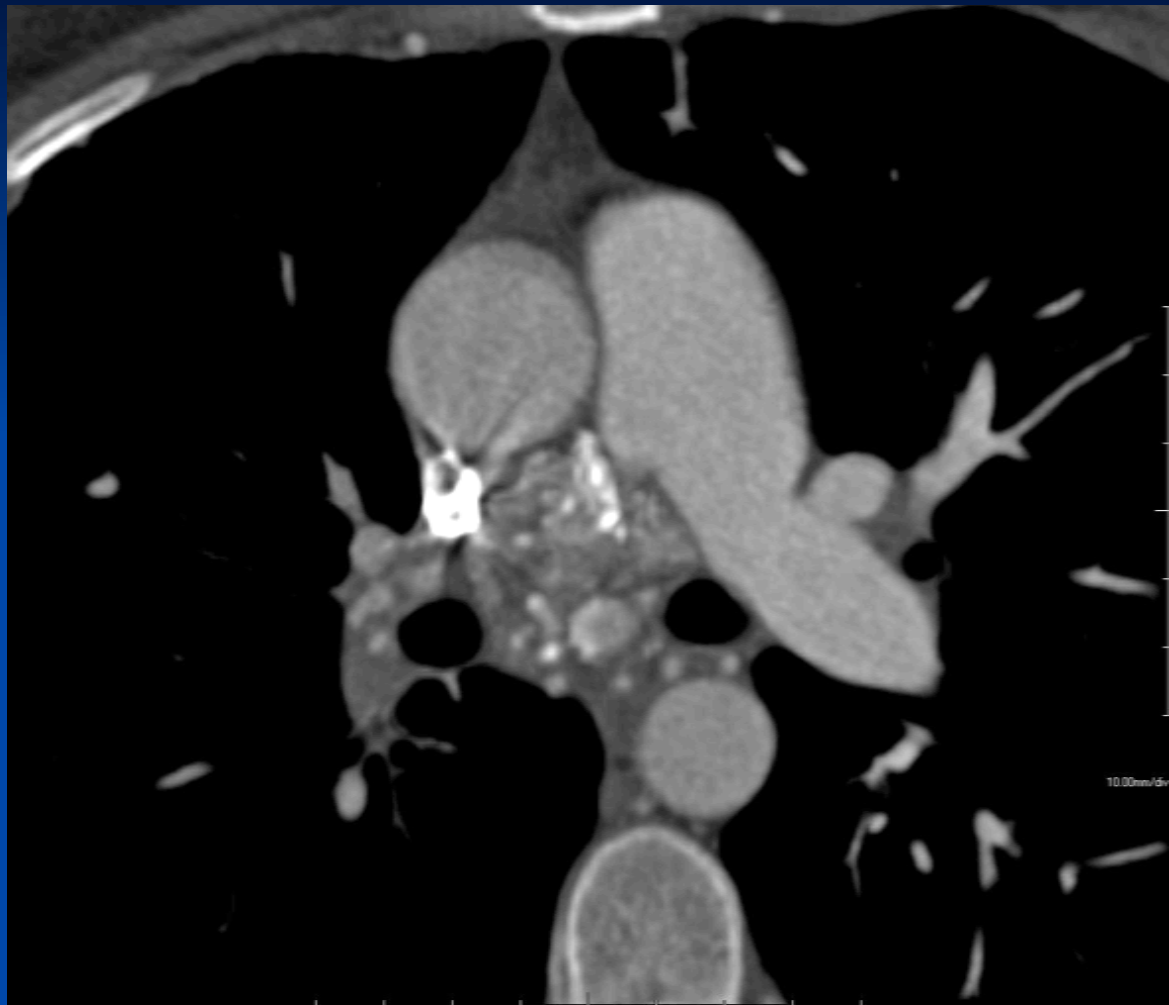ANTERIOR

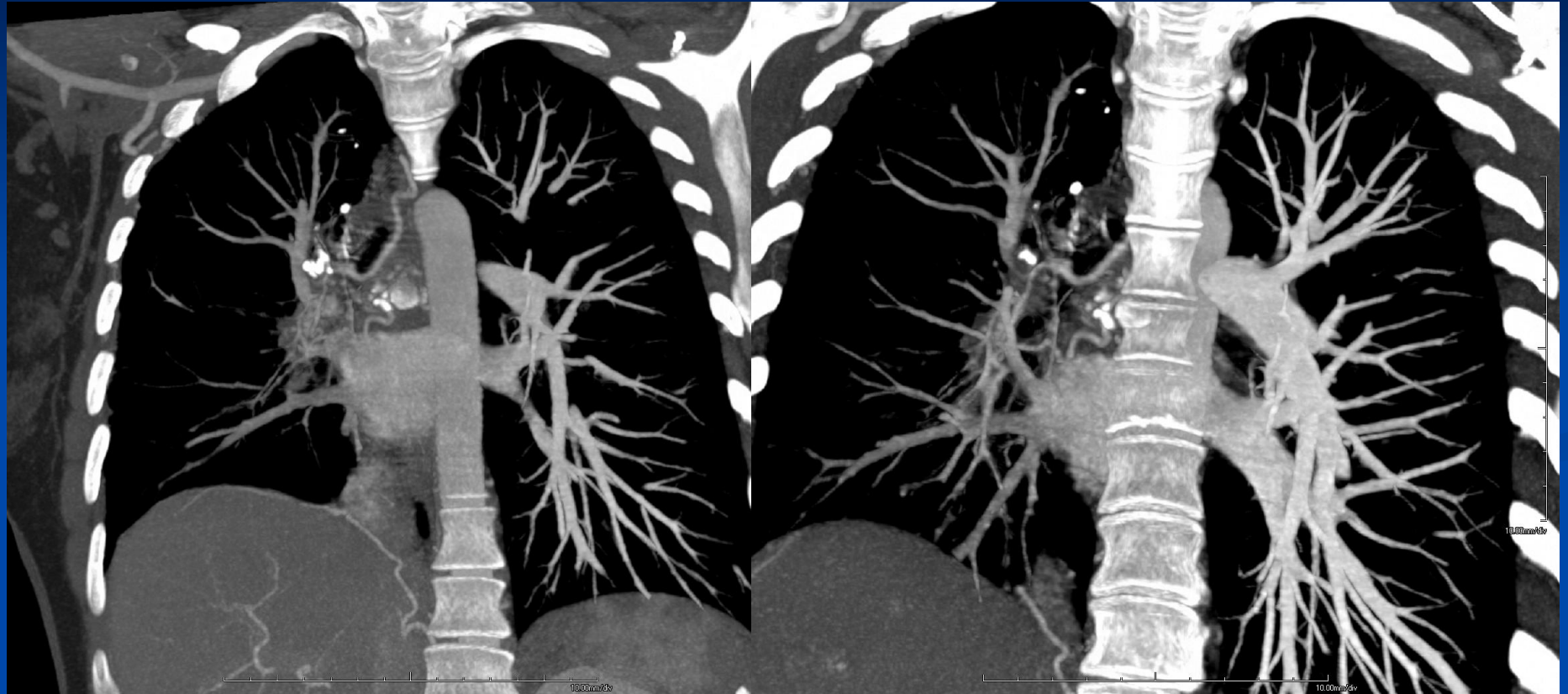POSTERIOR

5.5 mCi ^{99m}Tc-MAA IV

RAC

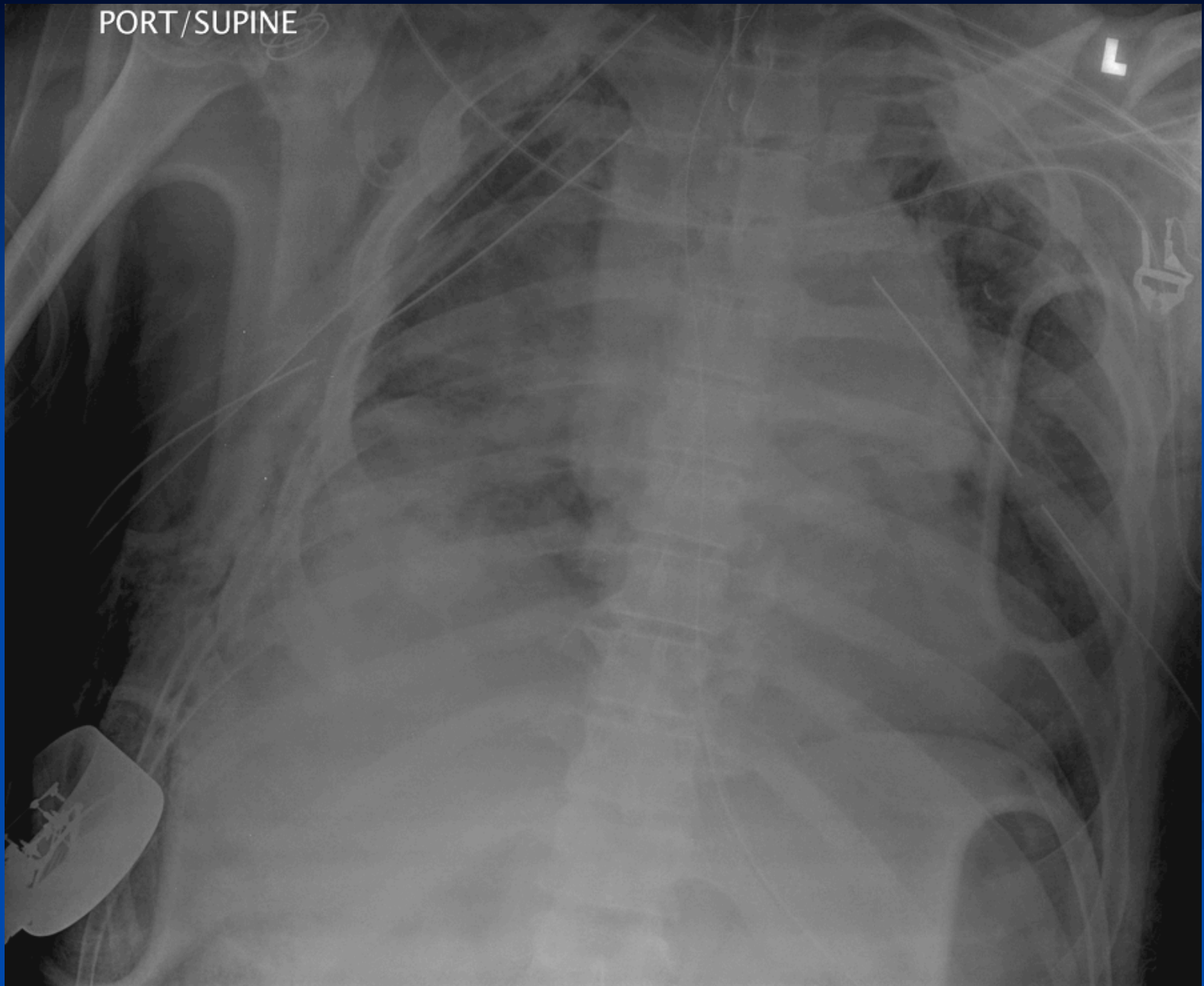
LPO

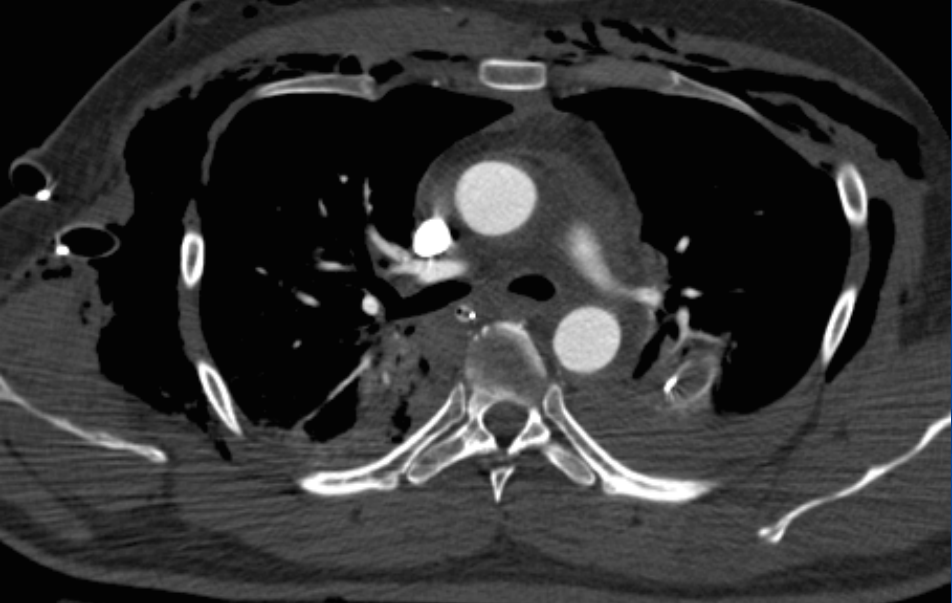
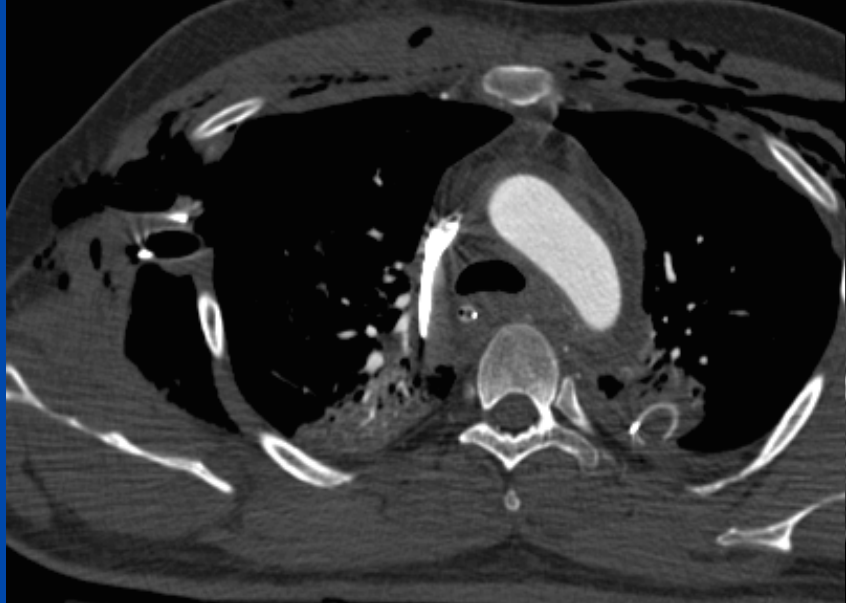
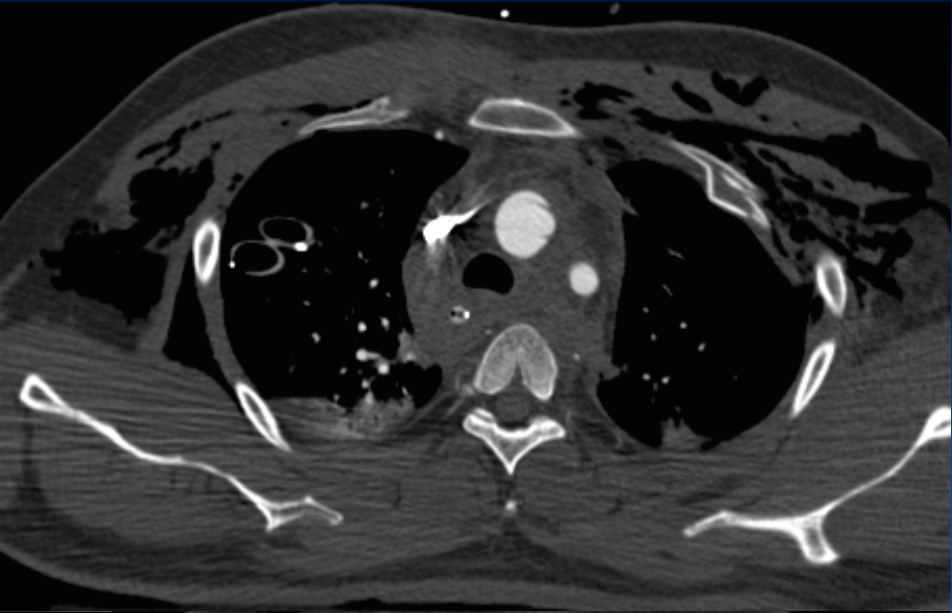
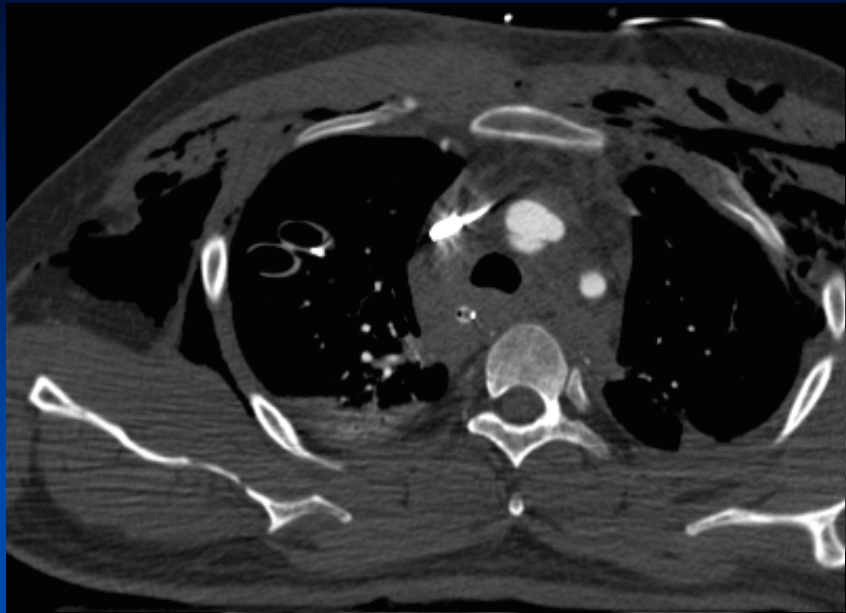




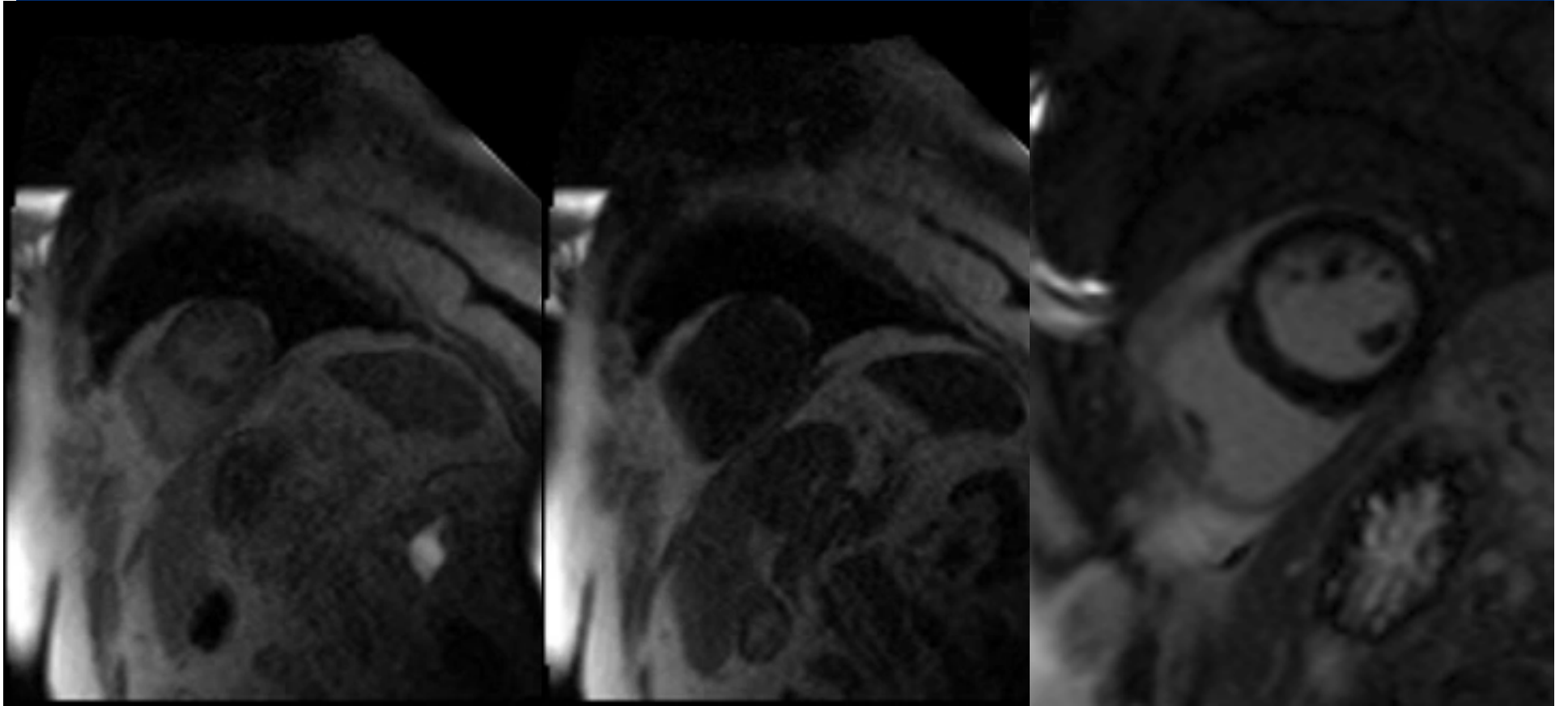
Chest

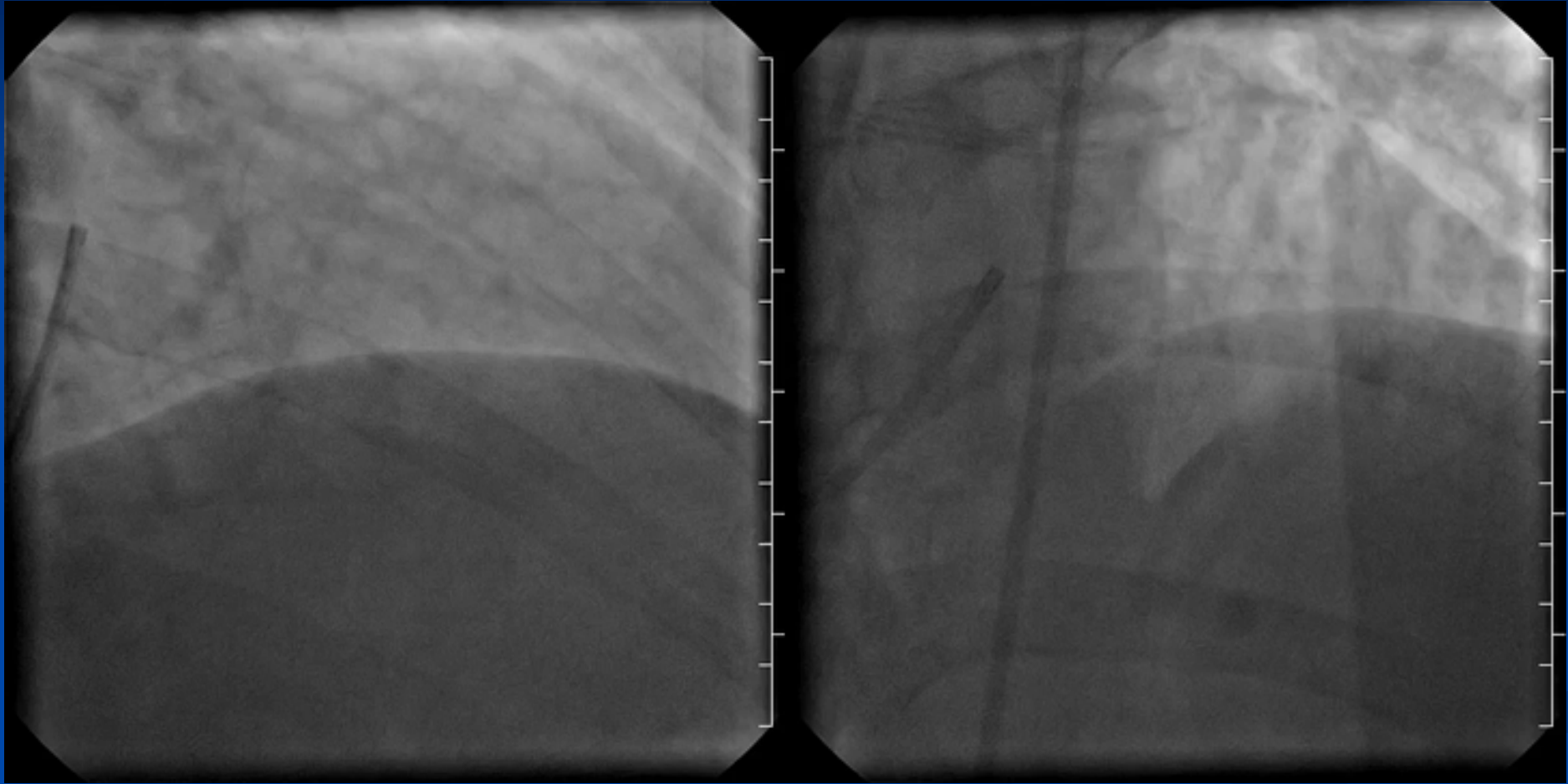
PORT/SUPINE



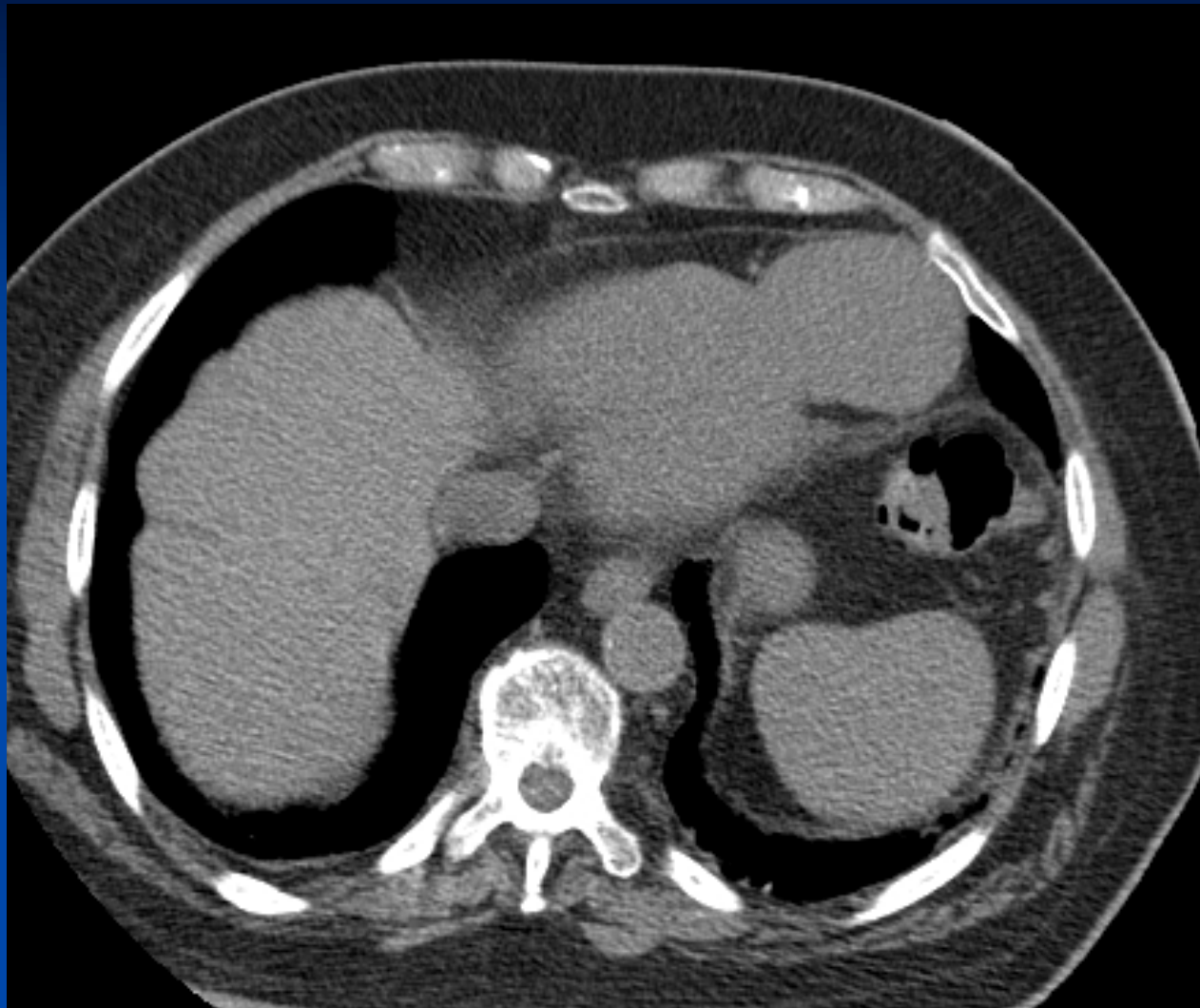


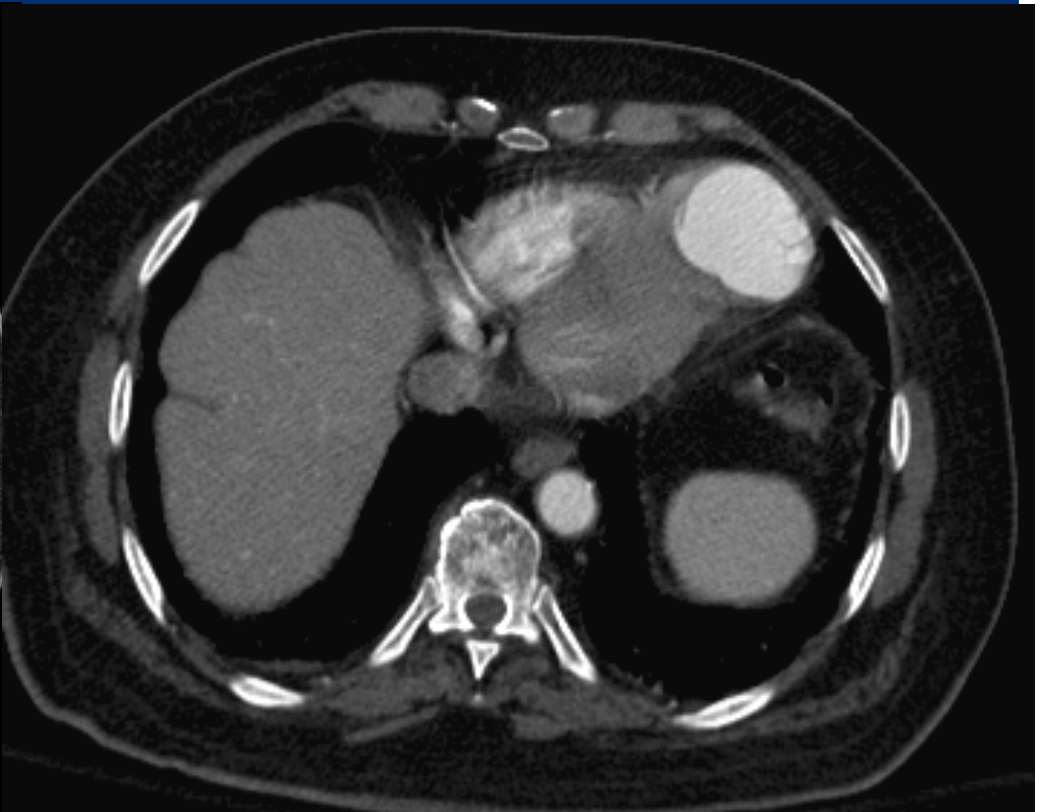
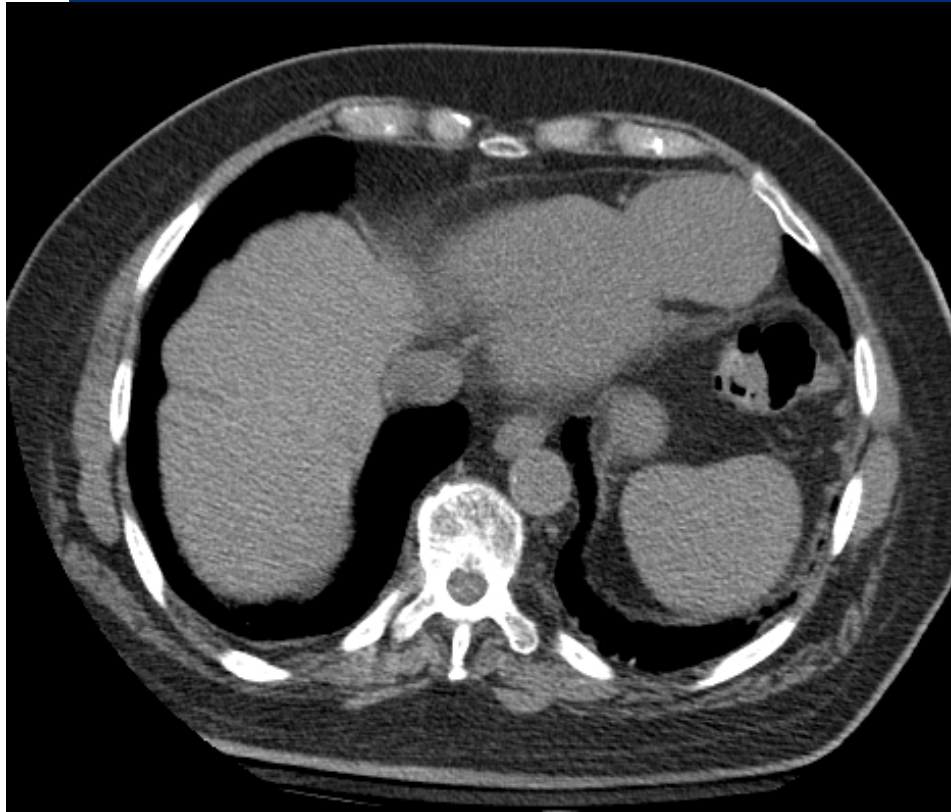
Chest





Chest





LV aneurysm and MI

I] ANATOMIC (little functional effect)

i) True aneurysm

- protrudes during both diastole & systole
- has a mouth that is \geq maximal diameter of aneurysm
- aneurysm wall was originally part of ventricular wall
- composed of fibrous tissue \pm residual myocardial cells
- may contain thrombus
- never ruptures once healed

ii) False aneurysm

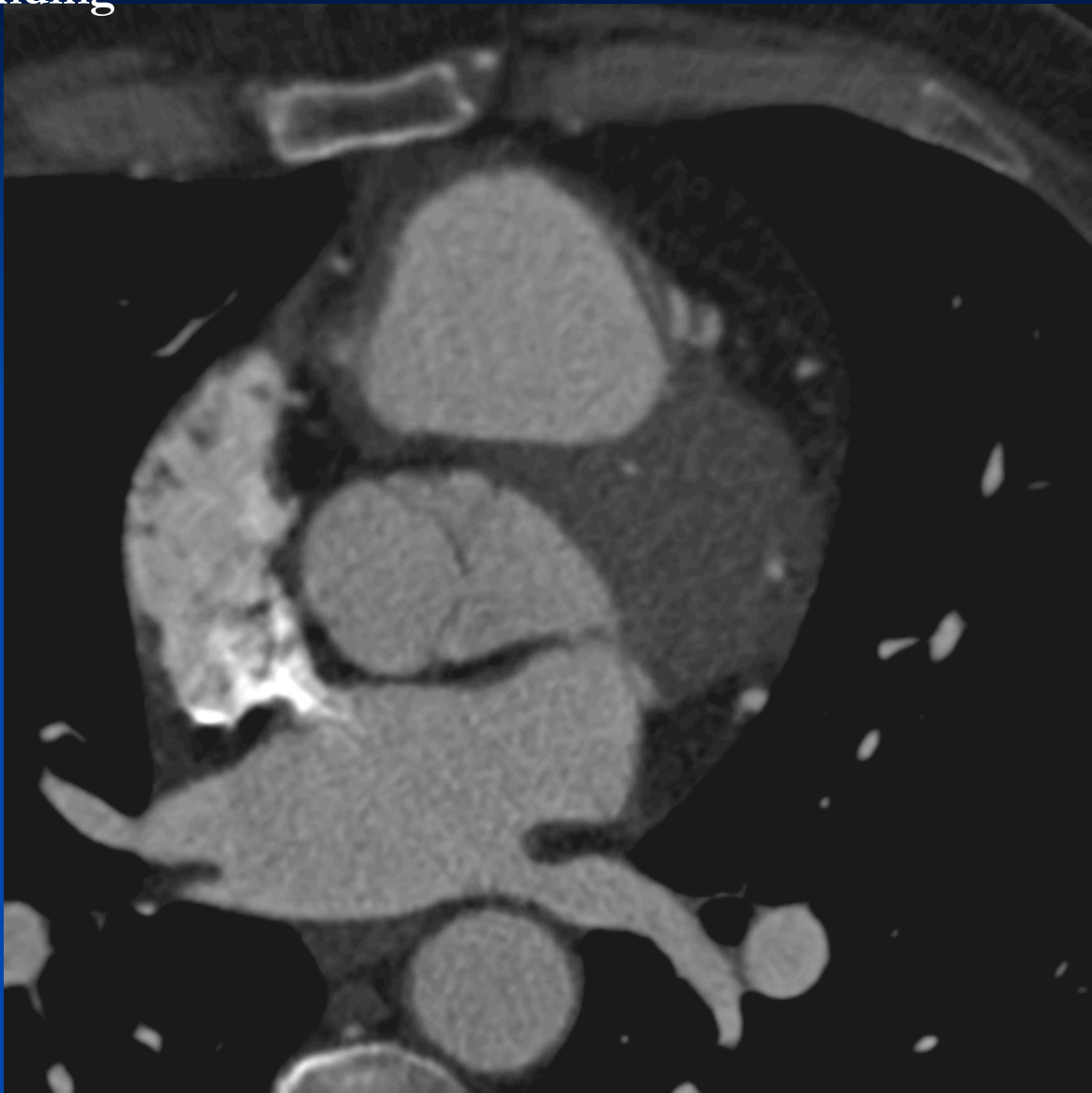
- protrudes during both diastole & systole
- has a mouth that is $<$ maximal diameter of aneurysm
- aneurysm wall is composed of parietal pericardium and thrombus
- almost always contain thrombus [source of emboli]
- often ruptures
- represents a myocardial rupture site

II] FUNCTIONAL

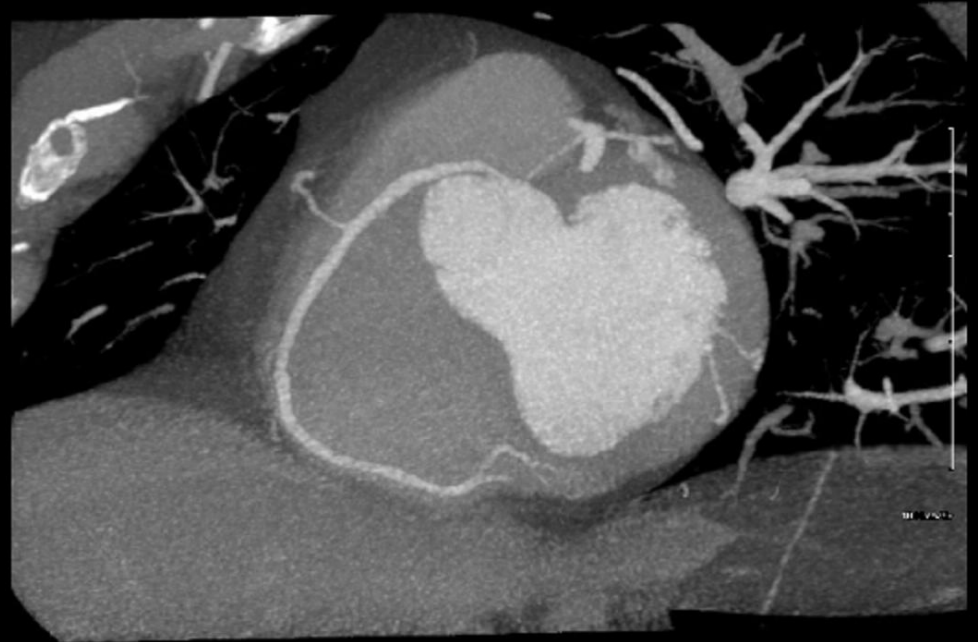
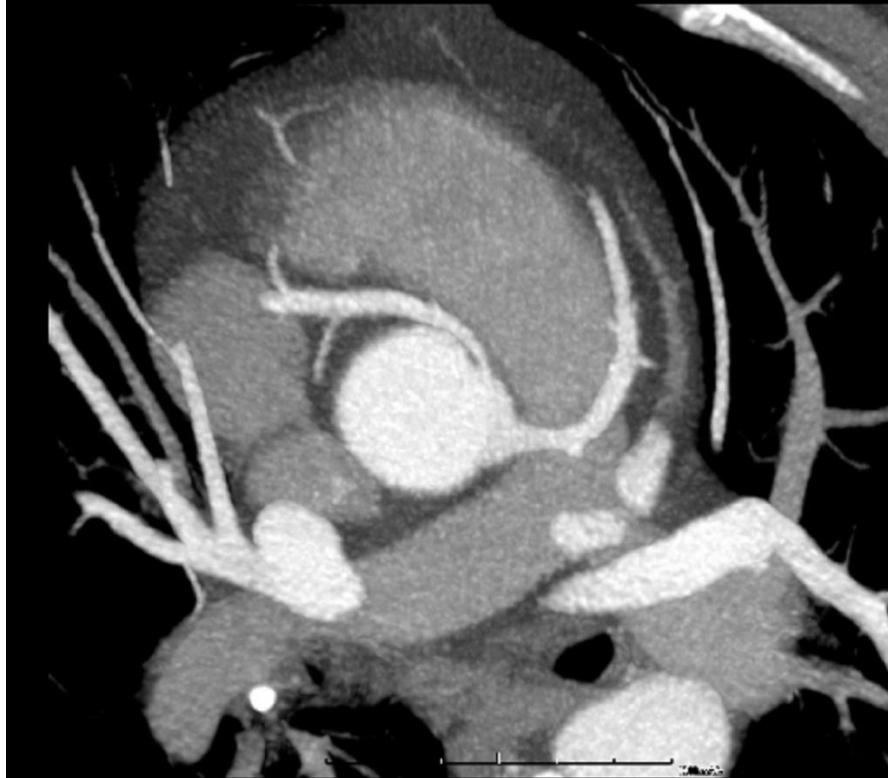i) Functional left ventricular aneurysm

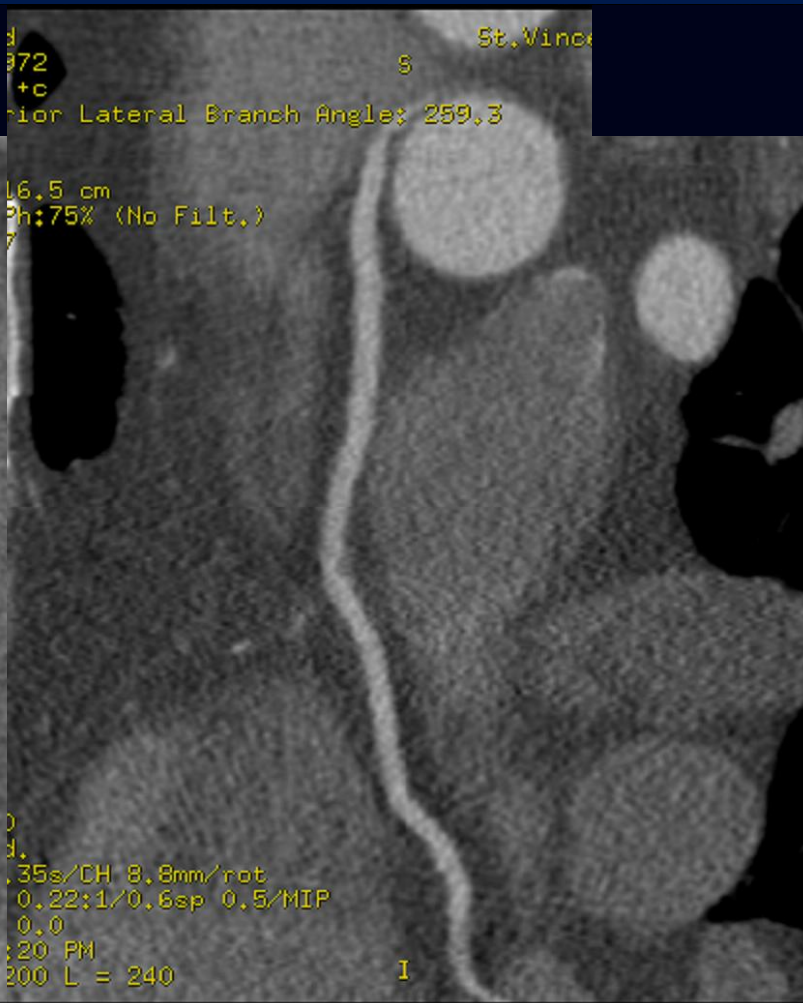
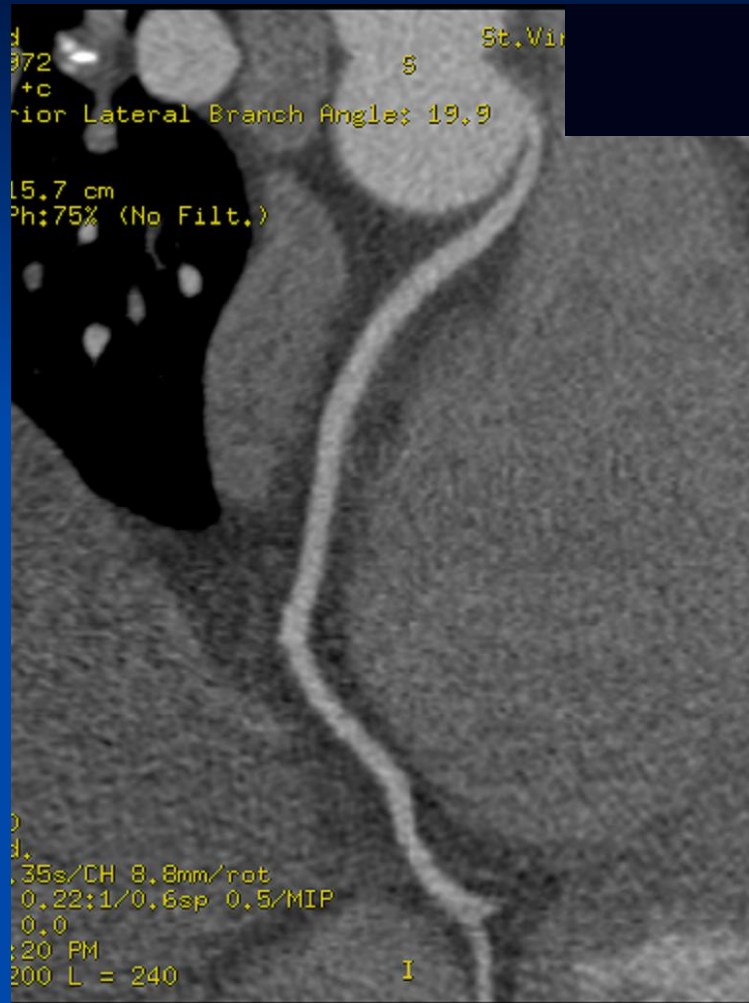- protrudes during systole but not during diastole
- composed of fibrous tissue \pm residual myocardial cells

Incidental finding

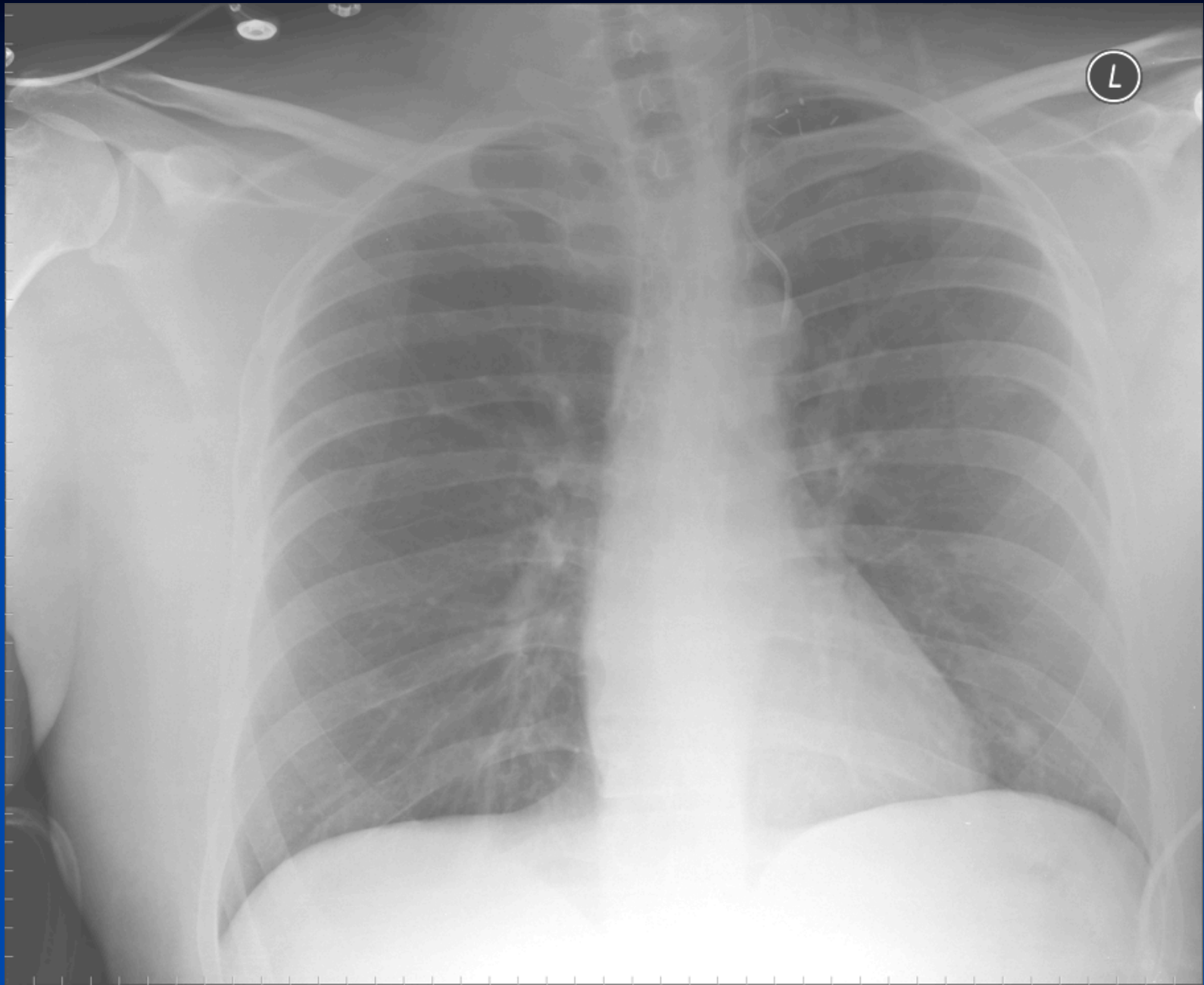


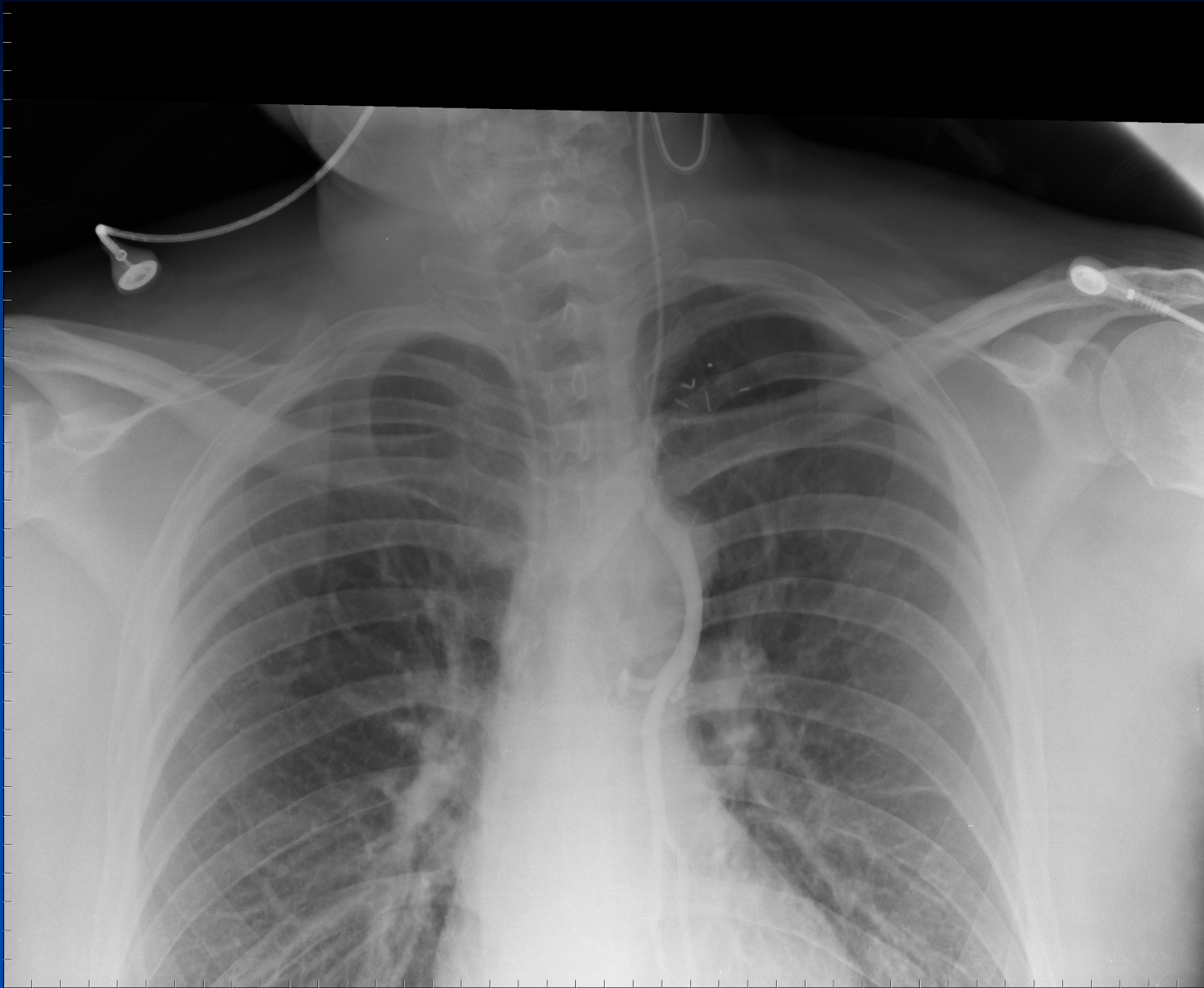CHEST



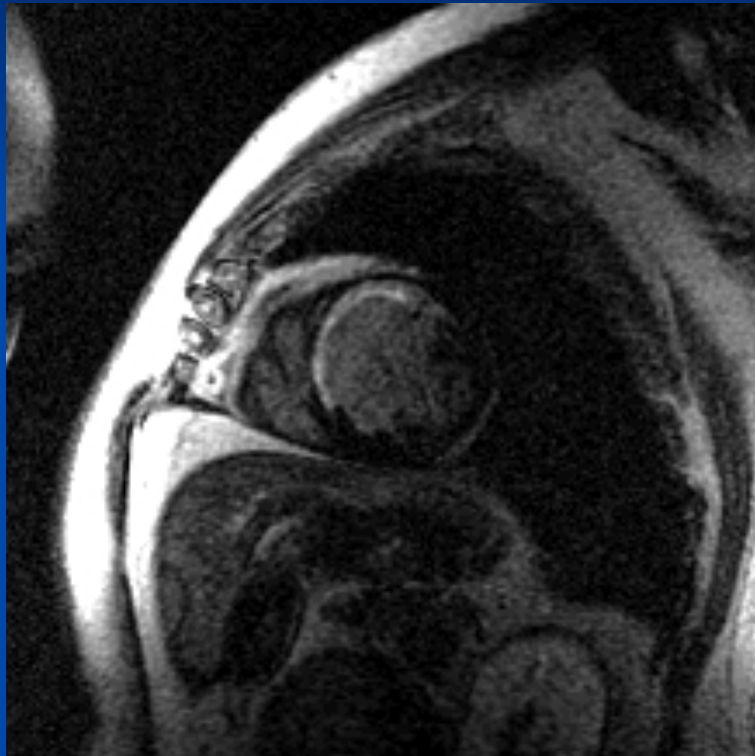


CHEST

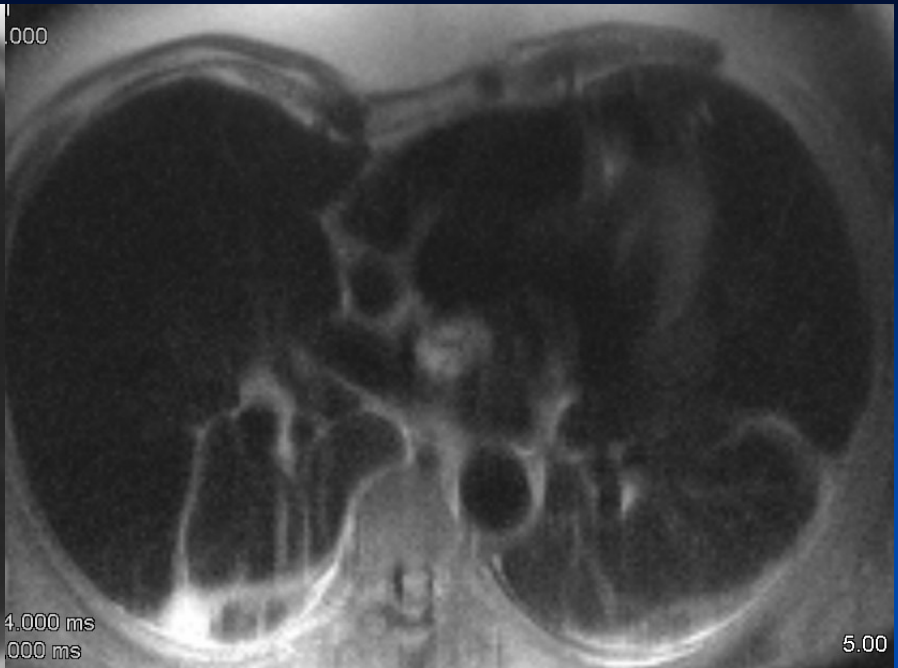
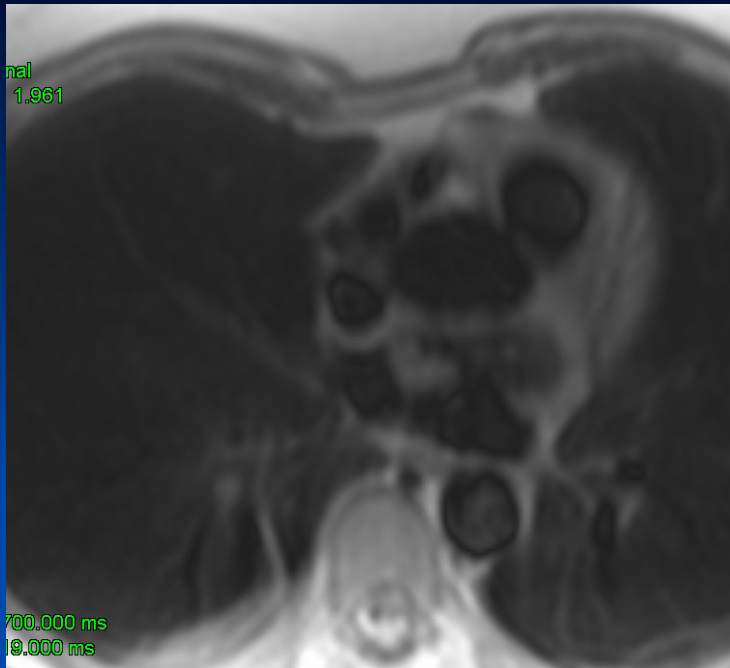




Chest



Chest

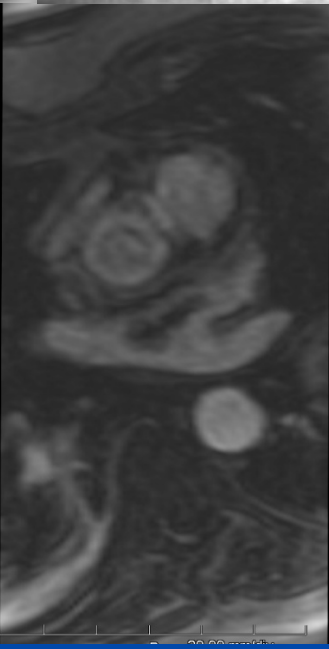

P: 105458
S: 1 Se: 19
005/08/24
0:51:22

R
aySum
ag: 1.340

R: 4.690 ms
E: 1.580 ms

ickness: 1.800 mm



Symphon
MRC2274
Rows: 102
Cols: 102

Slab: 2.00 mm

20.00 mm/div

F

