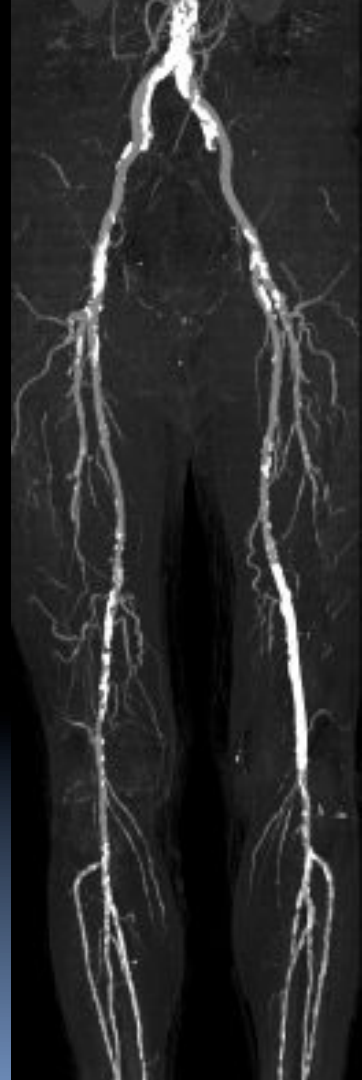

Richard L. Hallett, MD

Chief, Cardiovascular Imaging
Northwest Radiology Network
Indianapolis, IN

Adjunct Assistant Professor – Radiology
Stanford University
Stanford, CA

PERIPHERAL CTA



Outline

- CTA Acquisition Techniques
 - Scan Acquisition
 - Contrast Medium injection
 - Reconstruction
- Clinical Efficacy in PAD
- Cost Effectiveness

CTA Indications in PAD

- Intermittent Claudication
- Critical Limb Ischemia
- Acute Ischemia (urgent)
- Monitoring of Therapy (complications)

CTA Benefits / Limitations

- Non-invasive (DSA)
- Spatial Resolution (MRA)
- Quick Acquisition
- (mostly) Operator Independent
- Ionizing Radiation
- Nephrotoxic Contrast
- Spatial Resolution (DSA)
- No same session Tx
- No flow or pressure measurements

CTA Acquisition

- ✦ Scan Acquisition
- ✦ Contrast Medium Injection

CTA Scan Acquisition

Peripheral CTA Scan Acquisition / Recon

Scanning Range 1

celiac artery (~T12) → toes
(105 – 130 cm)

Optional Scanning Range 2

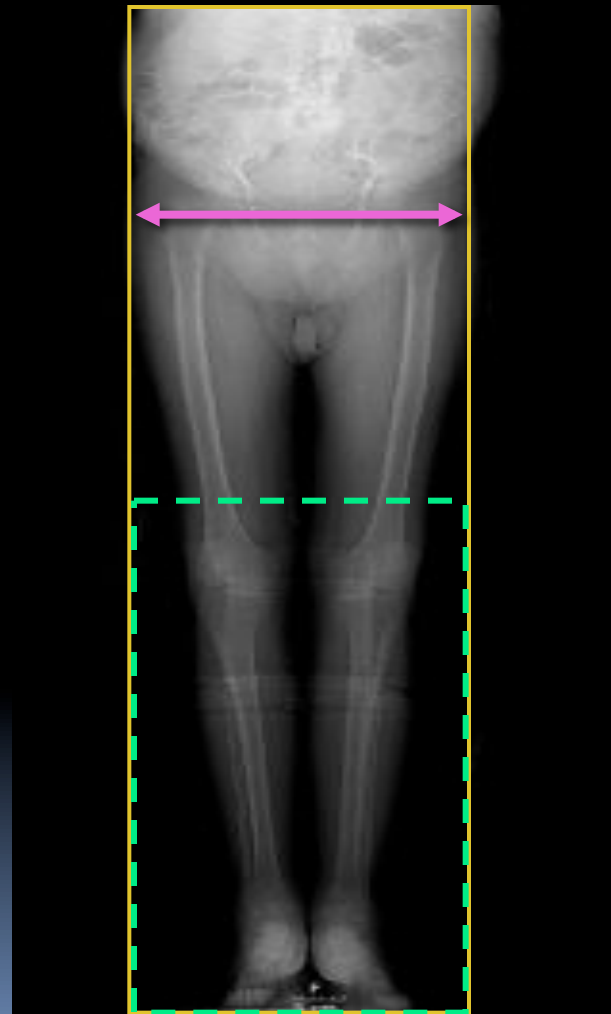
above the knees → toes

Always pre-programmed, but only initiated by RT if no contrast in pedal vessels

Recons:

Thin, overlapped

FOV = greater trochanters



Detector Configuration (mm)

TI / 360° (mm)

Table Speed (mm/s)

Scanning Time (s)

Anatomic coverage: 105 – 130cm

16-Channel MDCT

16x.75	18	36	30-40
16x.63	18	35	30-40
16x1.5	33	66	15-20
16x1.25	35	70	15-20

slow

~35 mm/s

slow

fast

~65 mm/s

fast

64-Channel MDCT

64x.63	55	92	11-14
64x.60	29	78	13-17

very

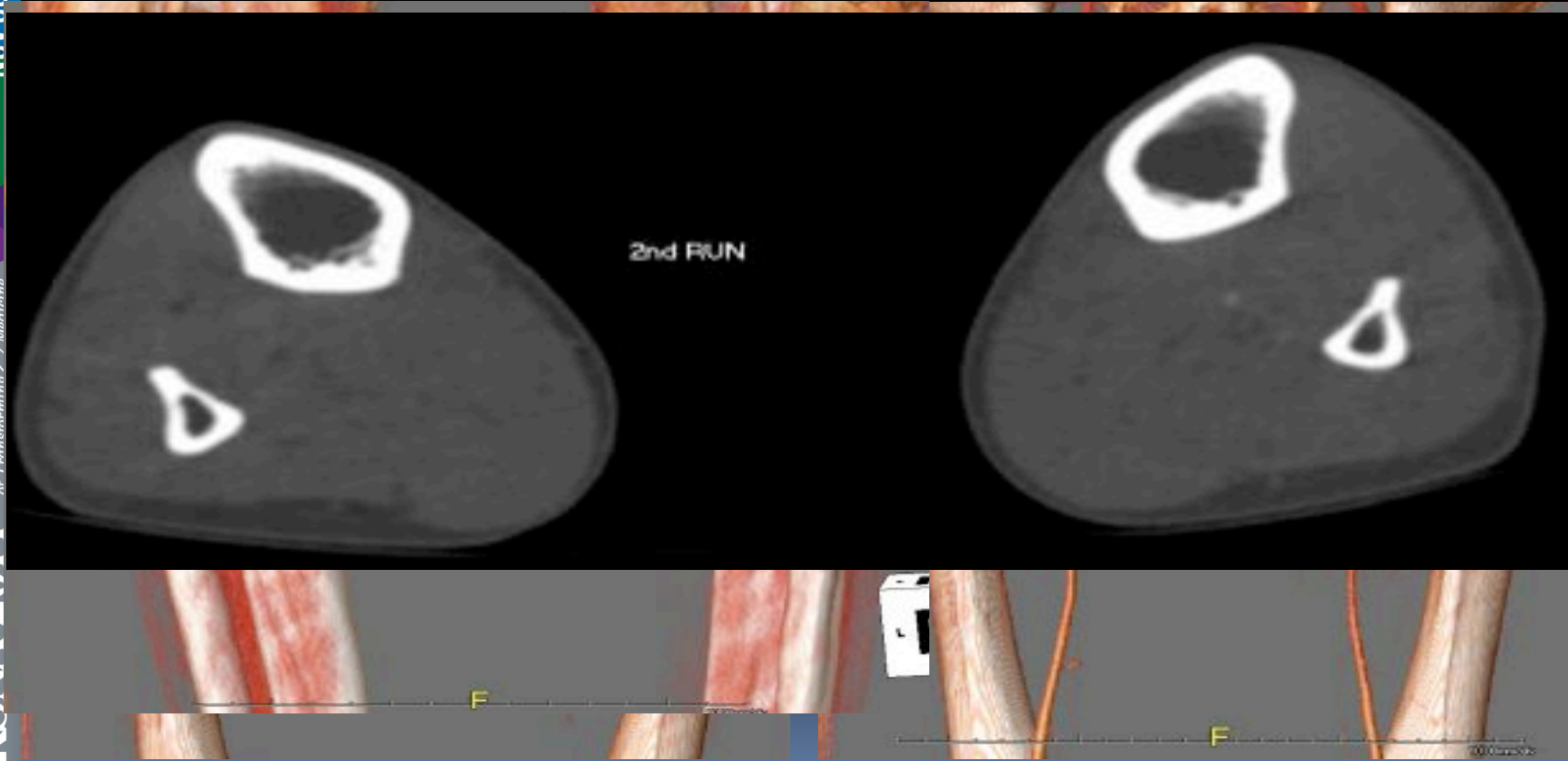~85 mm/s

fast

Speed considerations for ≥ 64 slice CTA

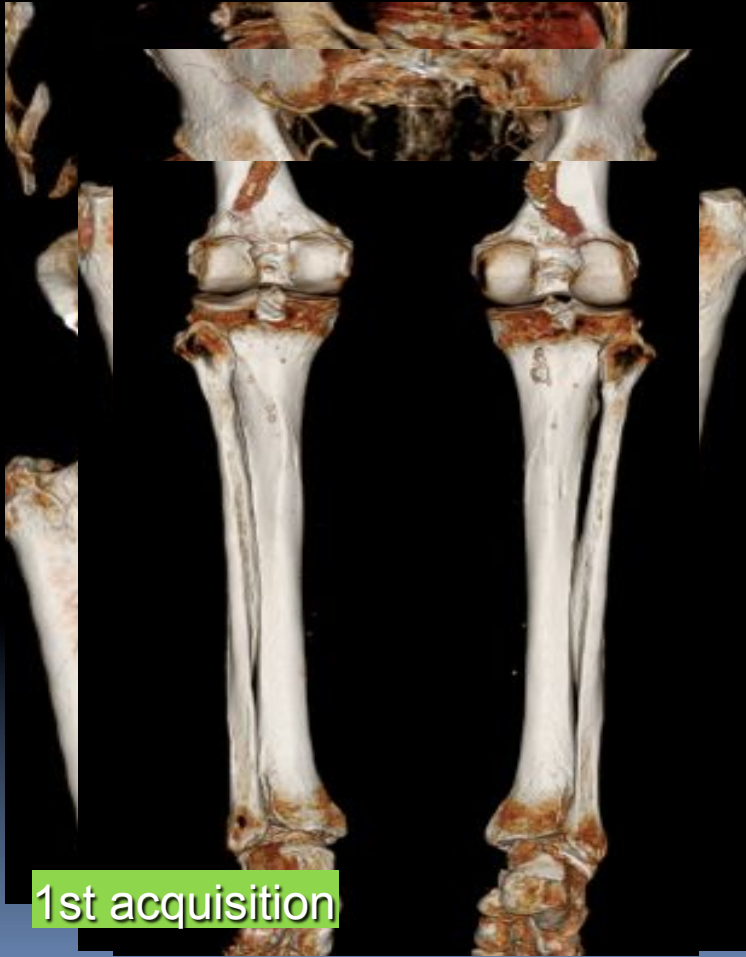
- Outrunning Bolus
- Delayed filling of distal arteries

Free-Flap Planning CTA

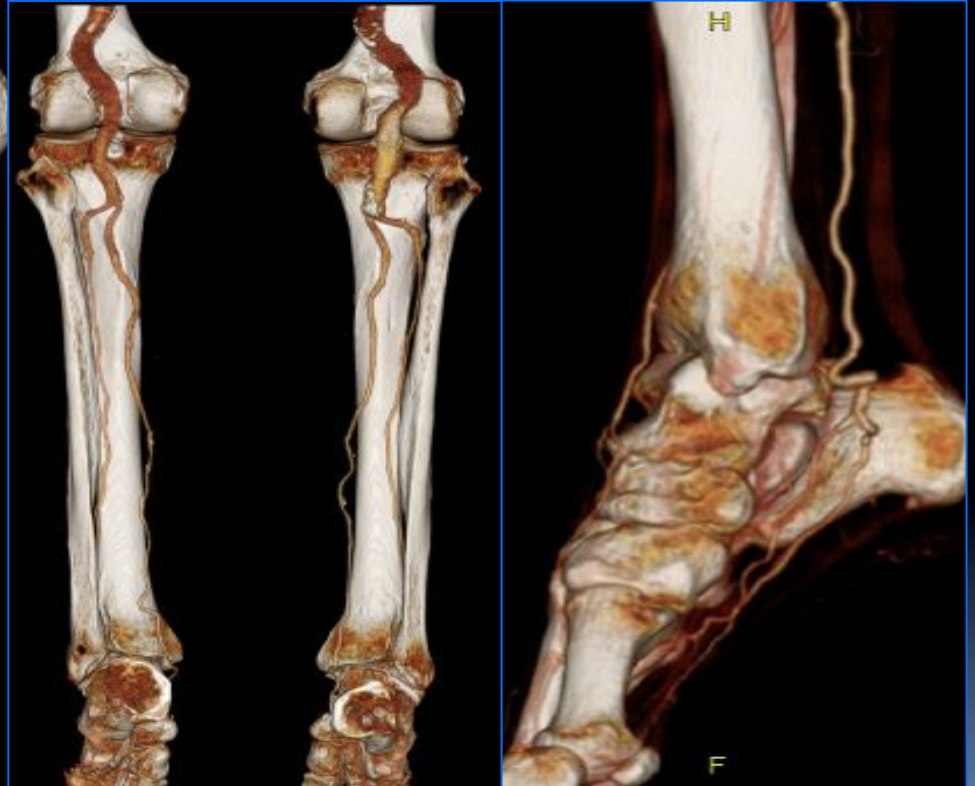


Arteriomegaly

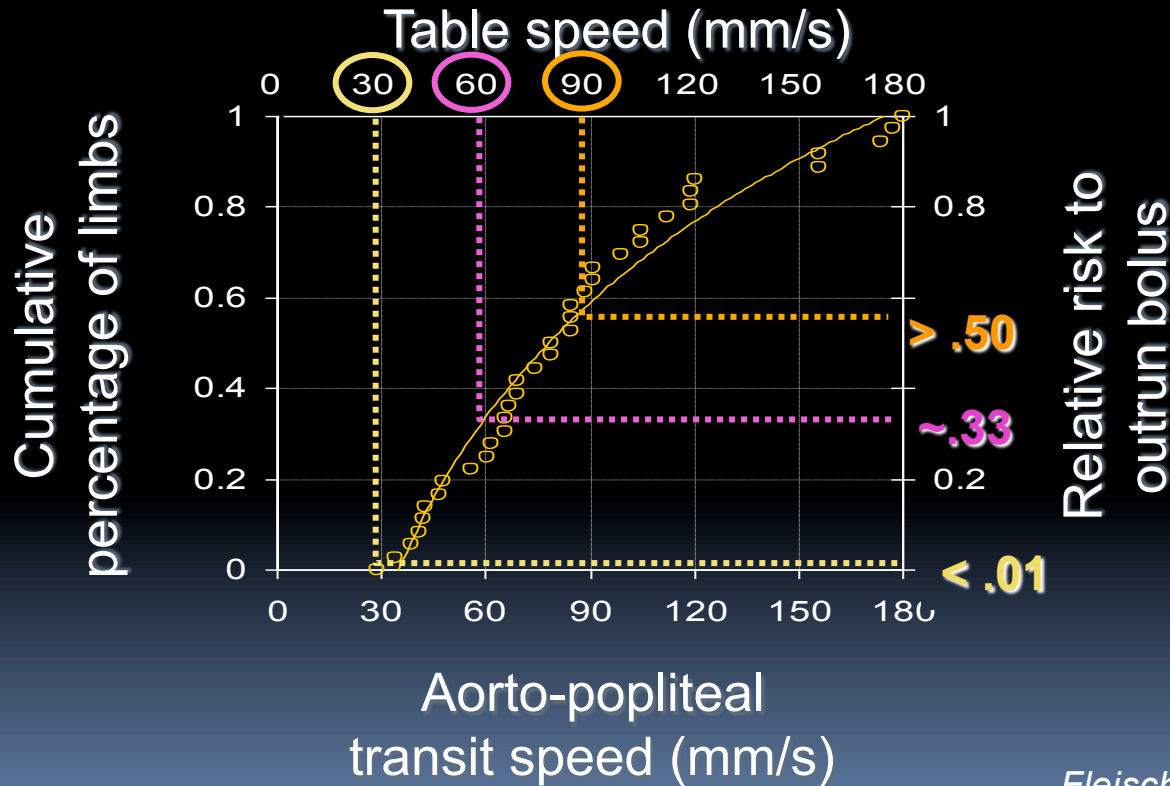
preprogrammed,
optional 2nd acquisition



1st acquisition

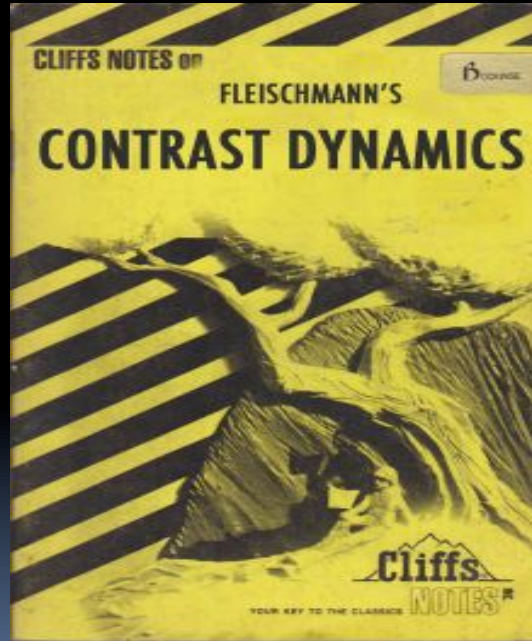


Peripheral arterial bolus propagation



Fleischmann D and Rubin GD.
 Radiology 2005, 1076-1082

Contrast Administration for peripheral CTA



Fleischmann D. How to design injection protocols for multiple detector-row CT angiography (MDCTA). Eur Radiol. 2005 Dec 1;15 Suppl 5:E60–5.

Contrast considerations for peripheral CTA

- Aorto-popliteal transit time: 4-24 sec (10 sec)
 - Contrast speed: 29-177 mm/s
- Biphasic injections yield more consistent enhancement profile

Biphasic Injection for Peripheral CTA

Fleischmann D. Eur. J. Radiol. 2003 Mar 1;45 Suppl 1:S88-93.

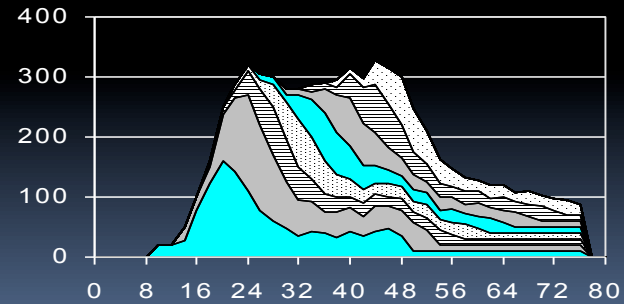
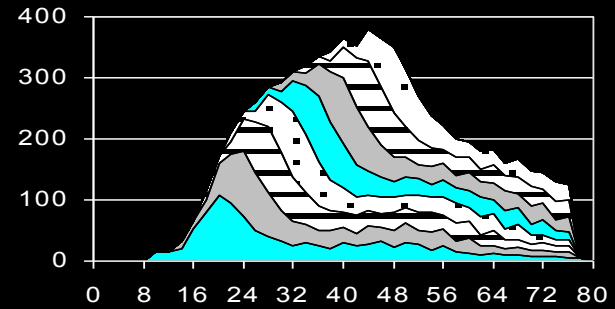
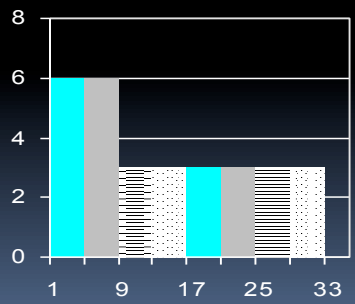
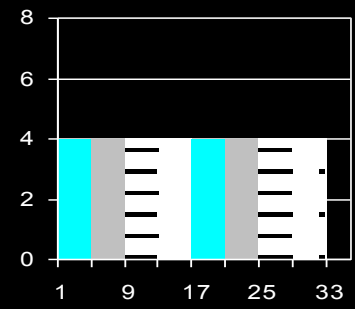
INPUT

intravenous injection rate (mL/s)

Biphasic Injection

Phase I (surge phase)

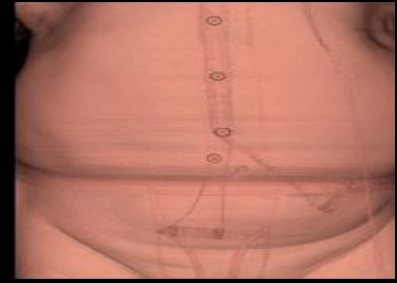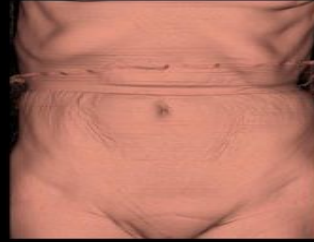
Phase II (continuing phase)



OUTPUT

arterial enhancement (Δ HU)

Patient Factors



- Arterial enhancement is inversely related to:
 - Cardiac output (CO)
 - Central blood volume (CBV) } usually unknown
 - CO (and CBV) correlate with body weight
 - at least in pts. with ~ normal cardiac function
 - Weight-based dosing helps consistency

Integrated Contrast/Scan Protocol

- ★ Simple, weight based injection volumes and flow rates, combined with a fixed scan time or scan time/diagnostic delay sum.
- ★ automated bolus triggering
- ★ Use physiology not scanner speed
- ★ **BENEFITS:**
 - ★ Decrease patient to patient variability in scan quality
 - ★ Optimize imaging timing
 - ★ Image all of the contrast given!
 - ★ (Potentially) save contrast

STANFORD Integrated Scanning-Injection Protocol: (Siemens)

- Scan time: 40s for ALL patients (pitch variable)
- Inj.duration: 35s for ALL patients
- Delay: bolus triggering

weight

Biphasic Injection

<55kg

20 mL (4.0mL/s) + 96 mL (3.2mL/s)

<65kg

23 mL (4.5mL/s) + 108 mL (3.6mL/s)

75kg

25 mL (5.0mL/s) + 120 mL (4.0mL/s)

>85kg

28 mL (5.5mL/s) + 132 mL (4.4mL/s)

>95kg

30 mL (6.0mL/s) + 144 mL (4.8mL/s)

ST. VINCENT Integrated Scanning-Injection Protocol: (GE HD-750, VCT)

- Scan time: Variable (can't specify time)
- Add “diagnostic delay” to make 40 sec
- Inj.duration: 35s for ALL patients
- Delay: bolus triggering

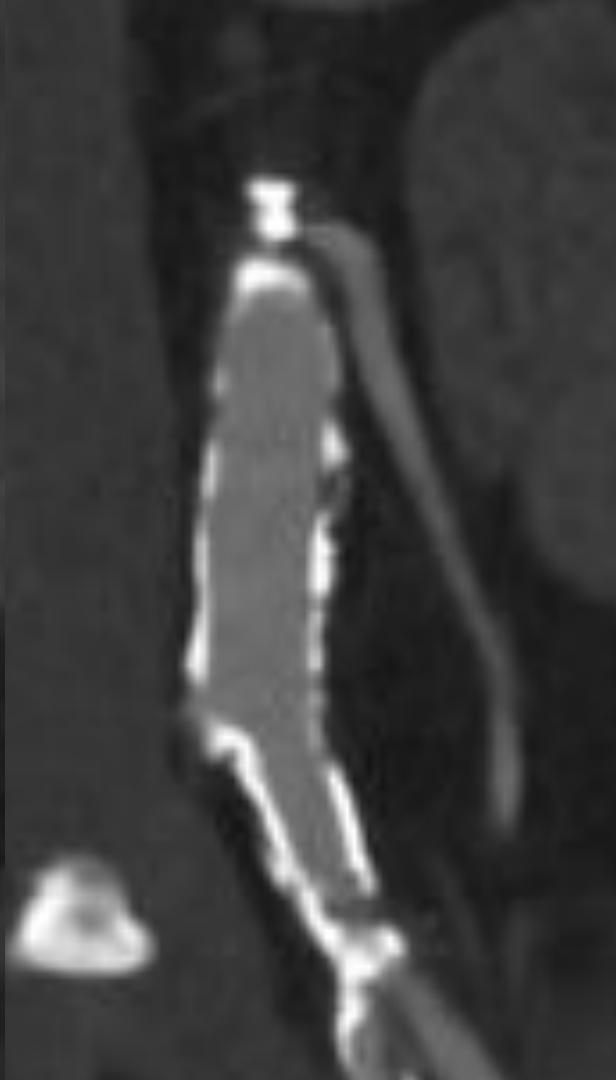
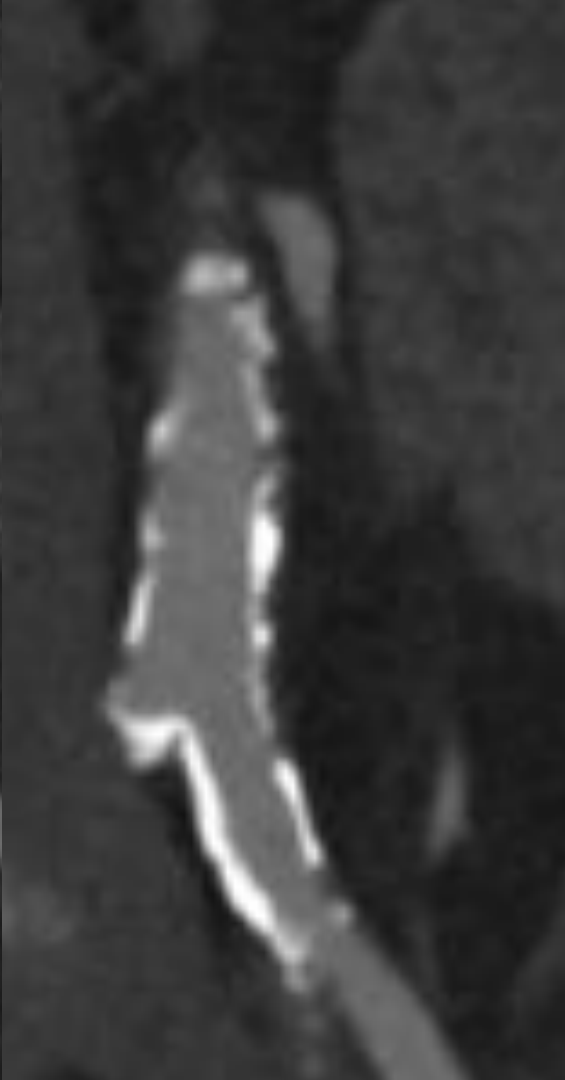
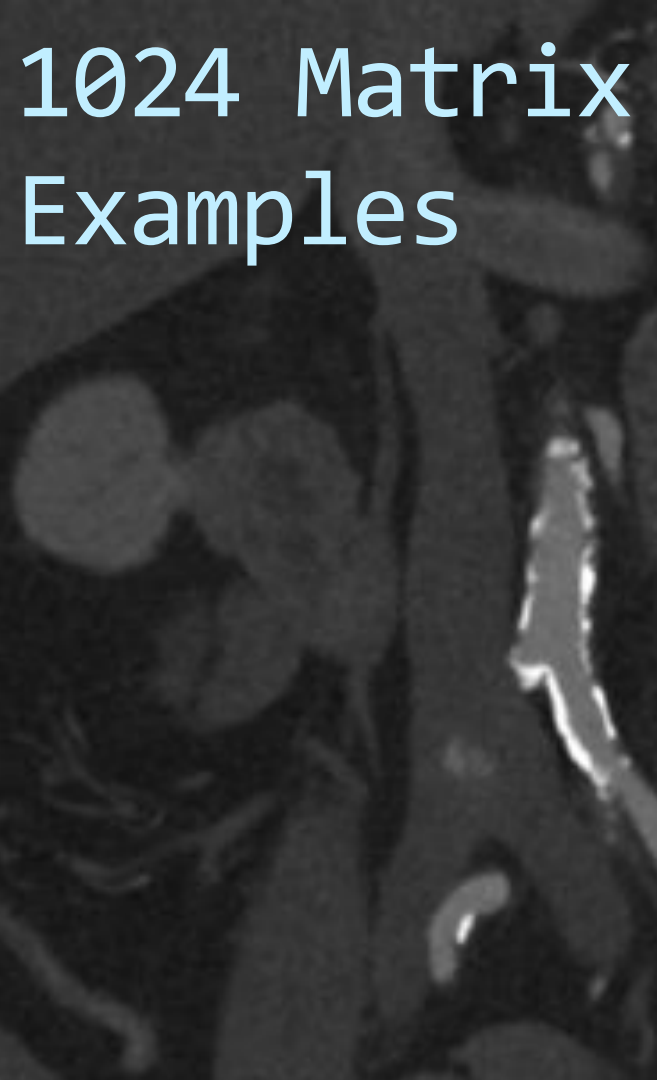
<u>weight</u>	<u>Biphasic Injection</u>
<55 kg	20 mL (4.0mL/s) + 96 mL (3.2mL/s)
55–95 kg	25 mL (5.0mL/s) + 120 mL (4.0mL/s)
>95 kg	30 mL (6.0mL/s) + 144 mL (4.8mL/s)

CTA Reconstruction

CTA Reconstruction and Interpretation

- Use Iterative Reconstruction
- **Recon** thin, overlapping images and **review in 3D**
 - VR / MIP overview then MPR, CPR
 - 3 -5 mm Axials in A/P
- **Recon larger matrix – 1024x1024**

1024 Matrix Examples



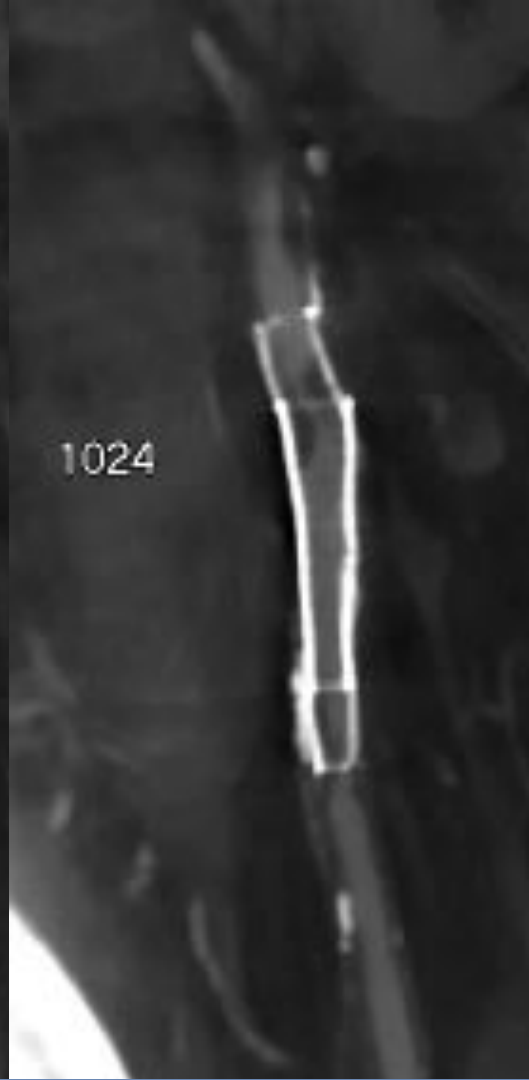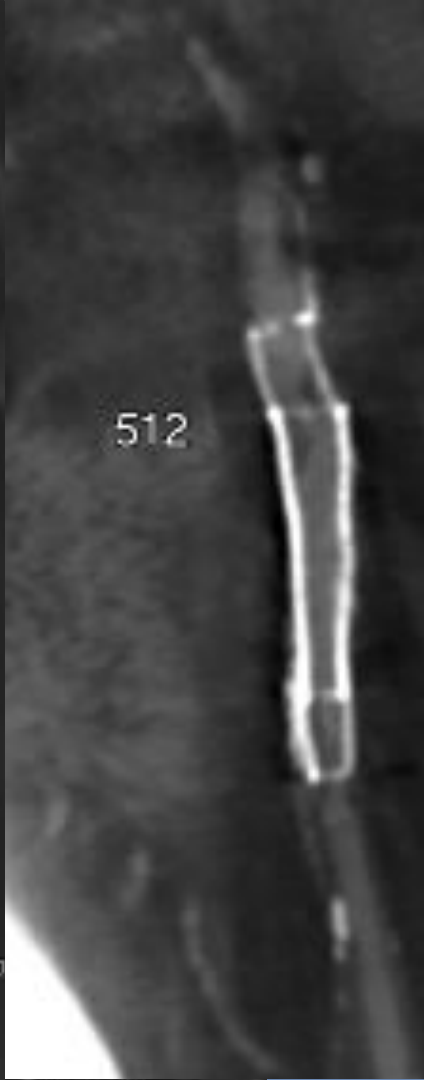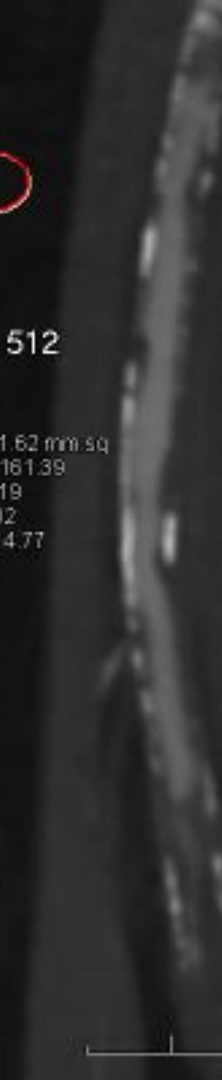512

Area: 51.62 mm²
Mean: -161.39
Max: -119
Min: -202
SDev: 14.77

1024

512

1024



Efficacy of LE CTA in PAD

PAD Classification

Fontaine Stage		Rutherford Classification	
I.C.	I	Asymptomatic	0
	IIa	Mild Claudication (>200m walk)	1
	IIb	Moderate to Severe Claudication (<200m walk)	2 (moderate) 3 (severe)
CLI	III	Ischemic Rest Pain	4
	IV	Ulceration or Gangrene	5 (minor tissue loss) 6 (major tissue loss)

CTA: Diagnostic Performance vs. DSA

Performance

CT Channels	Sens (95% CI)	Spec (95% CI)
2-4	92 (88-96)	98 (95-99)
16-64	97 (95-98)	98 (96-99)

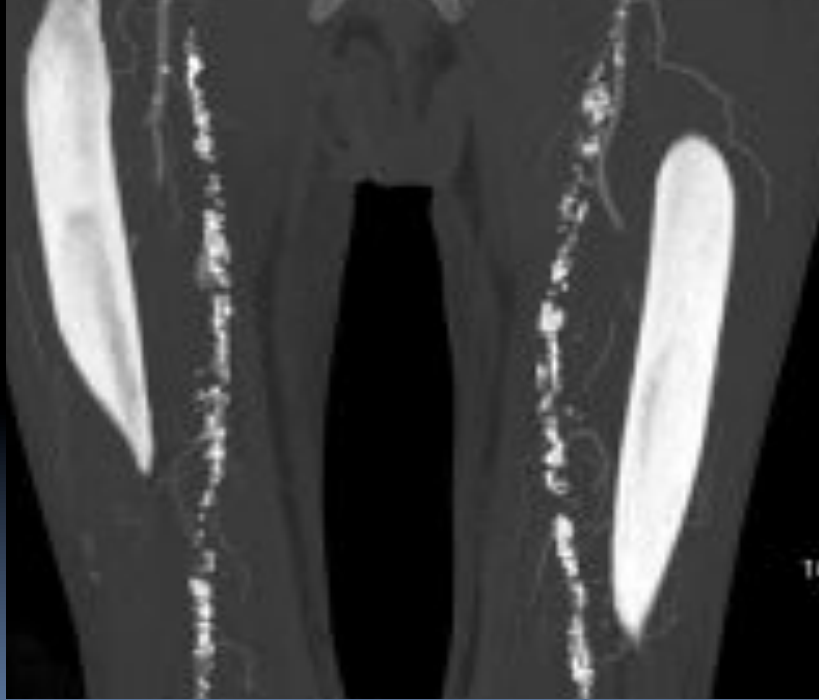
Detection of $\geq 50\%$
Stenosis or Occlusion
By Anatomical Region

Vessels	Sens (95% CI)	Spec (95% CI)
Aortoiliac	96 (91-99)	98 (95-99)
Femoropopliteal	97 (95-99)	94 (85-99)
Trifurcation	95 (85-99)	91 (79-97)

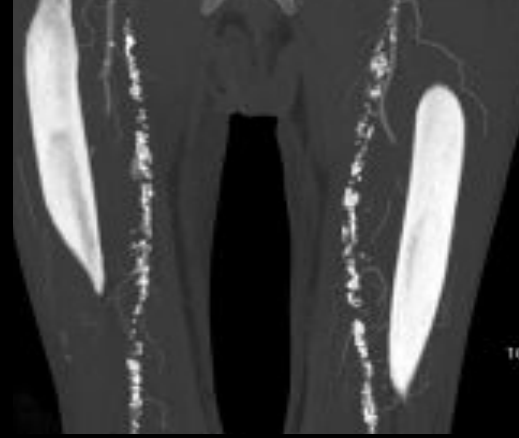
Diagnostic Performance: 64-slice CTA

- Symptomatic PAD: 242 pts, 7420 segments
- CTA and DSA performed
- For >70% stenosis:
 - SENS/SPEC 96% PPV 98% NPV 99%
 - No sig difference vs DSA findings
 - Results similar in Ca++ vs. Non-Ca++ lesions

The Achilles' Heel of Extremity CTA.....



Predictors of Vascular Calcification



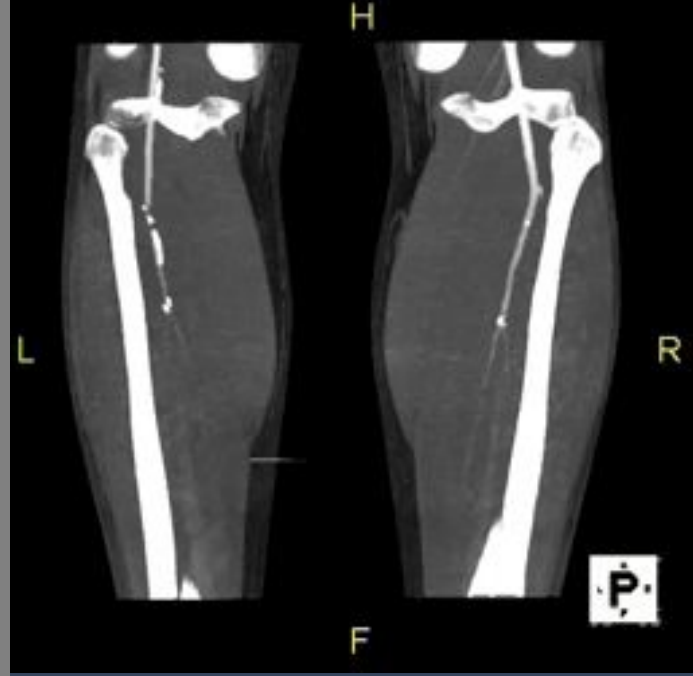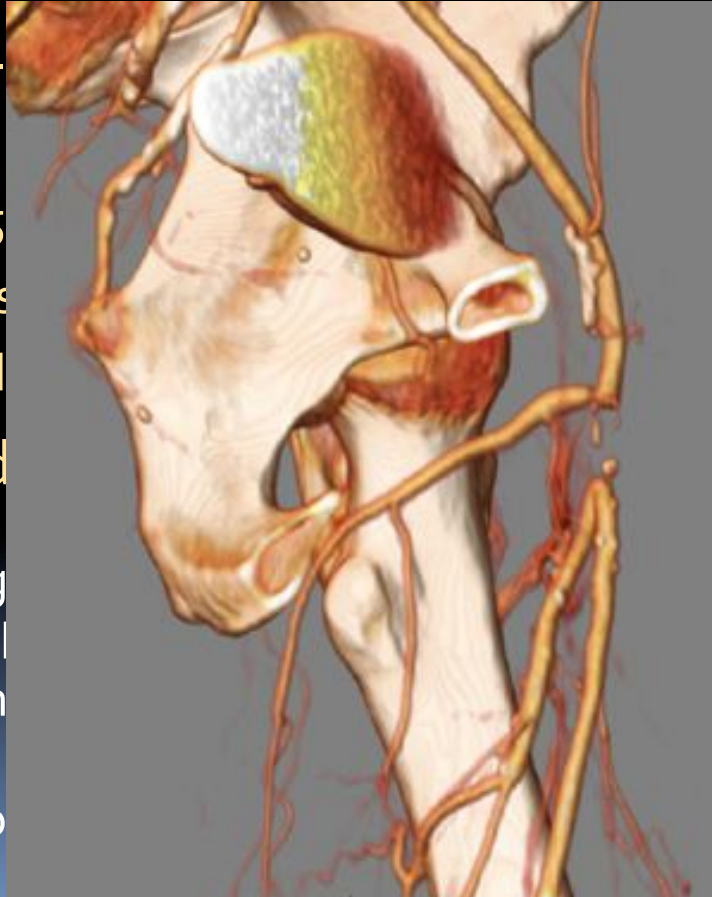- ★ Above knee:¹ Severe PAD (Fontaine III-IV), Diabetes
- ★ Below Knee:¹ Renal Failure (esp. dialysis), Diabetes
- ★ Also:² Age, cardiac disease
- ★ If heavy, significant decrease in SENS/SPEC in calf ¹

¹ Meyer BC Eur Radiol (2010) 20:497-505

² Ouwendijk R. Radiology (2006) 241, 603-608

Time-Resolved CTA - Runoff

- ★ Technique -
 - ★ timing bolus
 - ★ 50 mL at 5
 - ★ 12 low-dose
 - ★ Rapid
- ★ Then: stand
- ★ Significantly g
- ★ venous overlap
- ★ Significantly h
- ★ Directly visual
- ★ diminished flo

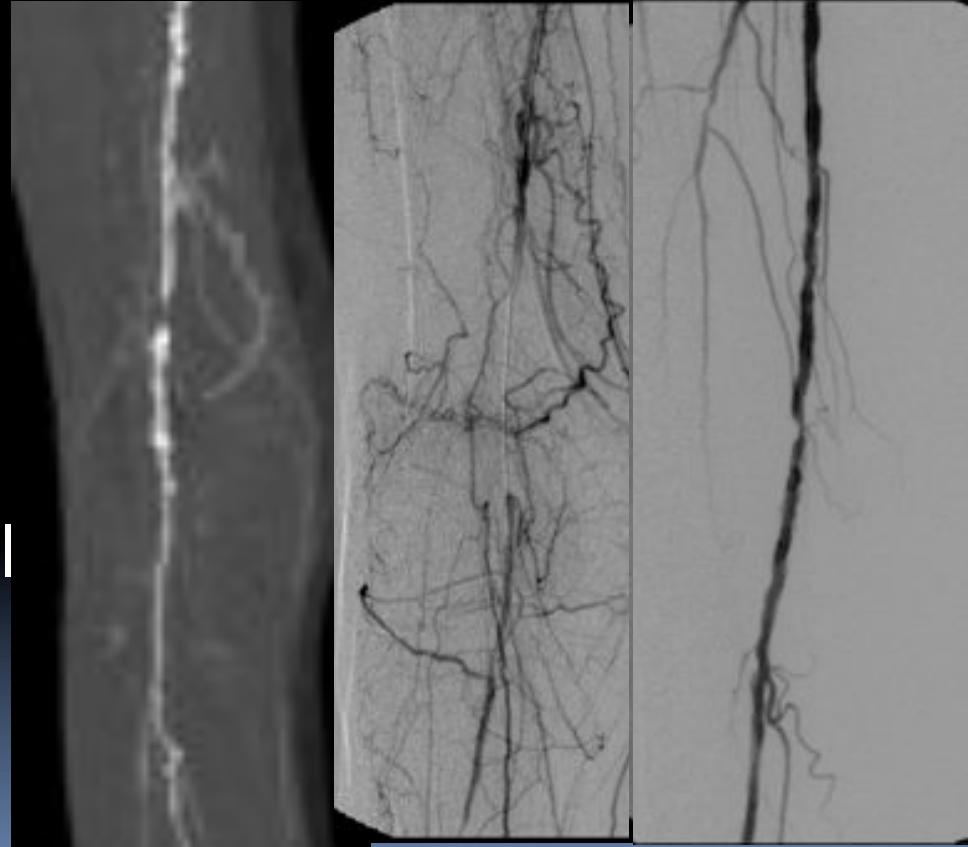


Clinical Utility of LE CTA in PAD

- Intermittent Claudication (IC)
- Critical Limb Ischemia (CLI)

Intermittant Claudication (IC)

- Only 1/4 progress clinically
- Amputation uncommon (unless diabetic)
- More likely ilio-femoral than trifurcation dz

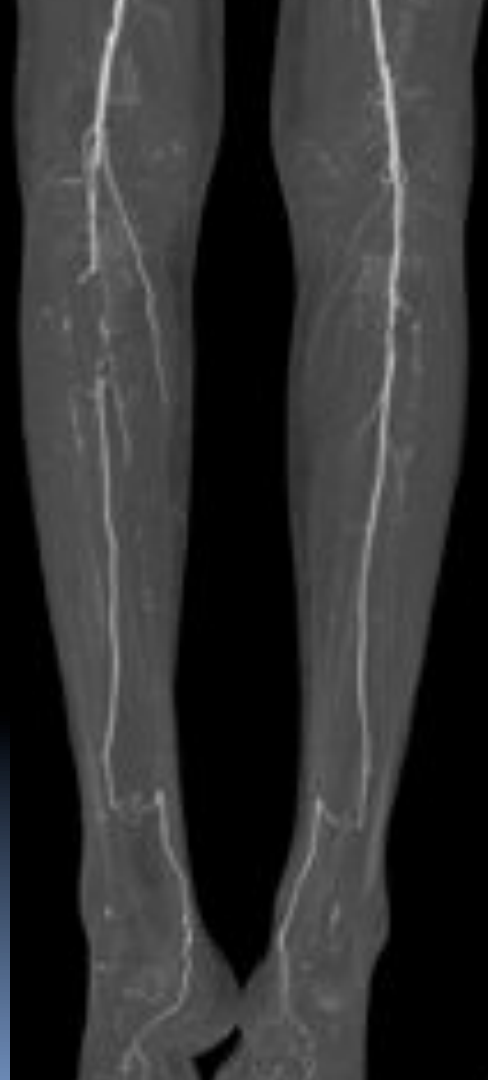

Management of Intermittent Claudication by CTA

- Fontaine IIb patients, Tx decisions by TASC II criteria
- 57/58 correct Tx decision-making by CTA
 - One CFA stenosis missed
 - 29 endovasc/surg Tx
 - 29 conservative mgmt

Critical Limb Ischemia (CLI)

- Duration > 2 weeks
- rest pain, tissue loss, ulcers, gangrene (TASC II)
 - Fontaine III / IV
- Higher incidence DM, trifurcation disease, comorbidities than IC



CTA assessment in CLI

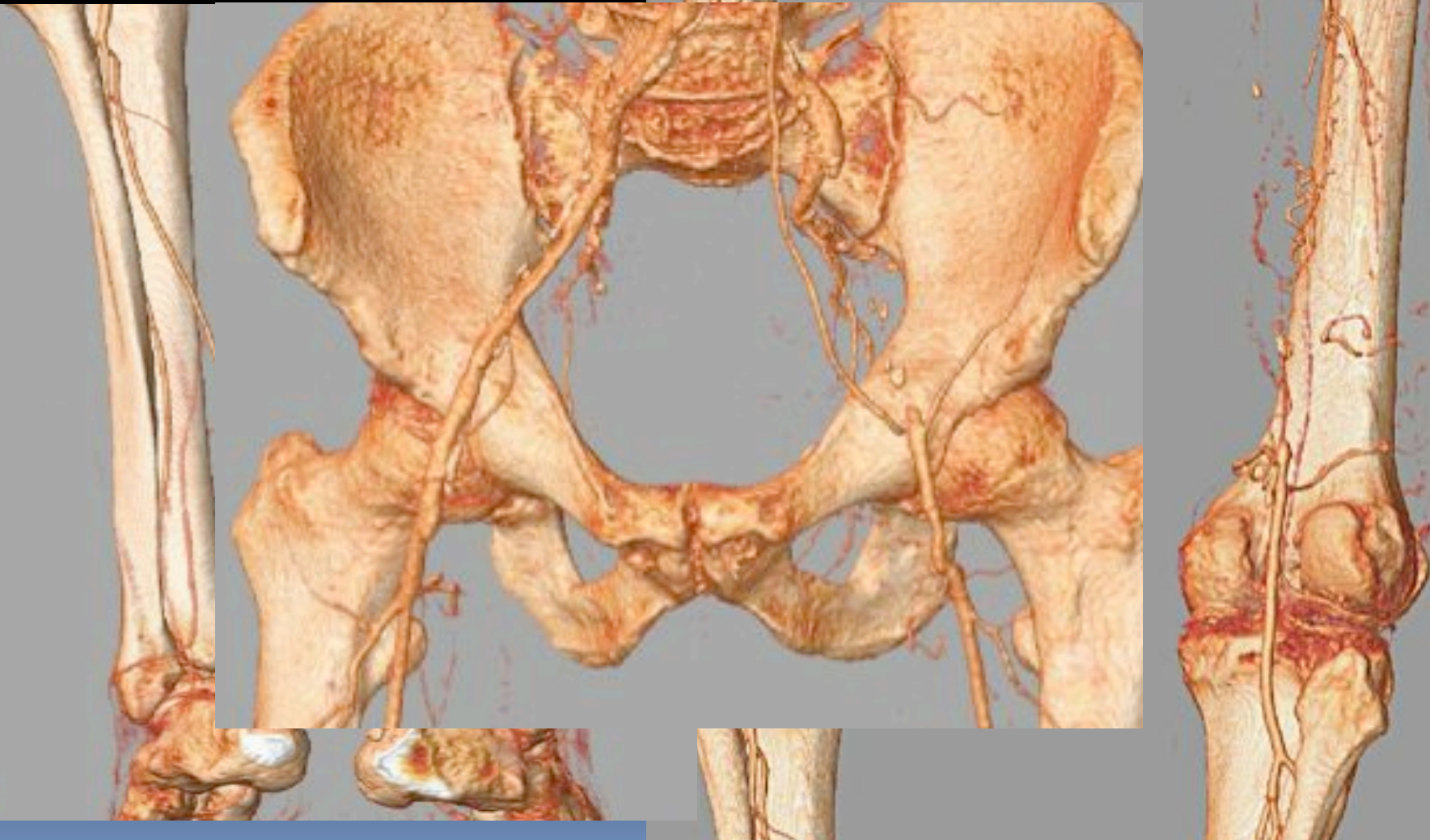- 41 pts, 1435 segments
- 64-CTA
- Fontaine IIb, III, IV
- 2.2% segments non-diagnostic
 - not included in calculation
 - 91% infrapop segments evaluable
- **For $\geq 50\%$ stenosis:**
 - **Sens 99% Spec 98% Acc: 98%**

Management Decisions in CLI

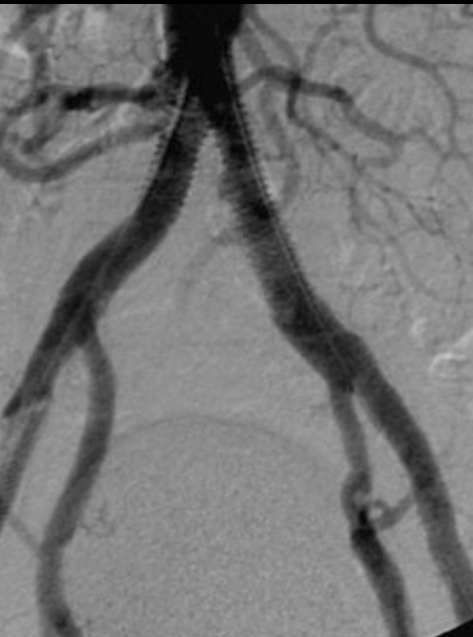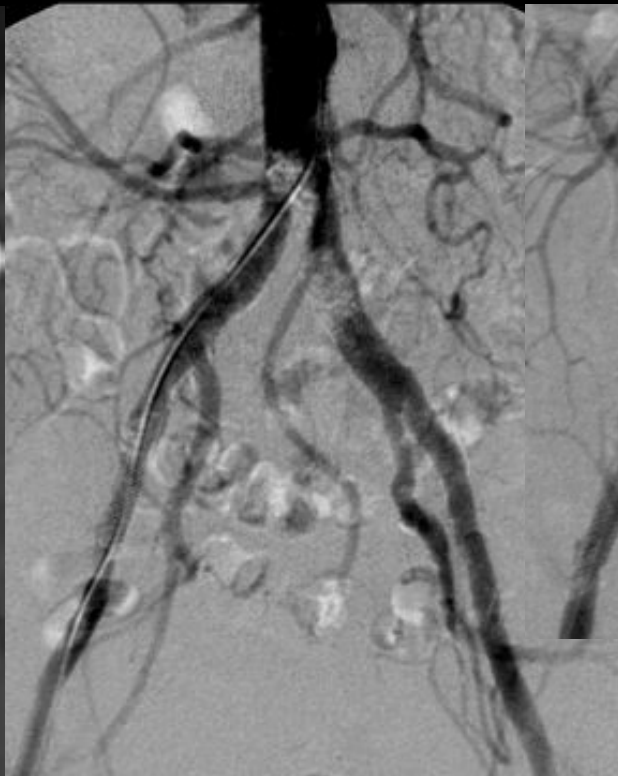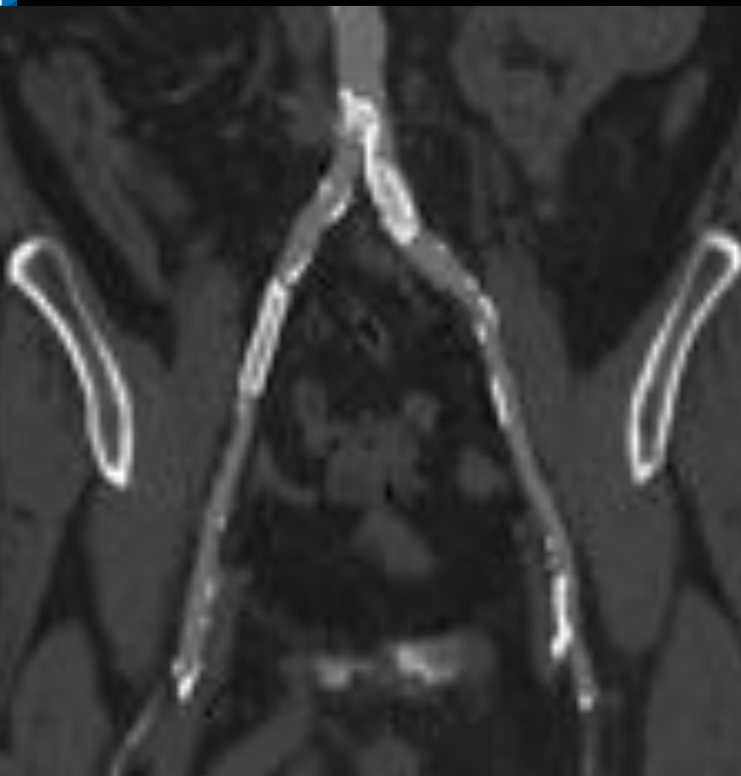
- 28 pts, Fontaine IV
- 64-detector CTA
- 14/28 → endovascular and/or surg. Tx
- correct decision-making for interventions, amputation, and medical Tx based on DSA and Tx response

Management of both IC and CLI by CTA

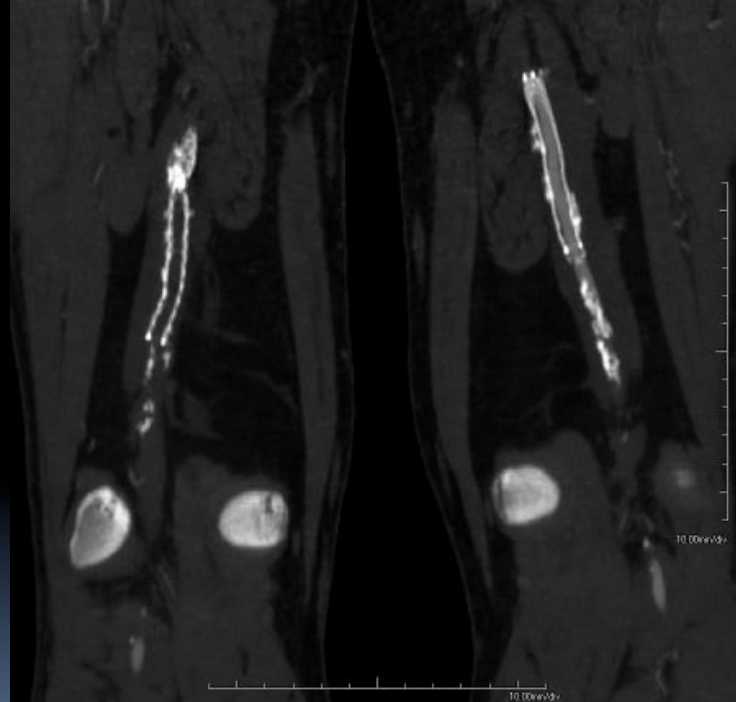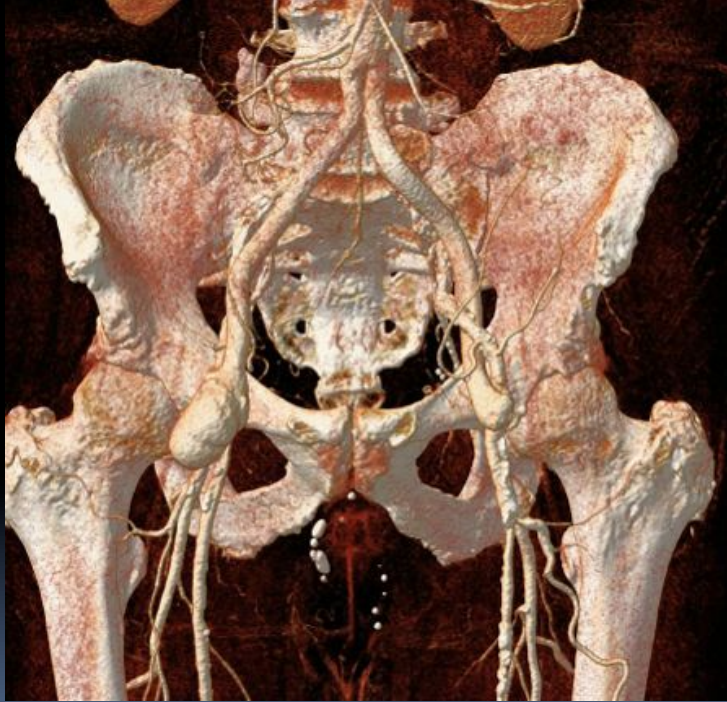- Treated using TASC II guidelines
 - 49 conservative TX
 - 87 Endovascular
 - 38 surgery
 - 17 hybrid
- Tx recommendations from CTA same as DSA
in all but ONE



Buttock Claudication – Calcified Aorto-iliac Disease



Post-TX Assessment by CTA

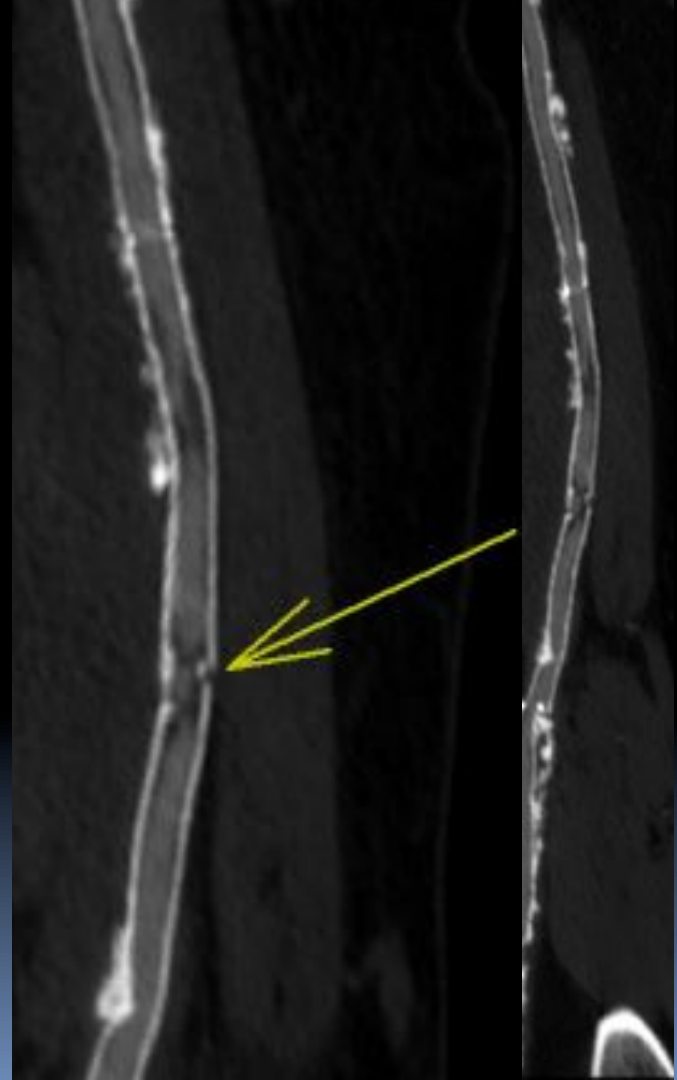

CTA for stent assessment

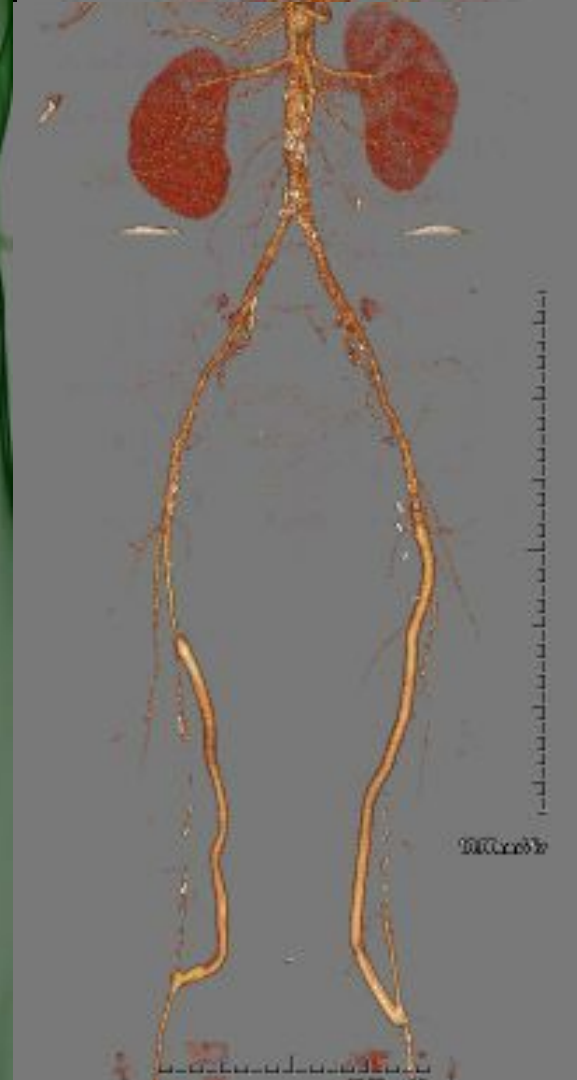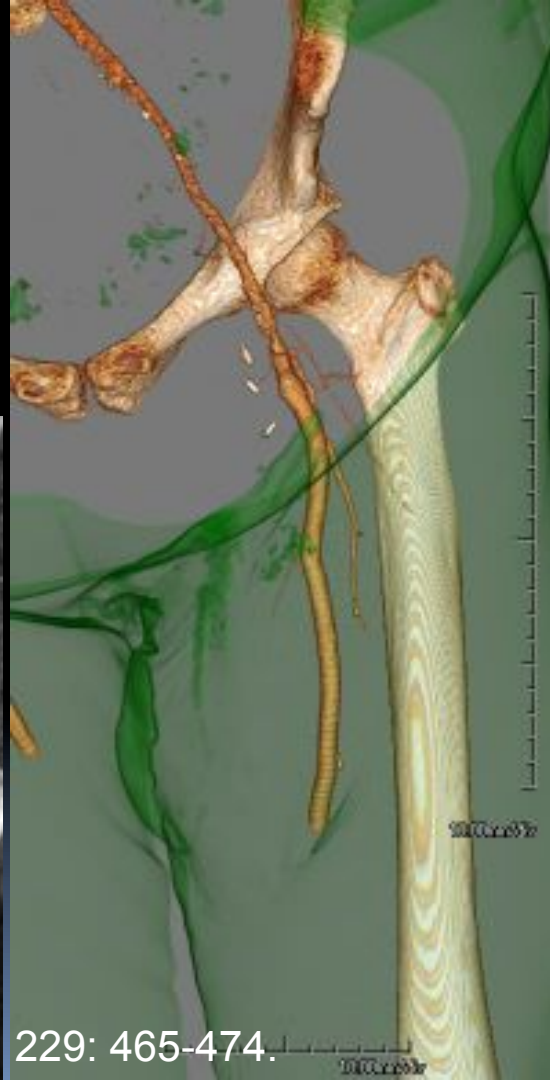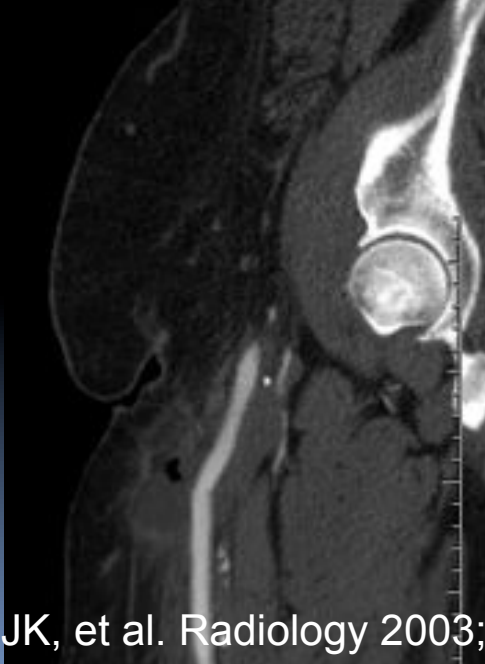
- Most stents assessable (76%) by CTA
 - Gold / platinum markers
 - Motion
 - Strecker stent (Tantalum): Increased luminal density²
- If evaluable, **sens/spec ~ 95%** for significant in-stent restenosis (vs. DSA)

¹ Li X, et al. Eur J Radiol 2010; 98-103

² Strotzer, Invest. Radiol. 2001:36(11)



CTA for assessment of complications



Willmann JK, et al. Radiology 2003; 229: 465-474.

Cost-Effectiveness of CTA

CTA as cost-effective care vs DSA

- ✦ 2005: Randomized, controlled trial: 4-DCT vs DSA¹
 - ✦ Dx confidence slightly lower with CTA (calcifications)
 - ✦ CT cost-effective and provides sufficient information for Tx planning
 - ✦ DSA costs (564 Euro) greater than CTA (363)

¹ Kock, MC, et al. Radiology 2005. 237 (2) pp. 727-37

CTA as cost-effective care vs MRA

- 2005: RCT - 156 pts CTA vs MRA
- CTA/MRA utility similar
- CTA lower diagnostic costs /patient
 - Average costs: \$199 vs \$627
 - Difference from imaging test itself, not from additional procedures

CTA as cost-effective care (vs. US and MRA)

- 2008: DIPAD Trial (Multicenter RCT)
- 514 PAD pts, randomized to Doppler/MRA/CTA
- CTA and MRA:
 - significantly higher diagnostic confidence
 - less additional imaging needed
- Total costs lower for CTA

Integrating CTA into cost-effective care

- ★ 2005: Randomized, controlled trial: 4-DCT vs DSA¹
 - ★ Dx confidence slightly lower with CTA (calcifications)
 - ★ CT cost-effective and provides sufficient information for Tx planning
 - ★ DSA costs (564+/- 210) greater than CTA (363 +/- 273)
- ★ 2007: Correct TX recommendations for I.C.²
- ★ 2009: Correct TX recommendations for CLI³

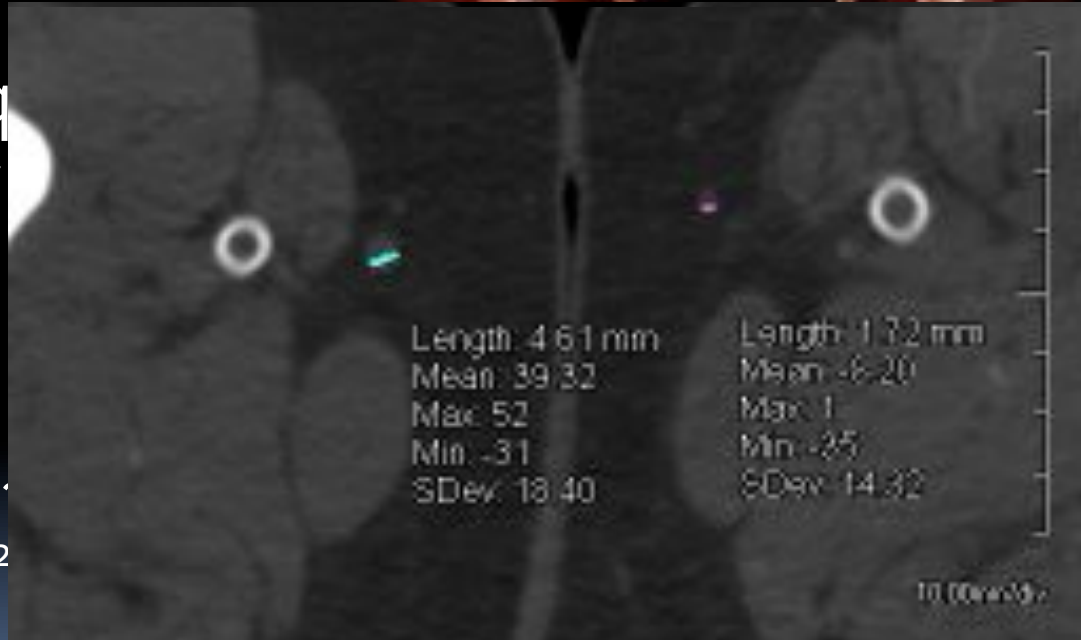¹ Kock, MC, et al. Radiology 2005. 237 (2) pp. 727-37

² Schernthaner, R, et al. AJR 2007; 189:1215-1222

³ Schernthaner, R, et al. AJR 2009; 192:1416-1424

Value-Added Info from CTA: GSV mapping¹⁻²

- Pre-Op CTA: Adeq evaluation of GSV
 - SENS/SPEC >90% (high thigh)
 - Charge savings of authors site alone²
 - If GSV \leq 2 mm, then do Doppler US

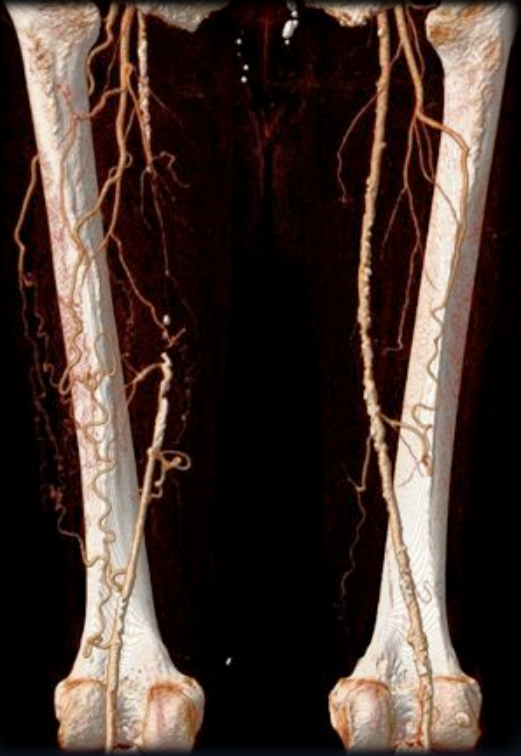

¹DeFreitas DJ, et al. J Vasc Surg 2013; 57(1): 5-55.

²Johnston WF, et al. J Vasc Surg 2012; 56(5): 1331-37.

Conclusions

- LE CTA is an accurate and cost-effective tool for assessment of various forms of peripheral arterial disease
- Implementation of integrated CM/scan protocol will improve consistency
- Clinical integration and uses will continue to expand



Thanks for your Attention!

- Special thanks to.....
 - Dominik Fleischmann, MD

