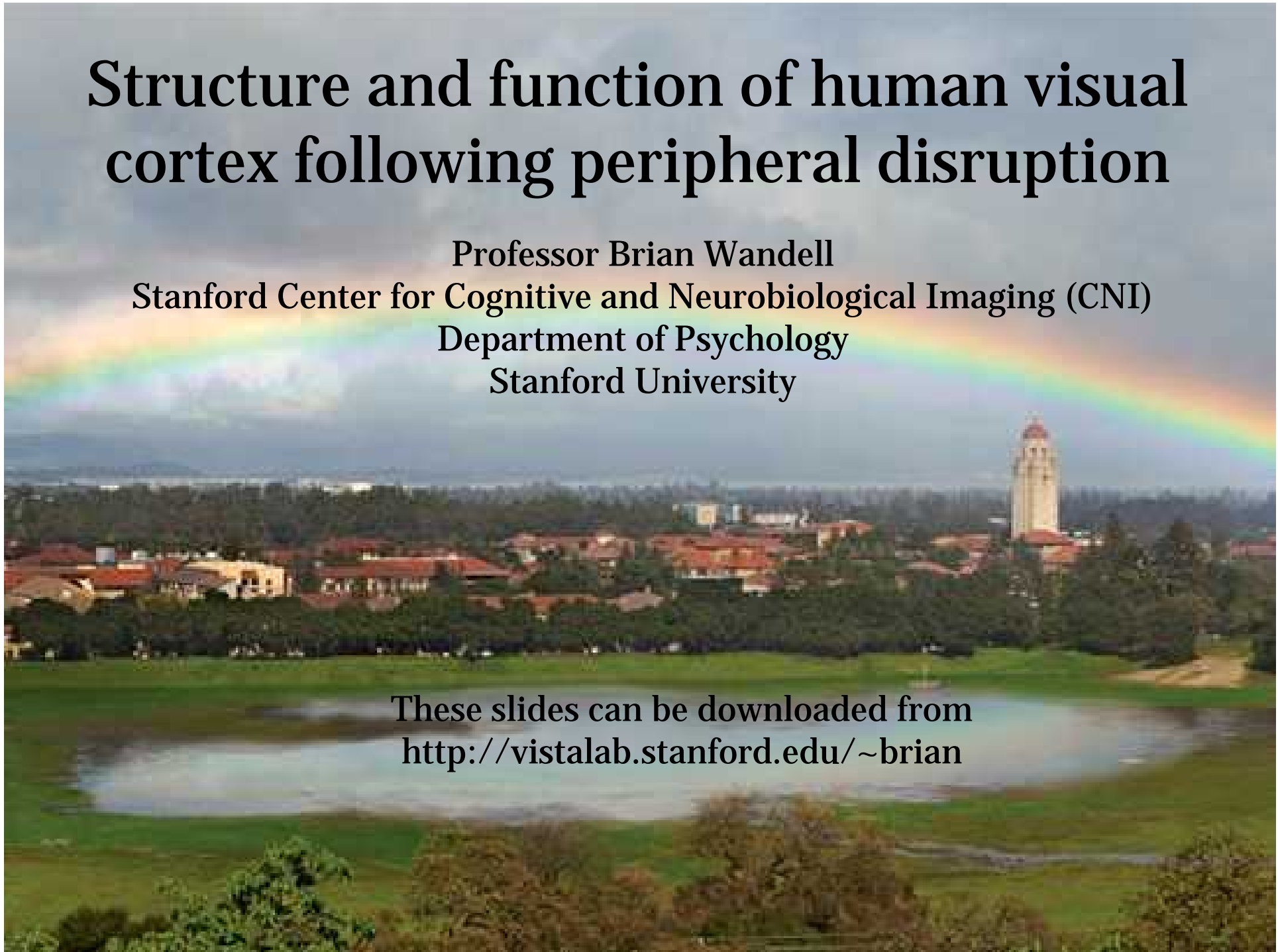


# Structure and function of human visual cortex following peripheral disruption

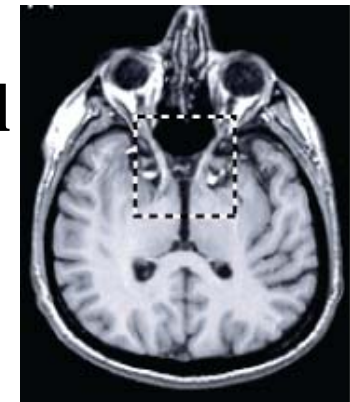

Professor Brian Wandell  
Stanford Center for Cognitive and Neurobiological Imaging (CNI)  
Department of Psychology  
Stanford University

These slides can be downloaded from  
<http://vistalab.stanford.edu/~brian>



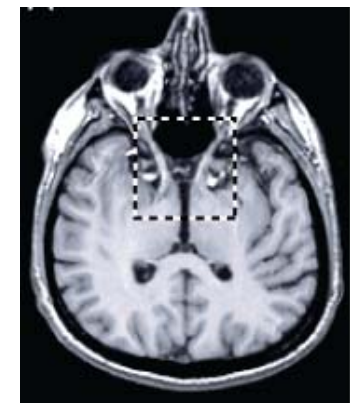

# Plasticity and stability in human visual cortex

- What does functional magnetic resonance imaging (fMRI) reveal about the stability and plasticity of human visual cortex across the lifespan?
- What are the consequences of abnormal development for V1 maps and responses?
- What are the consequences of acquired retinal dysfunctions for V1 maps and responses?



# Plasticity and stability in human visual cortex

- In congenital and developmental studies, human fMRI measures substantial cortical reorganization
- In adult retinal dysfunction produces
  - A. Stable feedforward mapping
  - B. Atypical cortical interactions



# Measuring visual field maps

- Imaging retinotopic maps in the human brain. B. A. Wandell and J. Winawer (2011). **Vision Research**, Volume 51, Issue 7, 13 April 2011, pp. 718-737. Vision Research 50th Anniversary Issue
- Visual Field Maps in Human Cortex. B. A. Wandell, S.O. Dumoulin and A. A. Brewer (2007) **Neuron**, V. 56 , p. 366-383

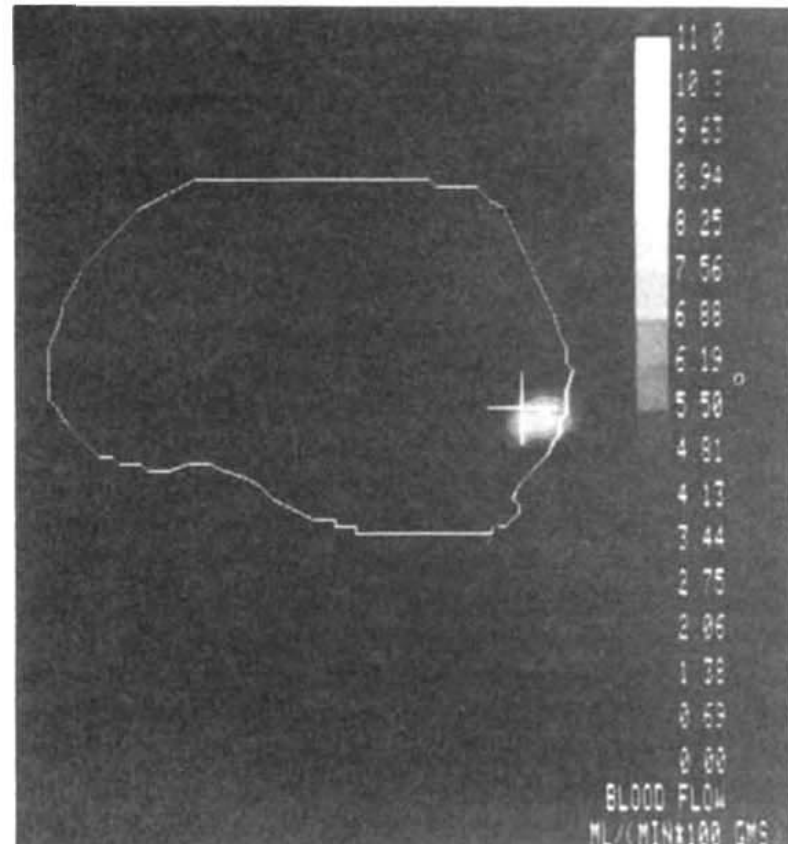
# Progress in measuring human visual cortex

PET images were exciting but of limited quality.

These data were striate cortex mapping with PET.

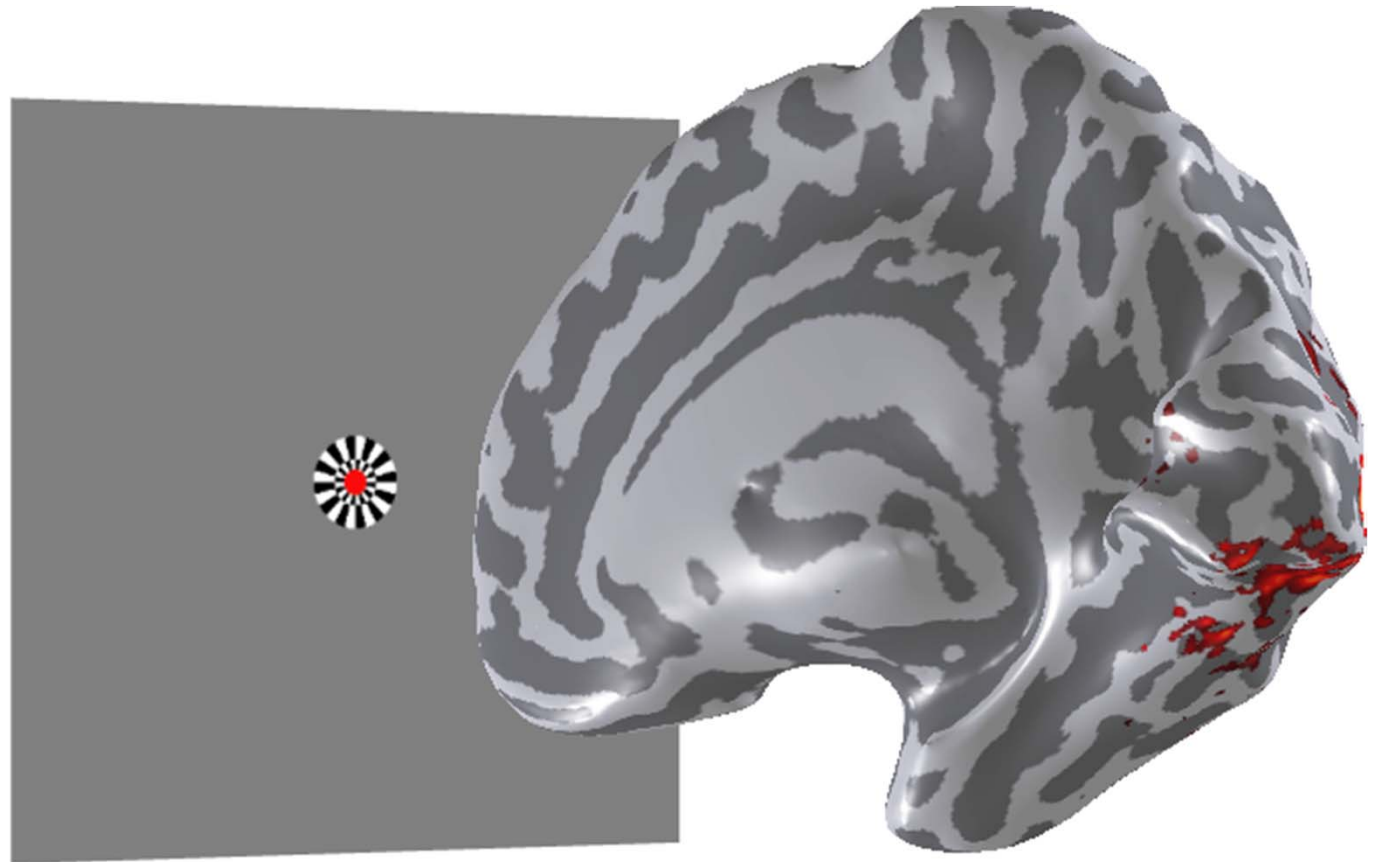
“Little is known about the organization of extrastriate visual areas in the human brain. Therefore, to construct our proposal we must draw upon data from experimental work in monkeys. (Horton and Hoyt, 1991, **Brain**)”

Fox et al., Mapping human visual cortex with positron emission tomography. *Nature*, 1986

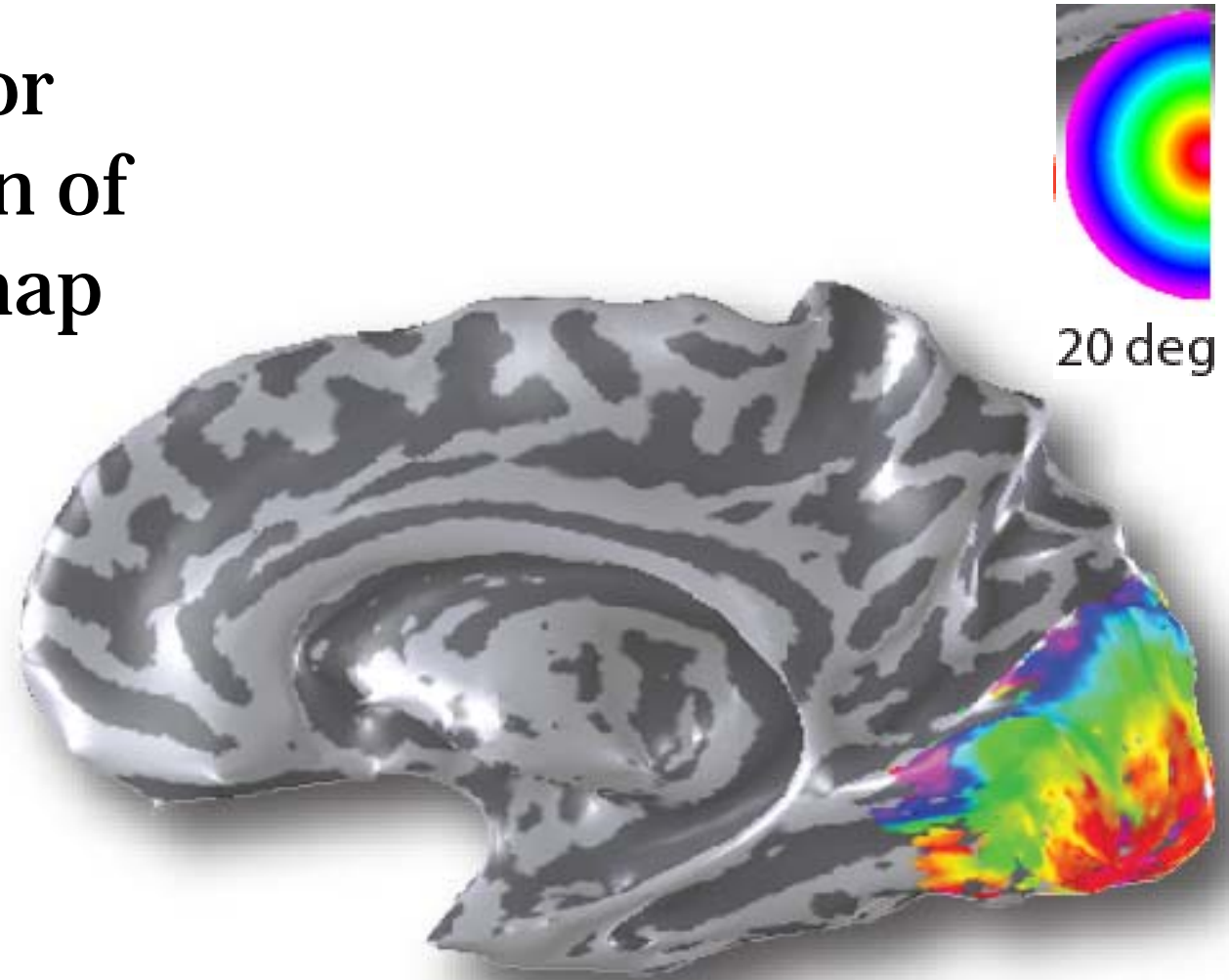


# Human eccentricity mapping

(DeYoe, 1994; Engel et al., 1994,1997; Sereno 1995)

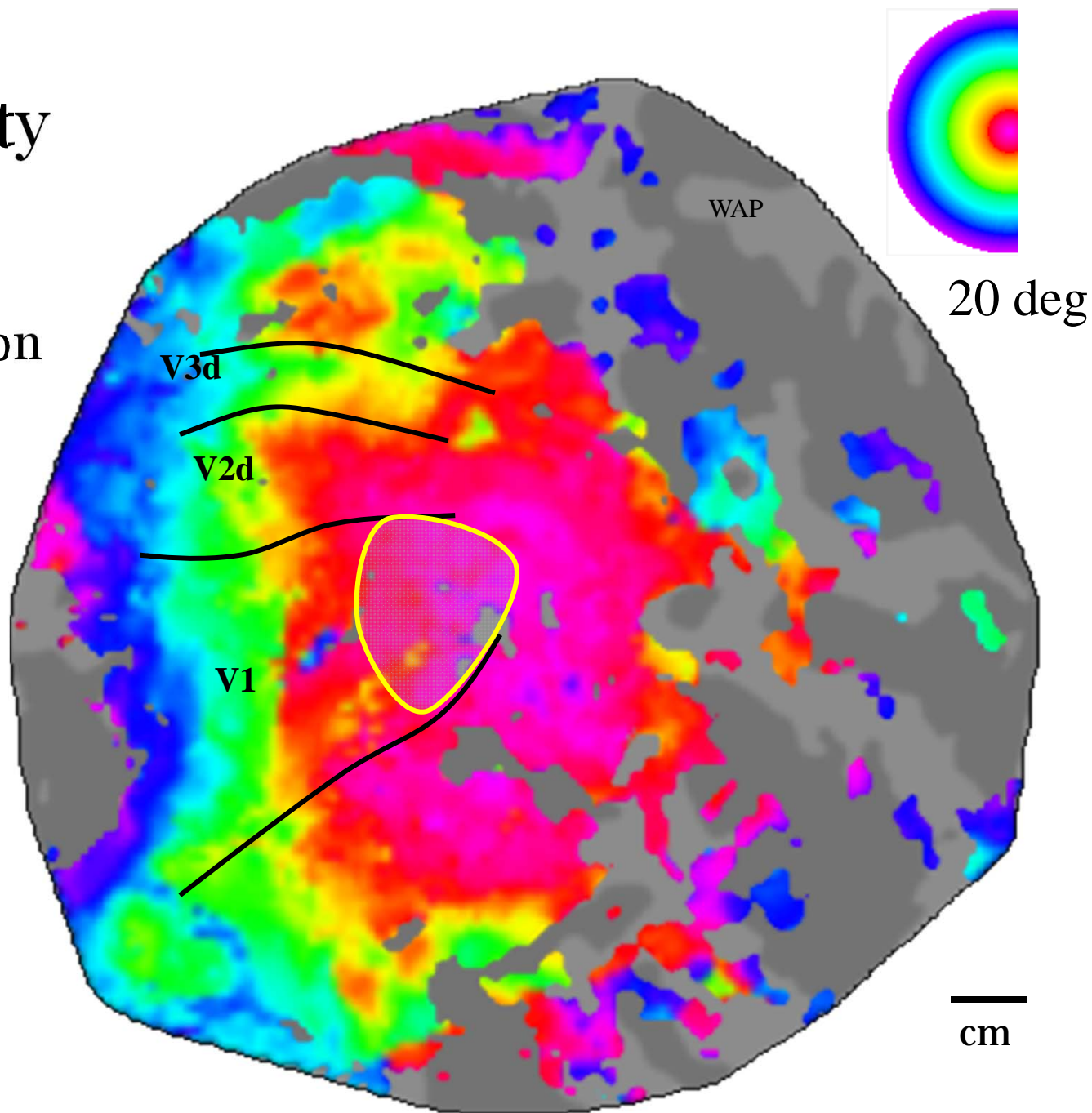


# Pseudo-color representation of visual field map




# Eccentricity Map Flattened Representation

The large  
**foveal V1**  
projection  
zone, outlined  
in yellow,  
is several  
square  
centimeters

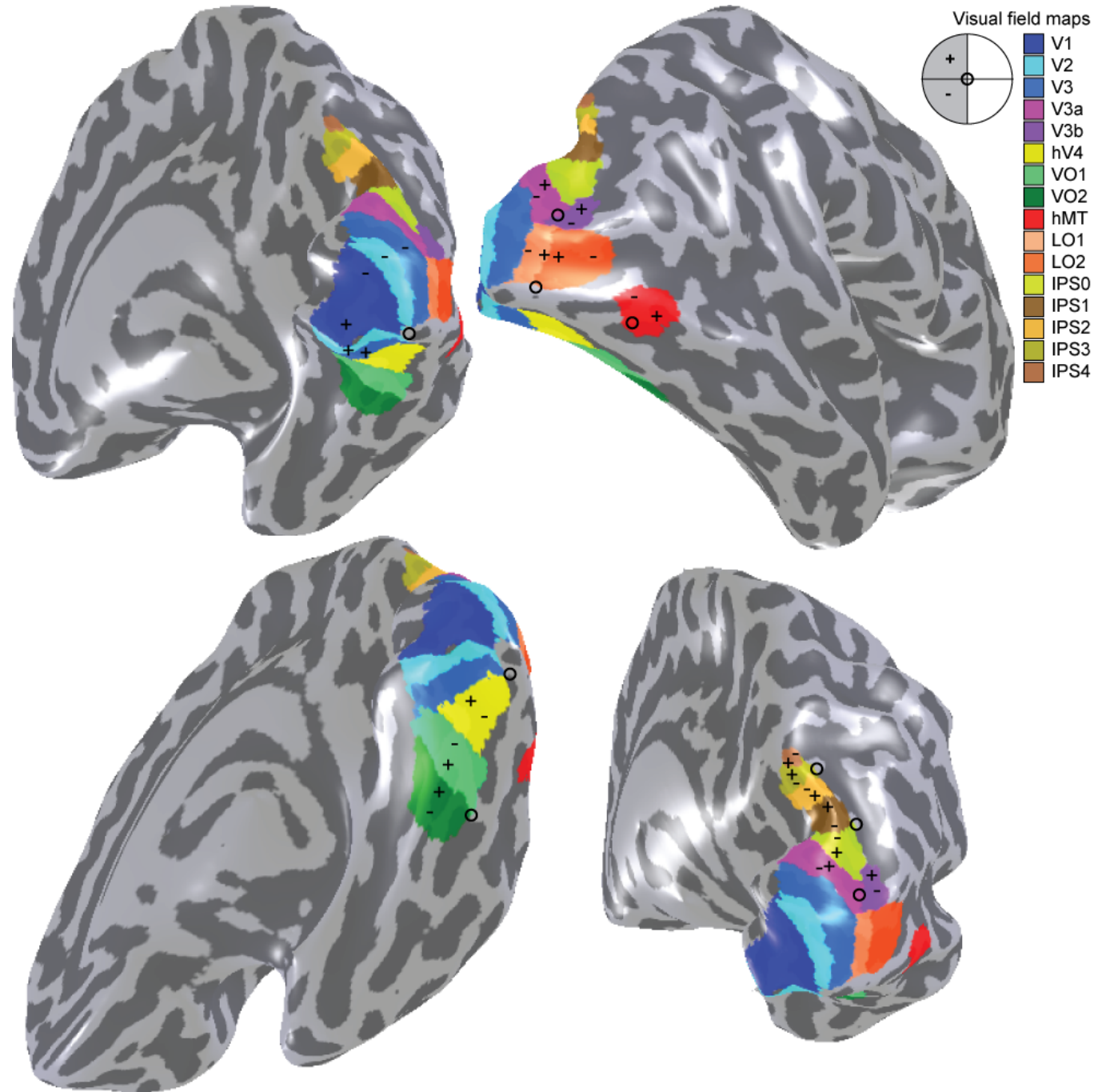


Angular  
measurements  
sharply delineate  
visual field map  
boundaries



# More than sixteen visual field maps

Wandell,  
Dumoulin,  
Brewer (2007)  
Neuron



A scenic view of a city with a prominent tower and a rainbow in the sky. The tower is a tall, white, cylindrical structure with a red roof, likely the Campanile tower in Berkeley, California. The rainbow is a vibrant, multi-colored arc in the sky, stretching across the horizon. The city is visible in the background, with buildings and greenery. The sky is a mix of blue and grey, suggesting a cloudy day.

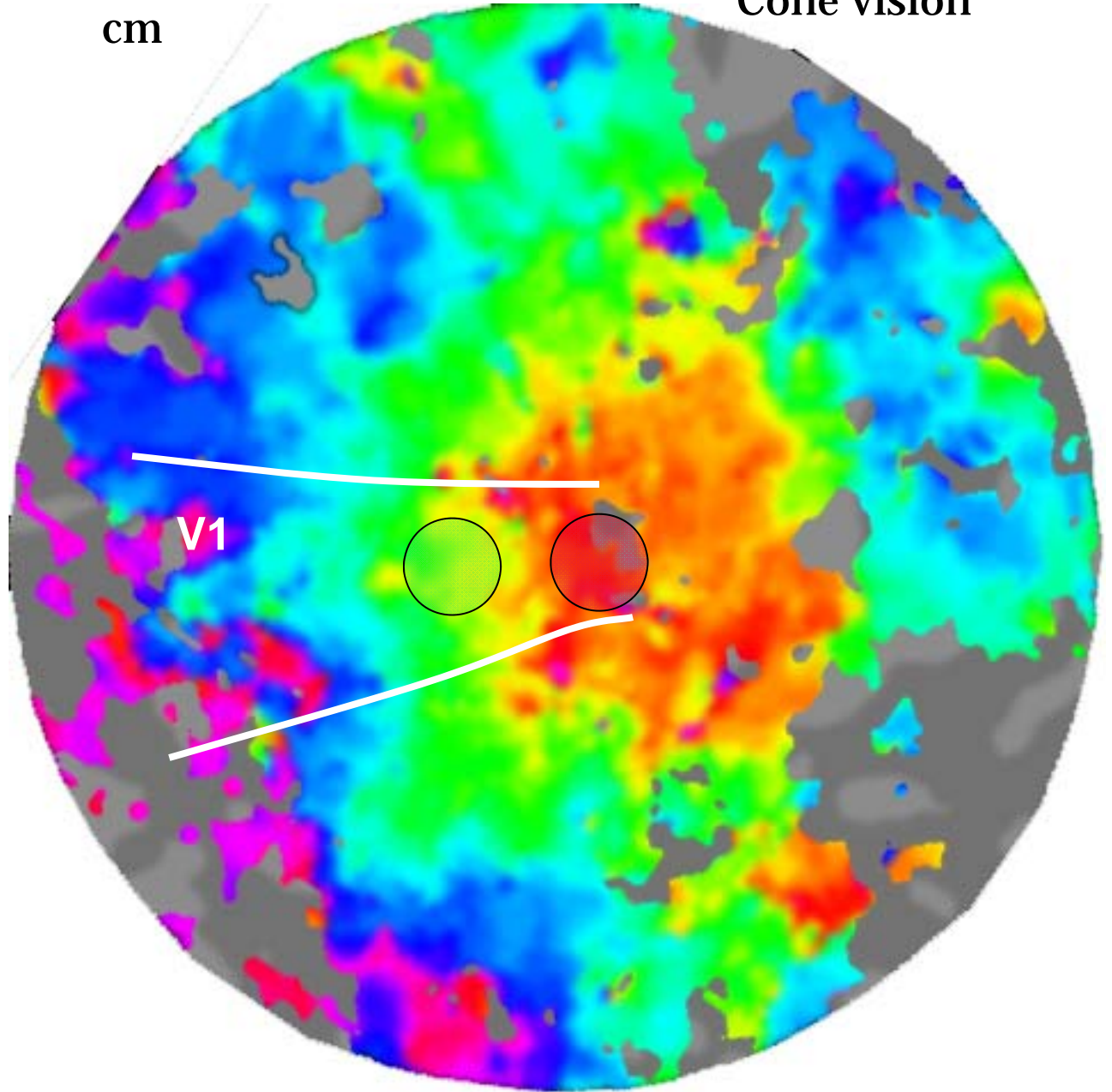
# Rod monochromacy

- Reorganization of human cortical maps caused by inherited photoreceptor abnormalities. Heidi A. Baseler, Alyssa A. Brewer, Lindsay T. Sharpe, Antony B. Morland, Herbert Jägle and Brian A. Wandell (2002). **Nature Neuroscience**, Apr;5(4):364-70.
- Projection of rods and cones within human visual cortex. Hadjikhani, N. and Tootell, R. B.H. (2000), **Hum. Brain Mapp.**, 9: 55–63.

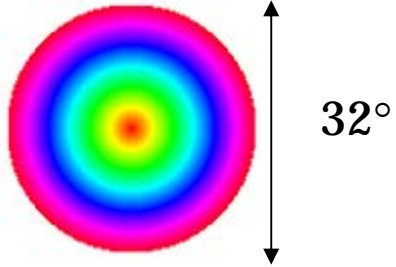
Cone vision

cm

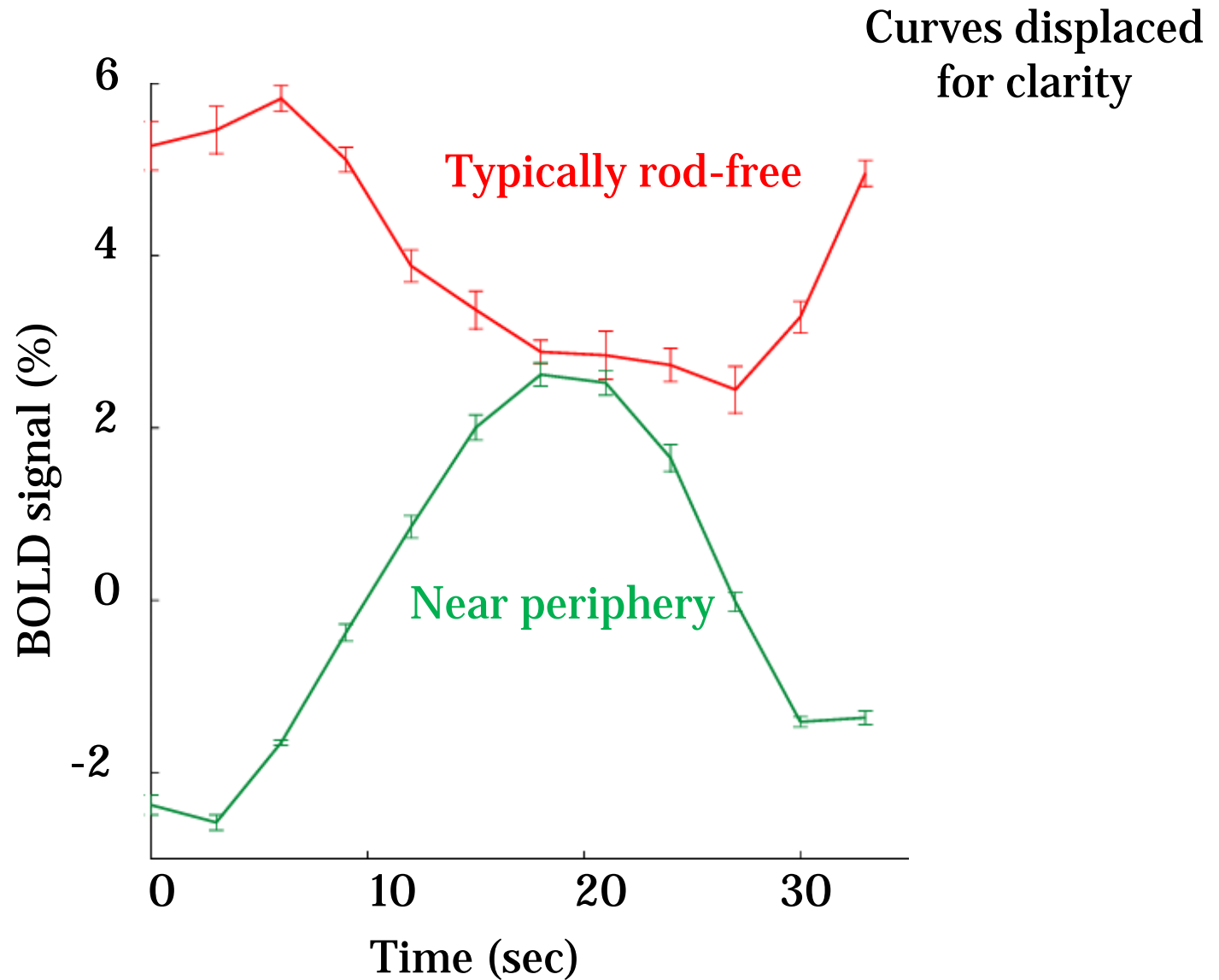
Control  
responses:  
Cone-  
mediated



V1



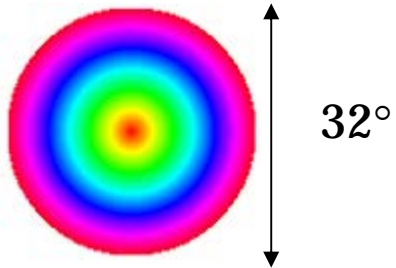
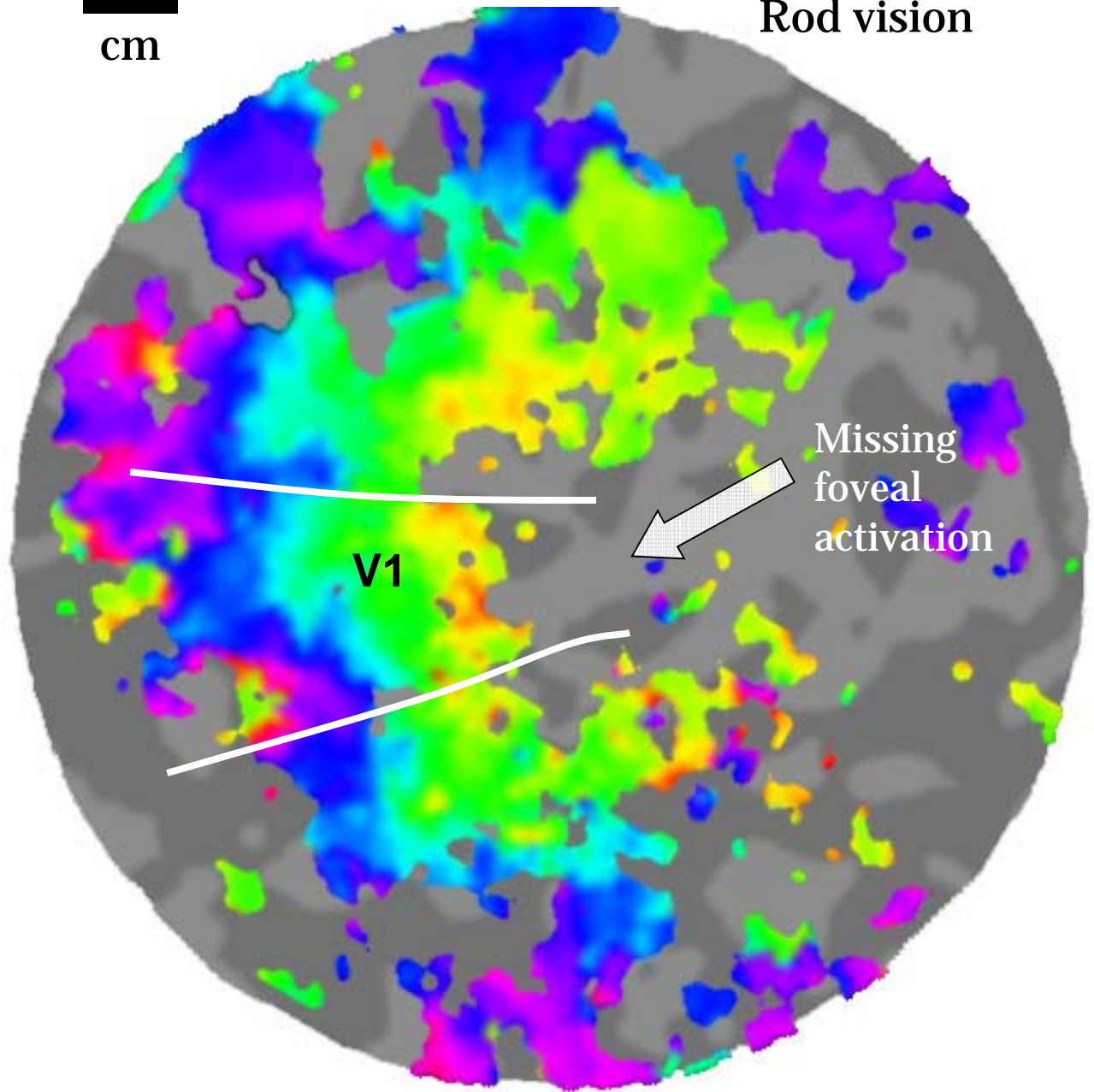
# Normal control FMRI time series



Rod vision

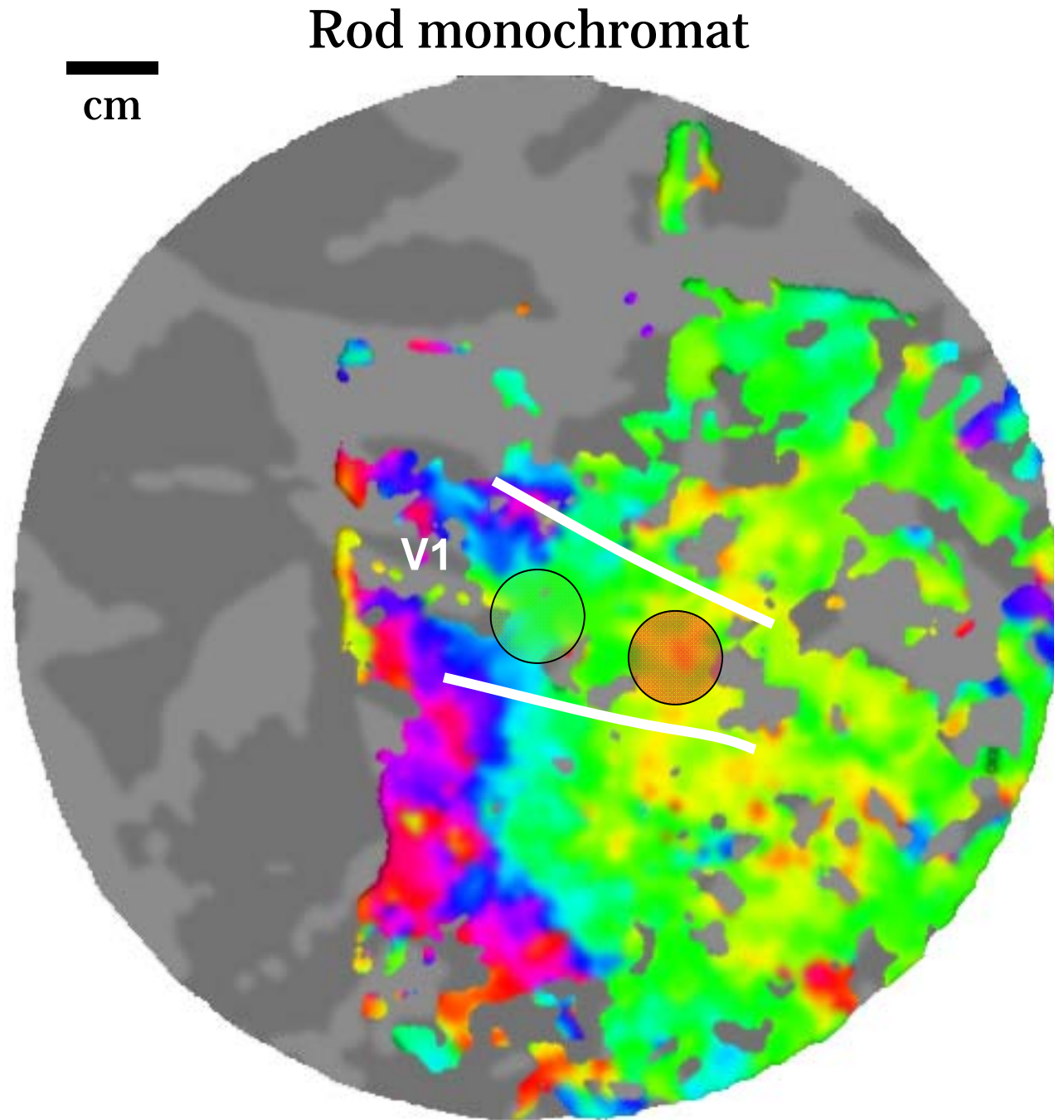
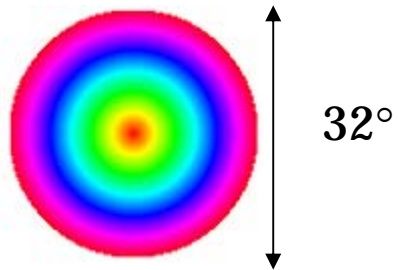
cm

Control  
responses:  
Rod-  
mediated



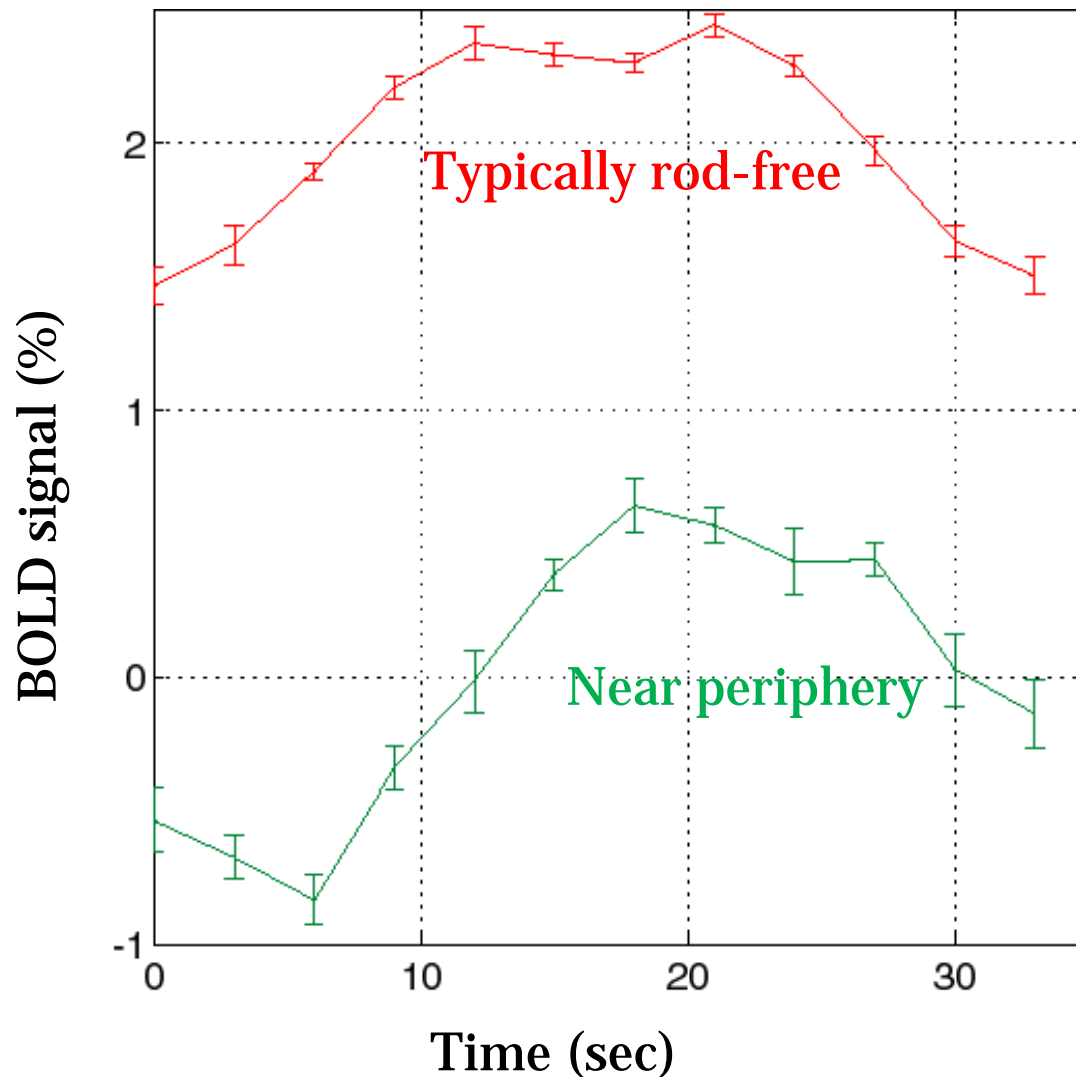
Rod  
monochromats  
develop a visual  
response in the  
rod-free zone

*Baseler et al., (2002)*

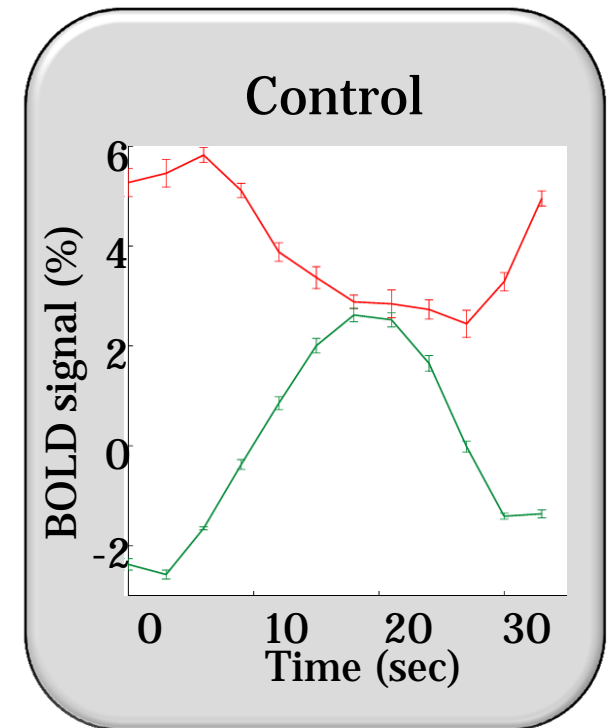


# Rod monochromat FMRI time series

amplitude is large



Curves displaced for clarity



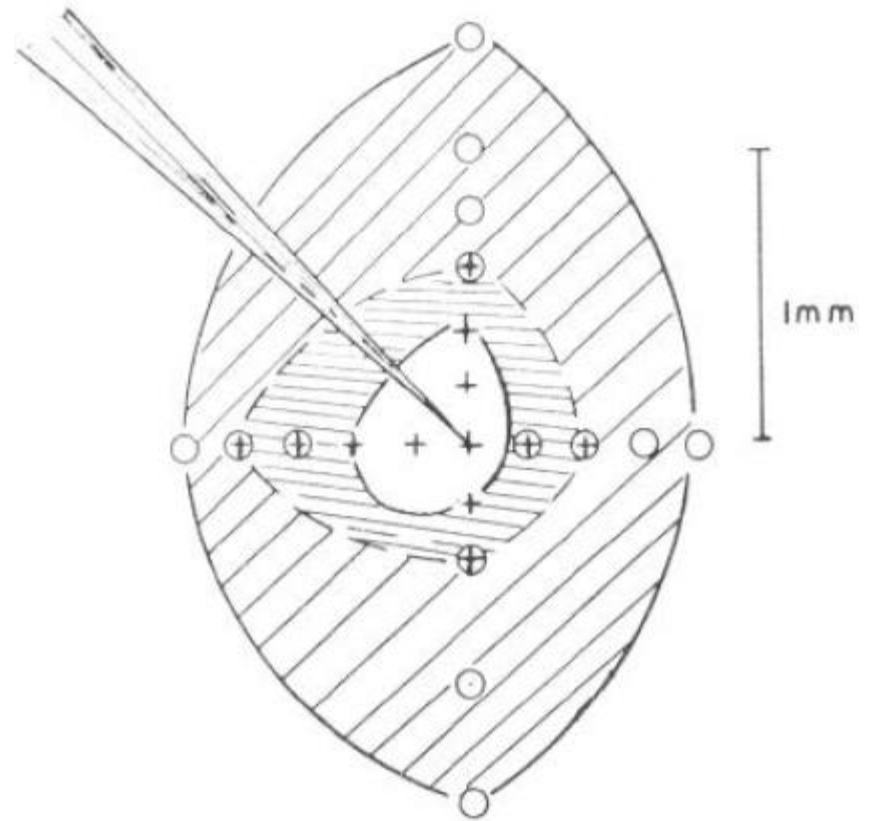
# The population receptive field

- Population receptive field estimates in human visual cortex. Serge O. Dumoulin and Brian A. Wandell (2007). **Neuroimage**. Volume 39, Issue 2, 15 January 2008, pp. 647-60
- Visual field maps, population receptive field sizes, and visual field coverage in the human MT+ complex. K. Amano, B. Wandell and S. Dumoulin (2009) **J. Neurophys.**
- Mapping hV4 and ventral occipital cortex: The venous eclipse. J. Winawer, H. Horiguchi, R. A. Sayres, K. Amano, B. A. Wandell (2010). **V. 10** 10(5),1,1-22 **Journal of Vision**

# The receptive field

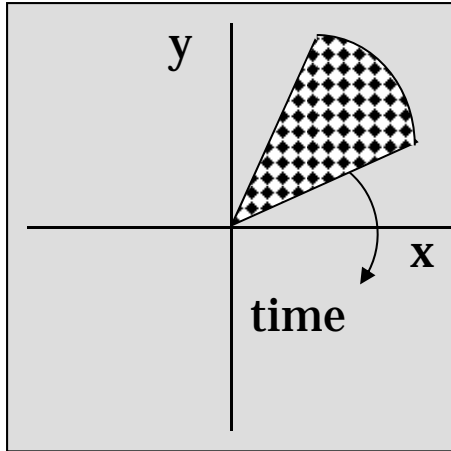
## Stimulus referred measurement

‘Responses can be obtained in a given optic nerve fiber only upon illumination of a certain restricted region of the retina, termed the receptive field of the fiber (Hartline, 1936)’.

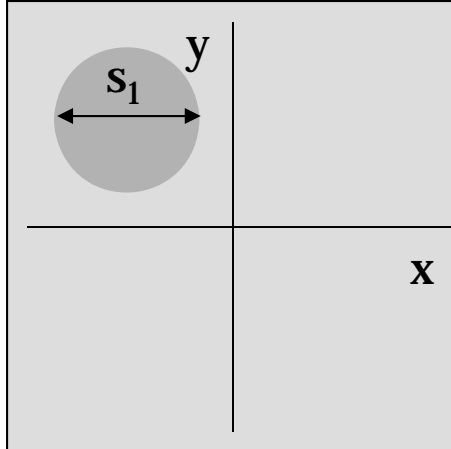


# Population RF estimation

Stimulus



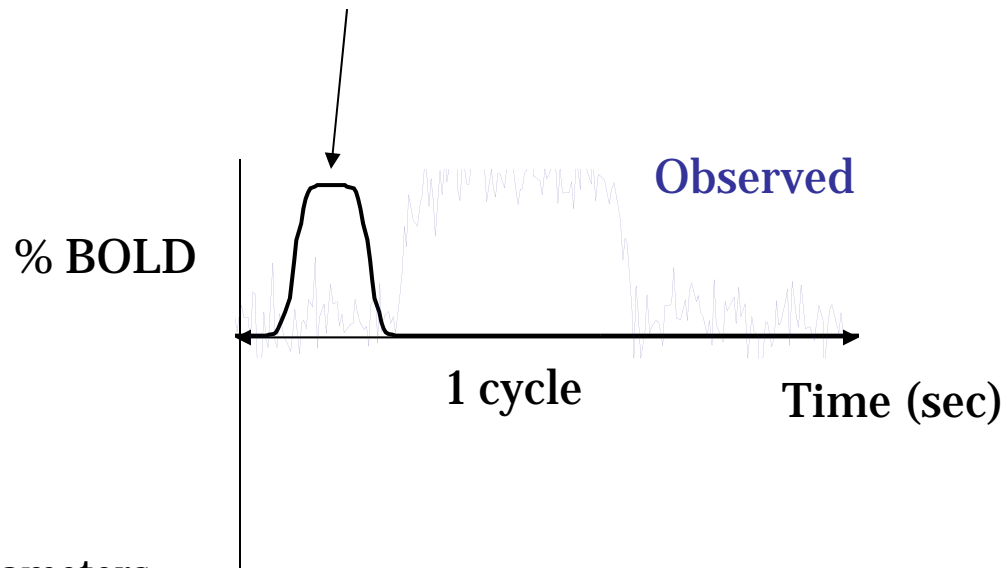
Population RF model



Parameters

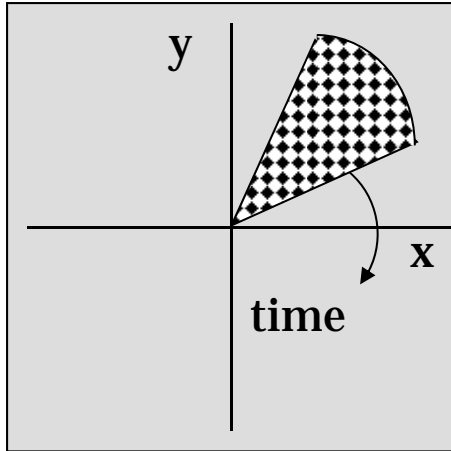
$(x_1, y_1, s_1)$

Predicted BOLD (including HRF)

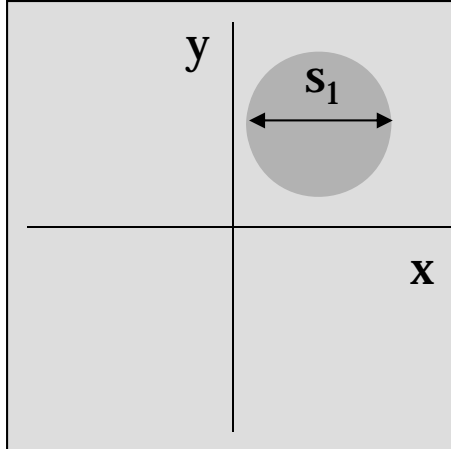


# Population RF estimation

Stimulus



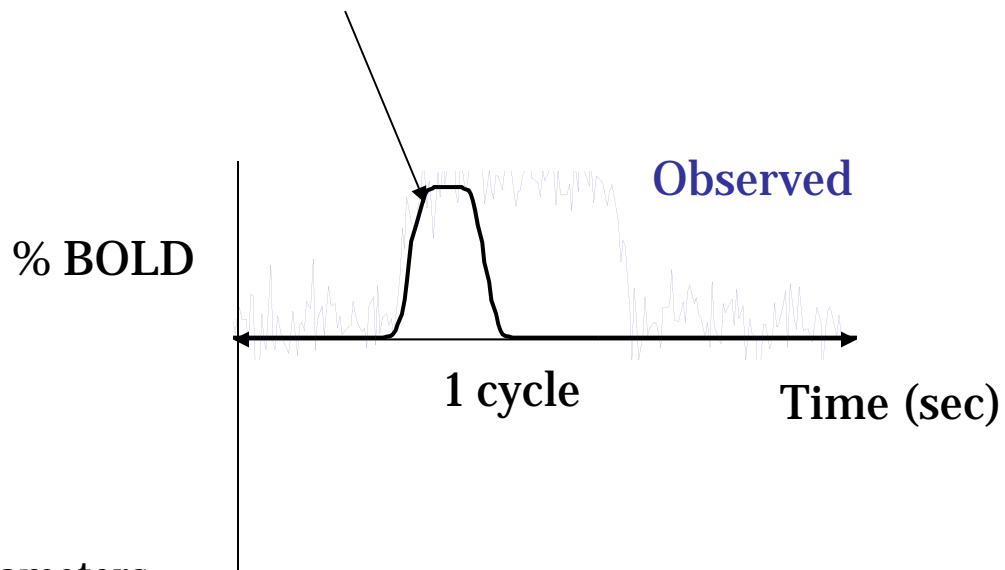
Population RF model



Parameters

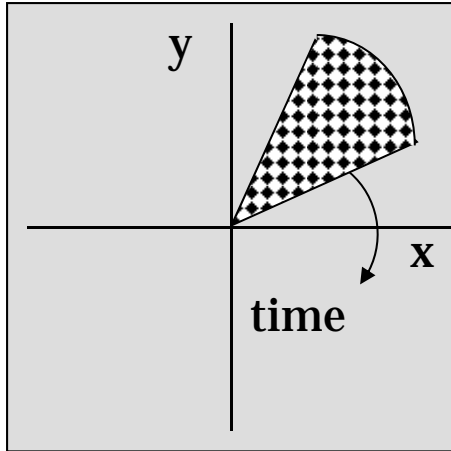
$(x_2, y_2, S_1)$

Predicted BOLD (including HRF)

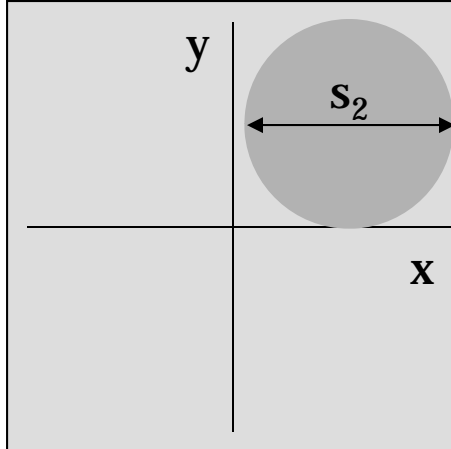


# Population RF estimation

Stimulus



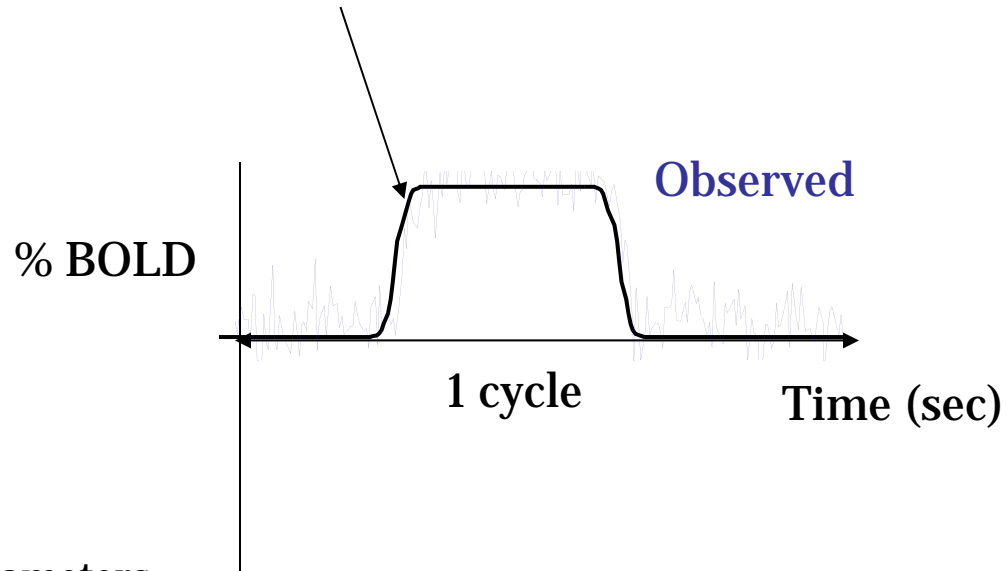
Population RF model



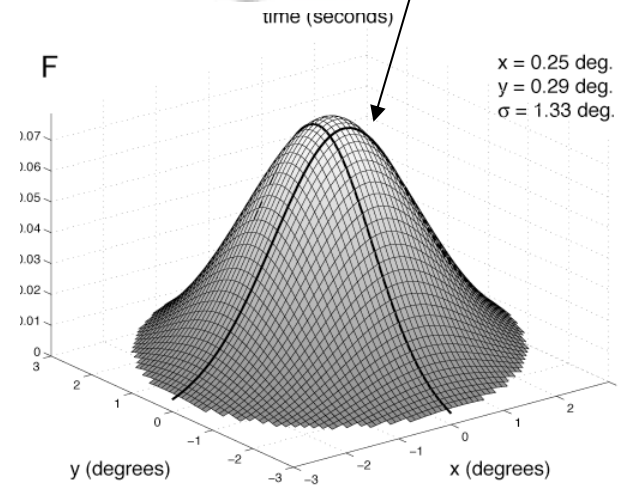
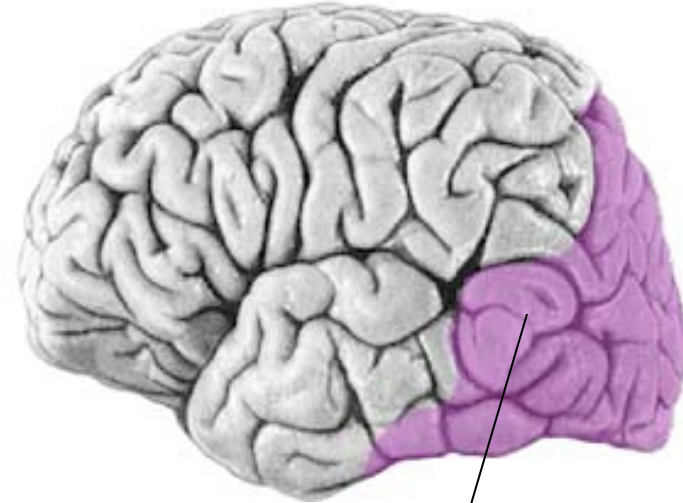
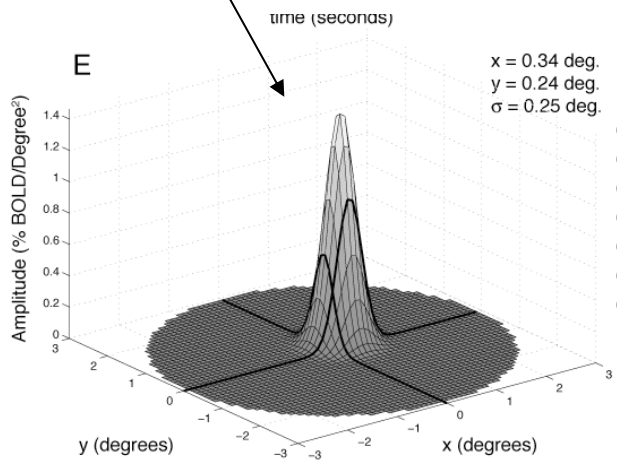
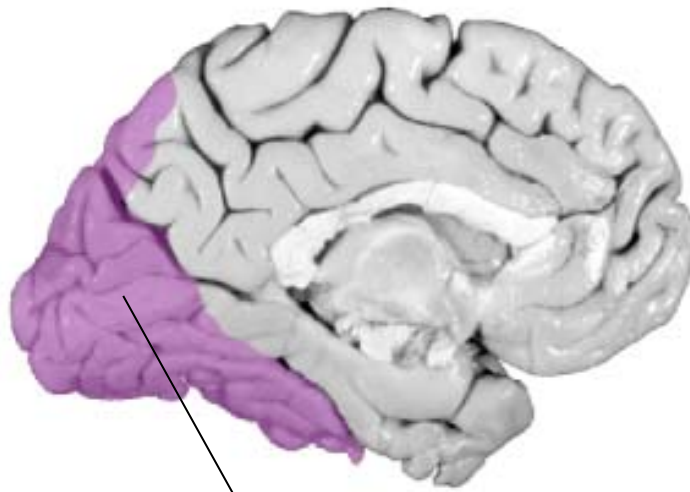
Parameters

$(x_2, y_2, S_2)$

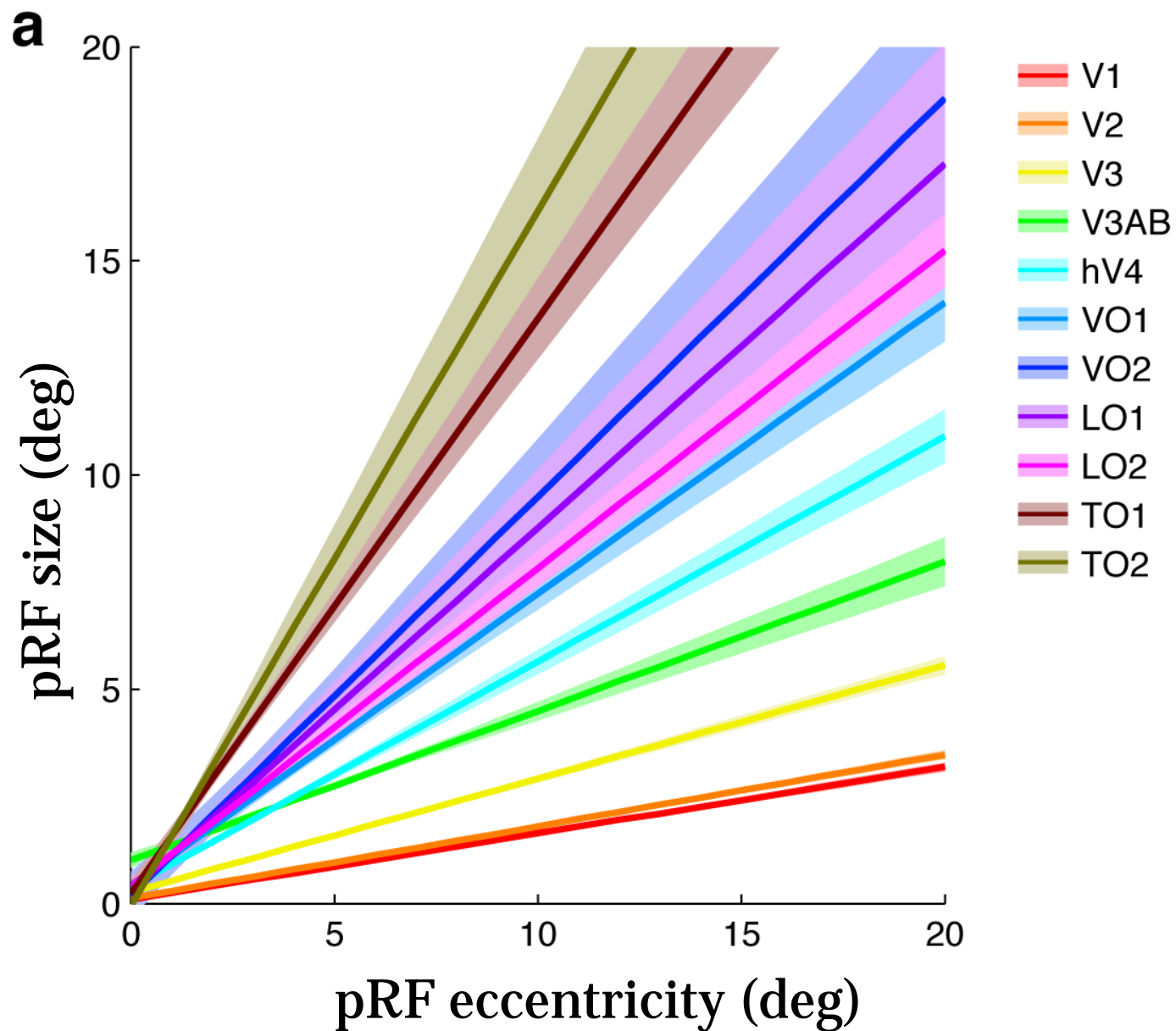
Predicted BOLD (including HRF)



# Population receptive field size varies significantly between maps (Dumoulin and Wandell, 2008)



Population  
RF  
increases  
with  
eccentricity  
in each map  
(Kay et al.)

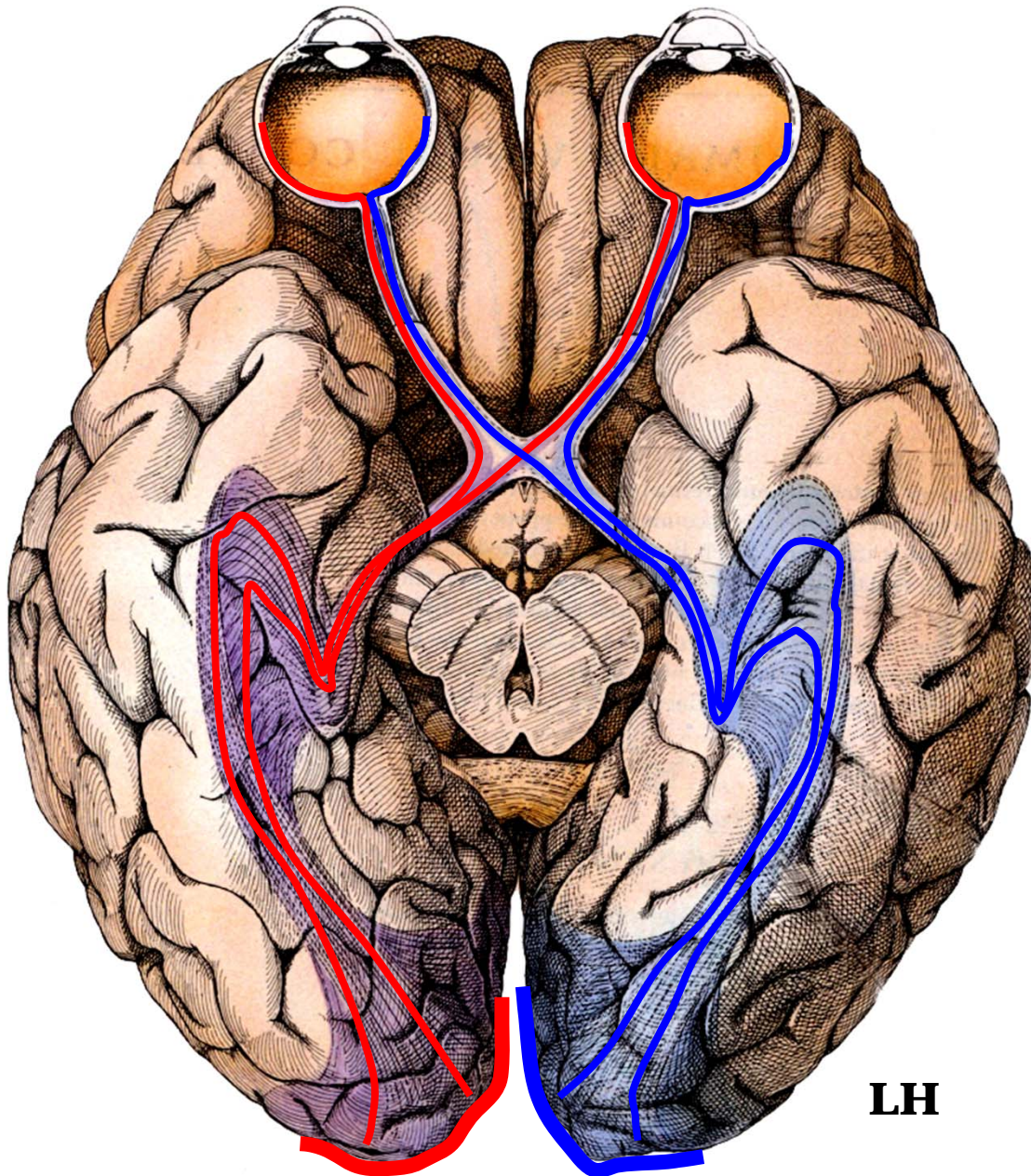


# Achiasma

- Congenital Achiasma and See-Saw Nystagmus in VACTERL Syndrome. S. Prakash, S. Dumoulin, N. Fischbein, B. A. Wandell, Y.J. Liao (2009). **J. Neuro-Ophthalmology** Volume. 29
- Plasticity and stability of the visual system in human achiasma. M.B. Hoffmann, F.R. Kaule, N. Levin, Y. Masuda, A. Kumar, I. Gottlob, H. Horiguchi, R.F. Dougherty, J. Stadler, B. Wolynski, O. Speck, M. Kanowski, Y.J. Liao, B.A. Wandell, S.O. Dumoulin. **Revision submitted.**

# Visual pathways

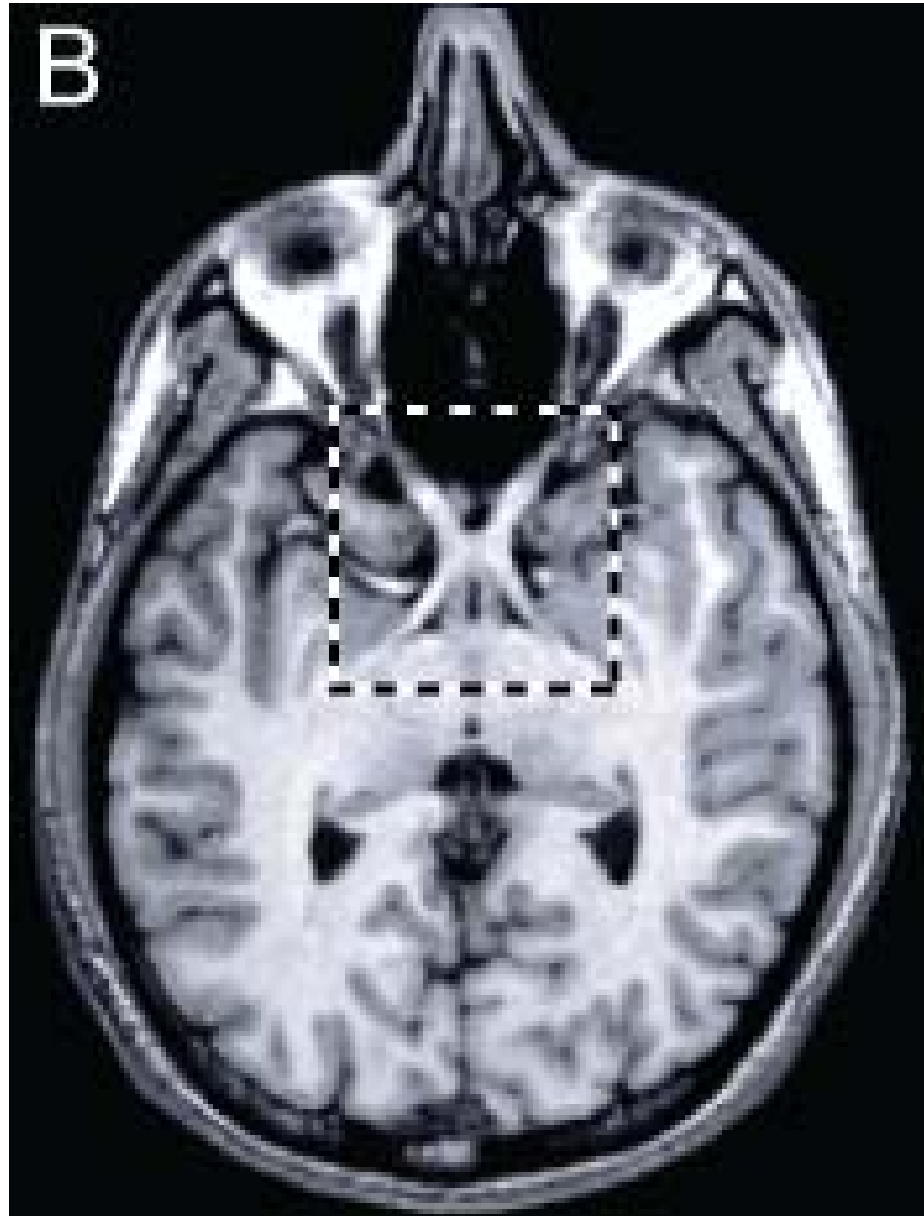
- Right visual field
- Left visual field



LH

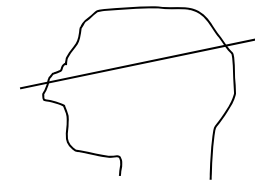


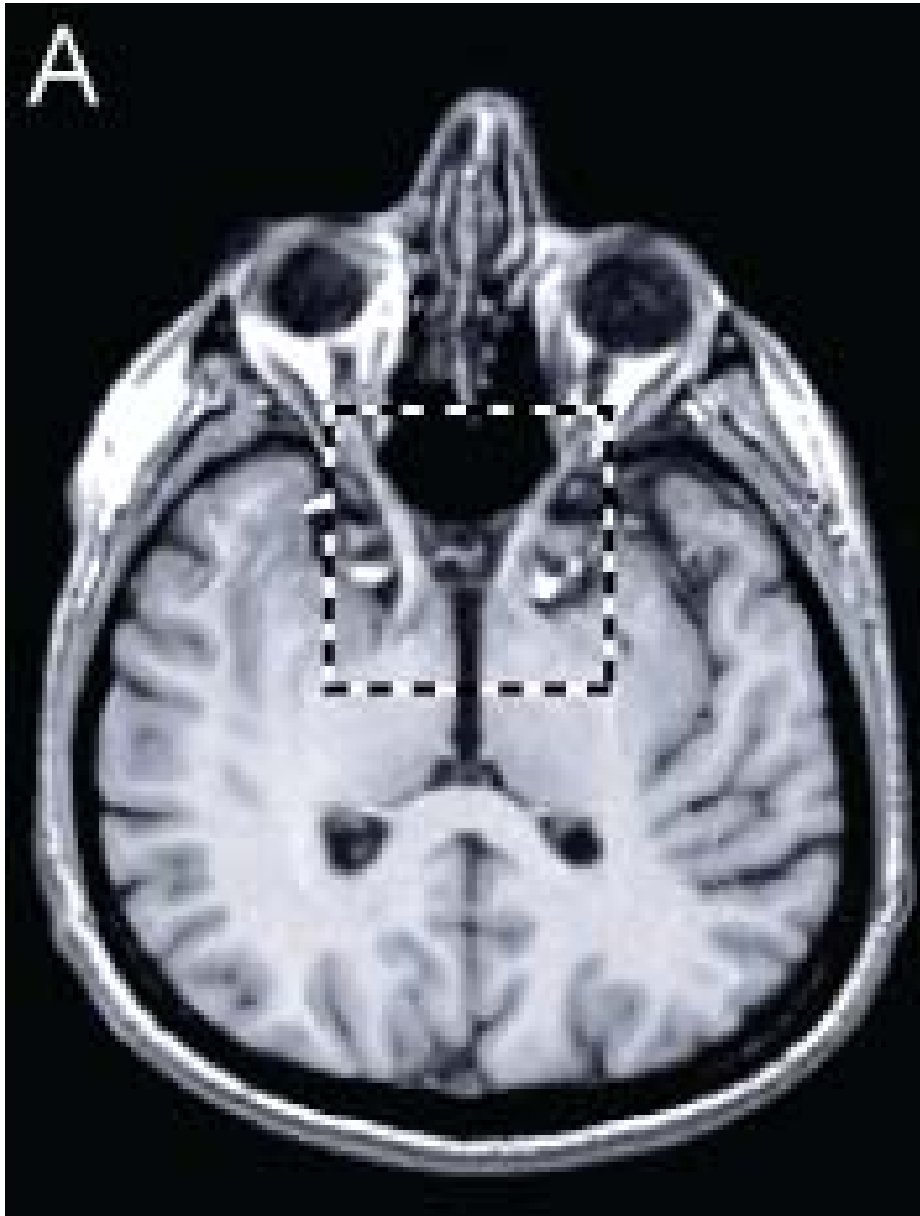Serge Dumoulin



Conventional  
optic chiasm

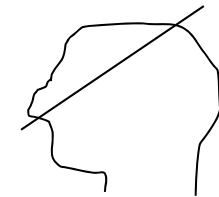
Control



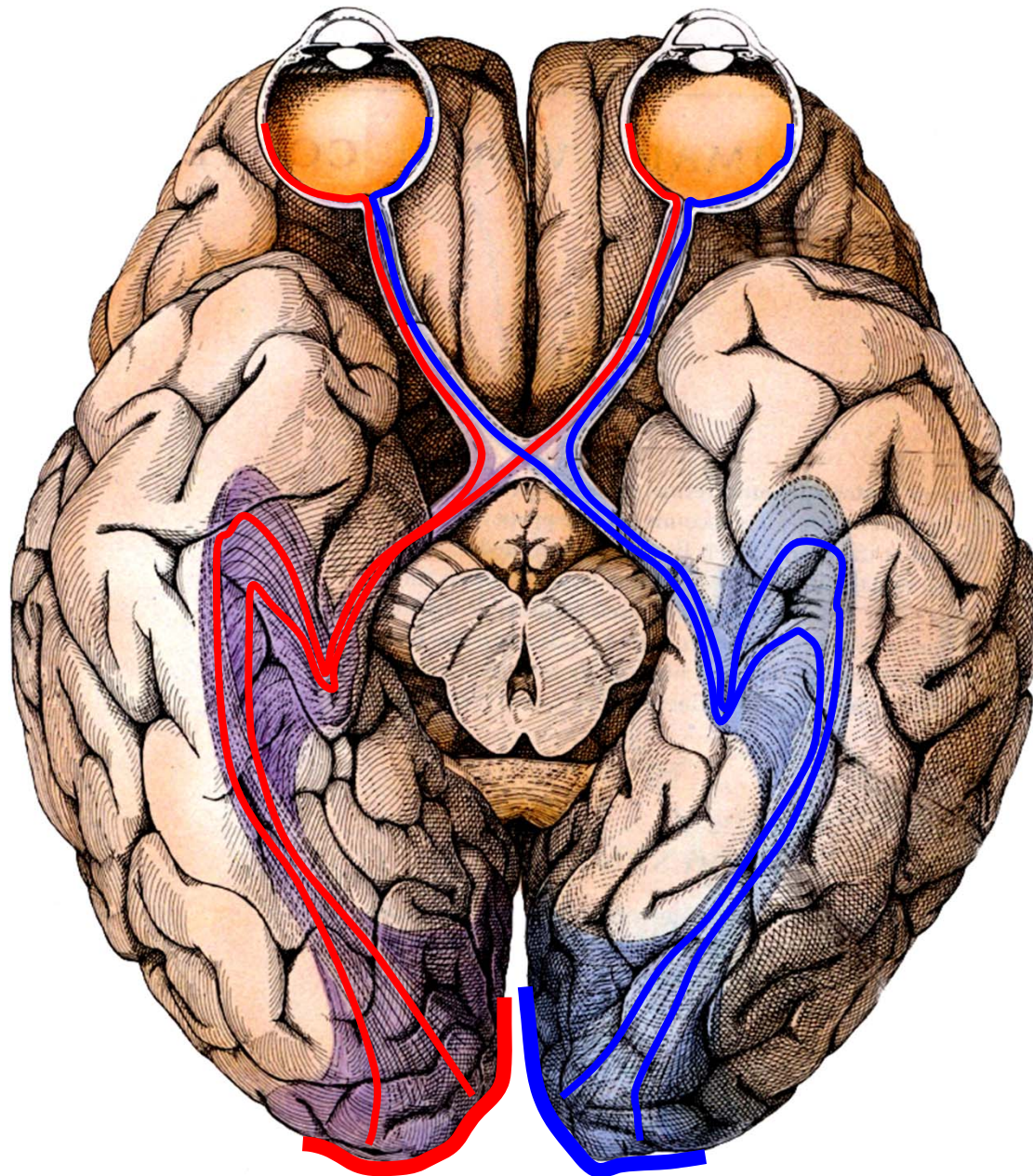


Missing optic  
chiasm

Achiasma



# Normal



— Right visual field

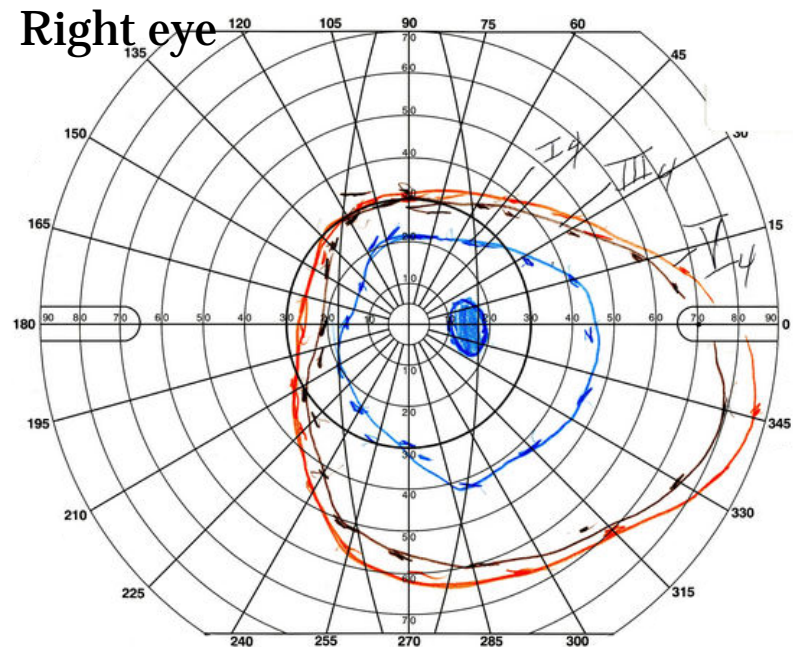
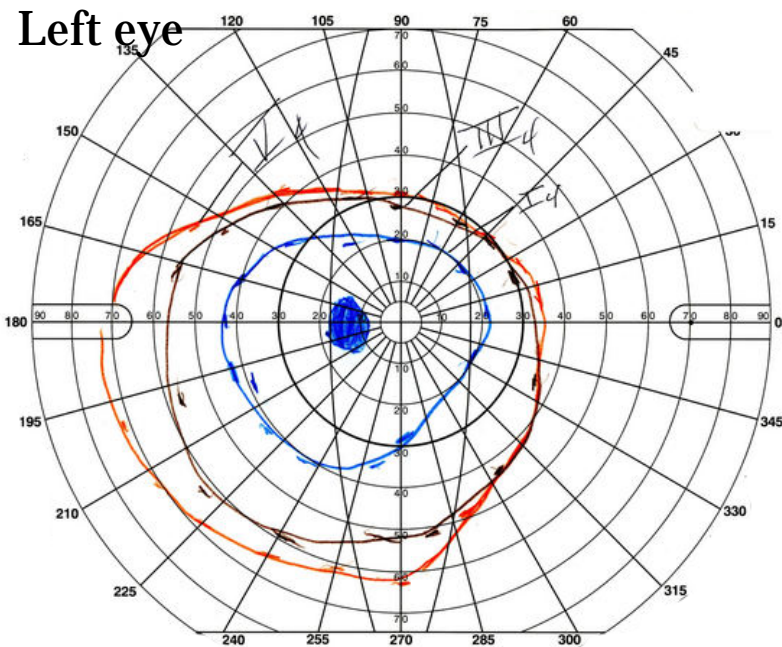
— Left visual field

Molecular guidance at chiasm mediated by Ephrin-B2 and EphB1 (Williams et al., 2003, Neuron)

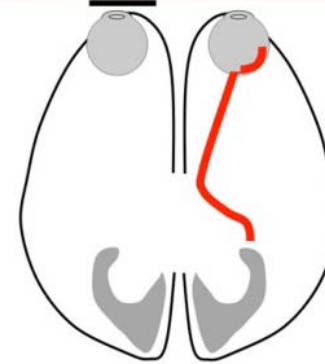



# Subject AC2 characteristics

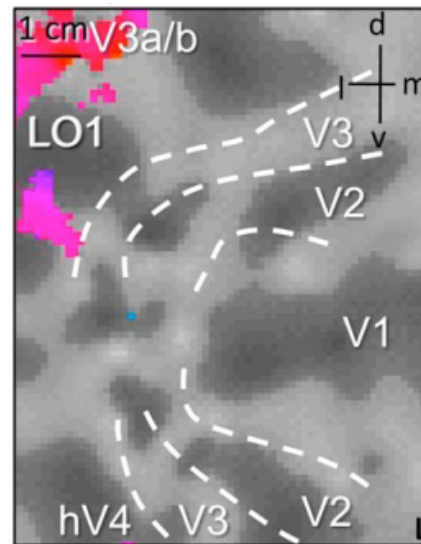
- Slight decrease in visual acuity
- Slightly reduced peripheral visual fields
- No stereopsis
- Prominent infantile and see-saw nystagmus (resolved)



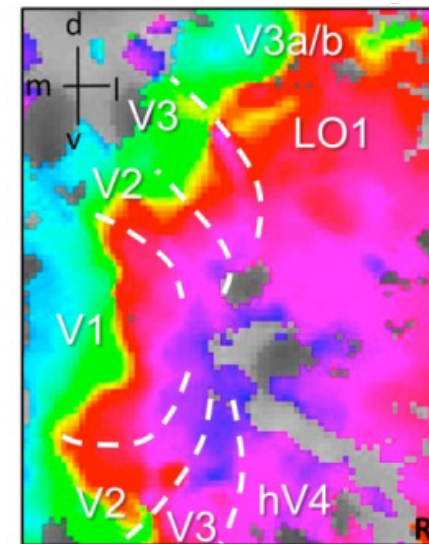
Right and left  
hemifield maps are  
overlaid in both  
hemispheres



Right eye

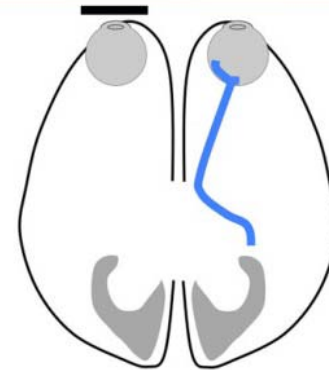
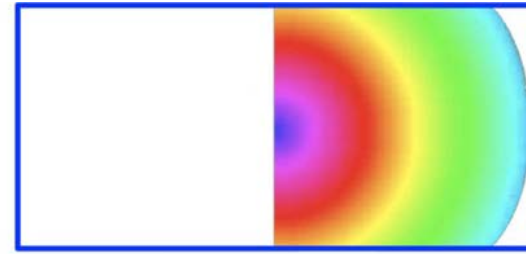


Left hemisphere




Right hemisphere

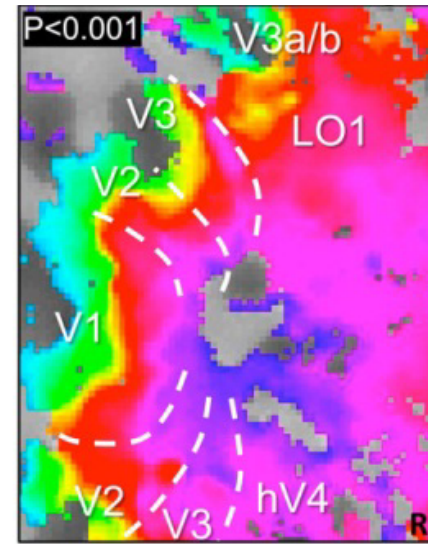
Right and left  
hemifield maps are  
overlaid in both  
hemispheres



Right eye


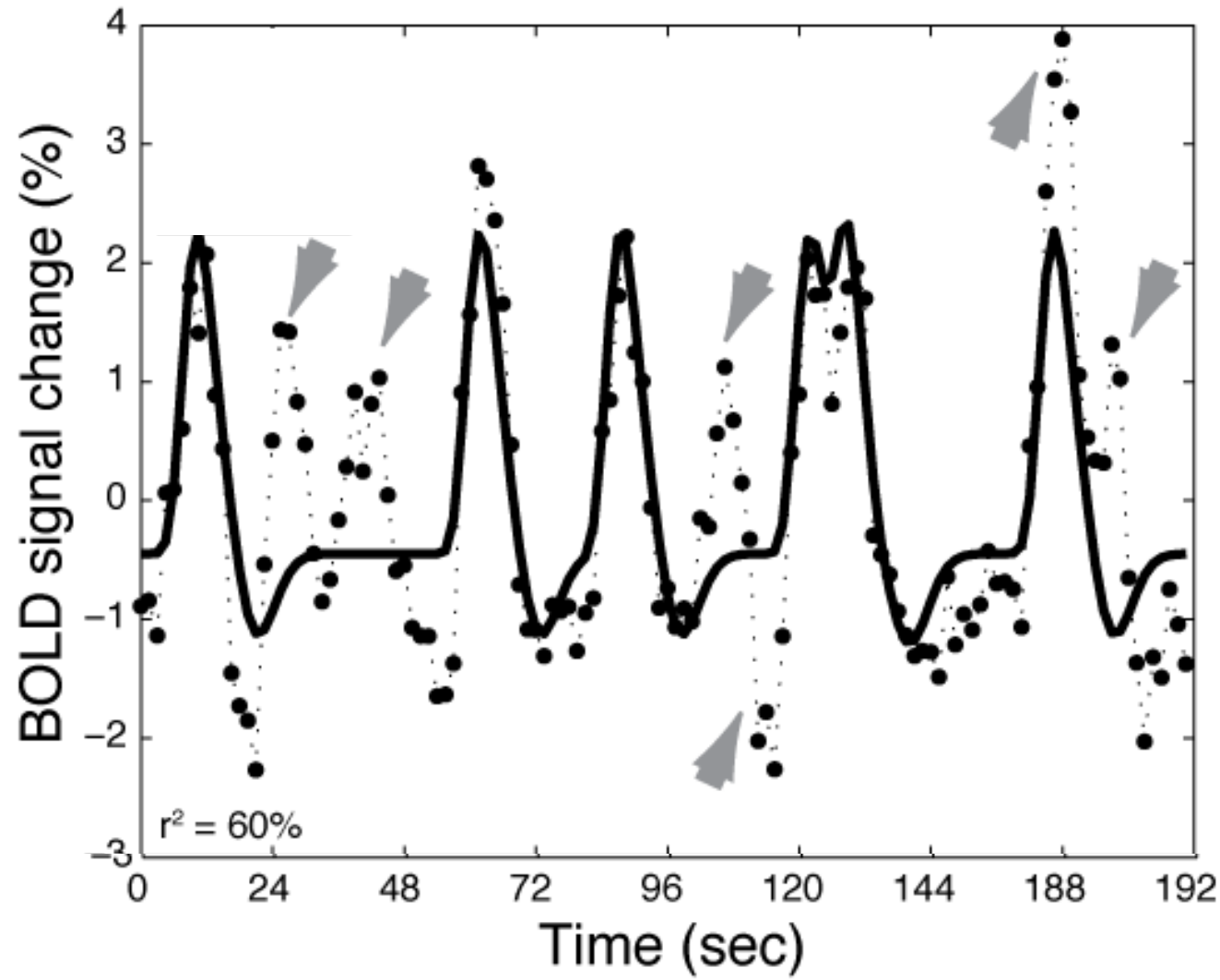


Left hemisphere


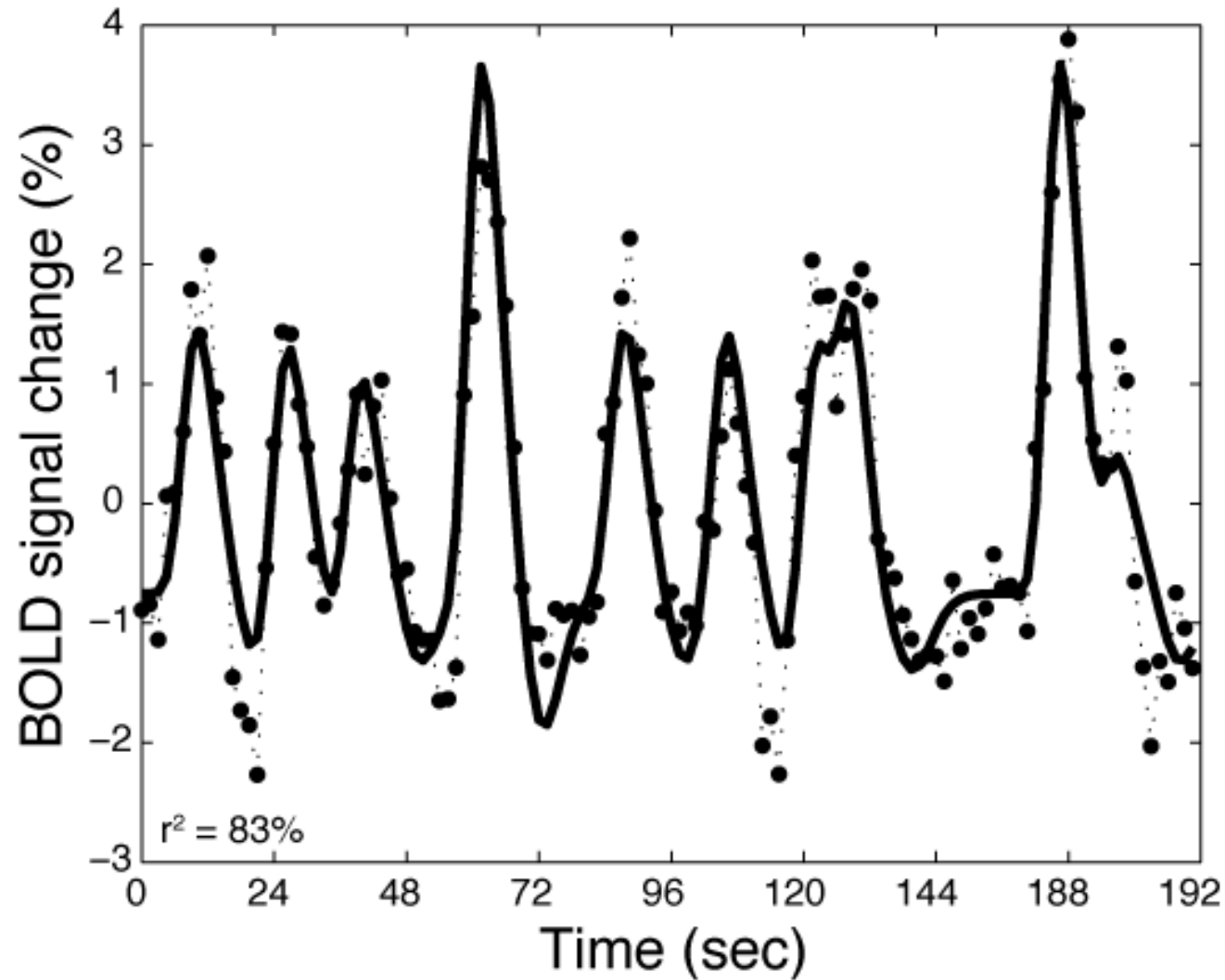


Right hemisphere

# Modeling the time course (1 Gaussian)

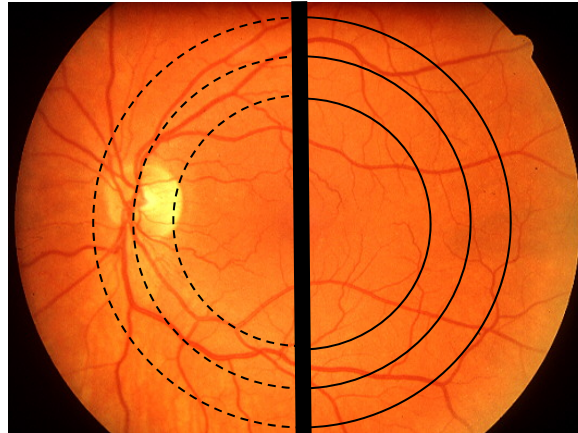


# Modeling the time course (2 Gaussians)

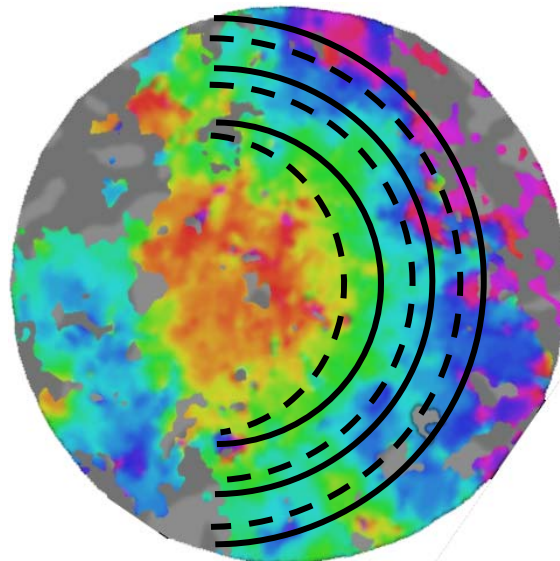


# Achiasmic - Folded representation

Retina



V1



(No clear evidence of an inserted map)

# Early disruption of retinal signals

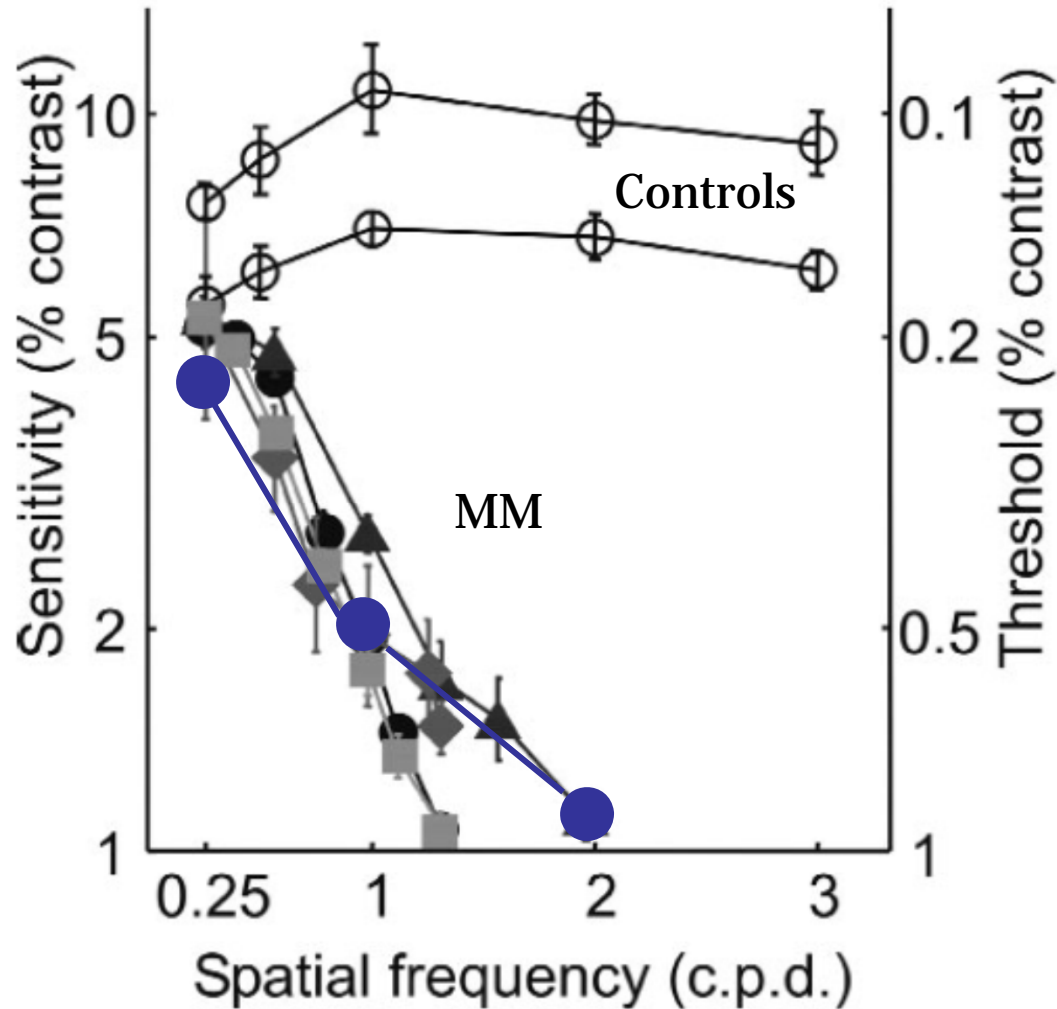
- Cortical maps and white matter tracts following long period of visual deprivation and retinal image restoration. N. Levin, S. Dumoulin, J. Winawer, R. Dougherty and B. Wandell (2010) . **Neuron** V. 65, pp. 21-31
- Long-term deprivation affects visual perception and cortex. Fine I, Wade AR, Brewer AA, May MG, Goodman DF, Boynton GM, Wandell BA, MacLeod DI (2003). **Nature Neuroscience** 6(9) pp. 915-916

## Stem cells, curing blindness



**IMAGES COPYRIGHT MICHAEL MAY**

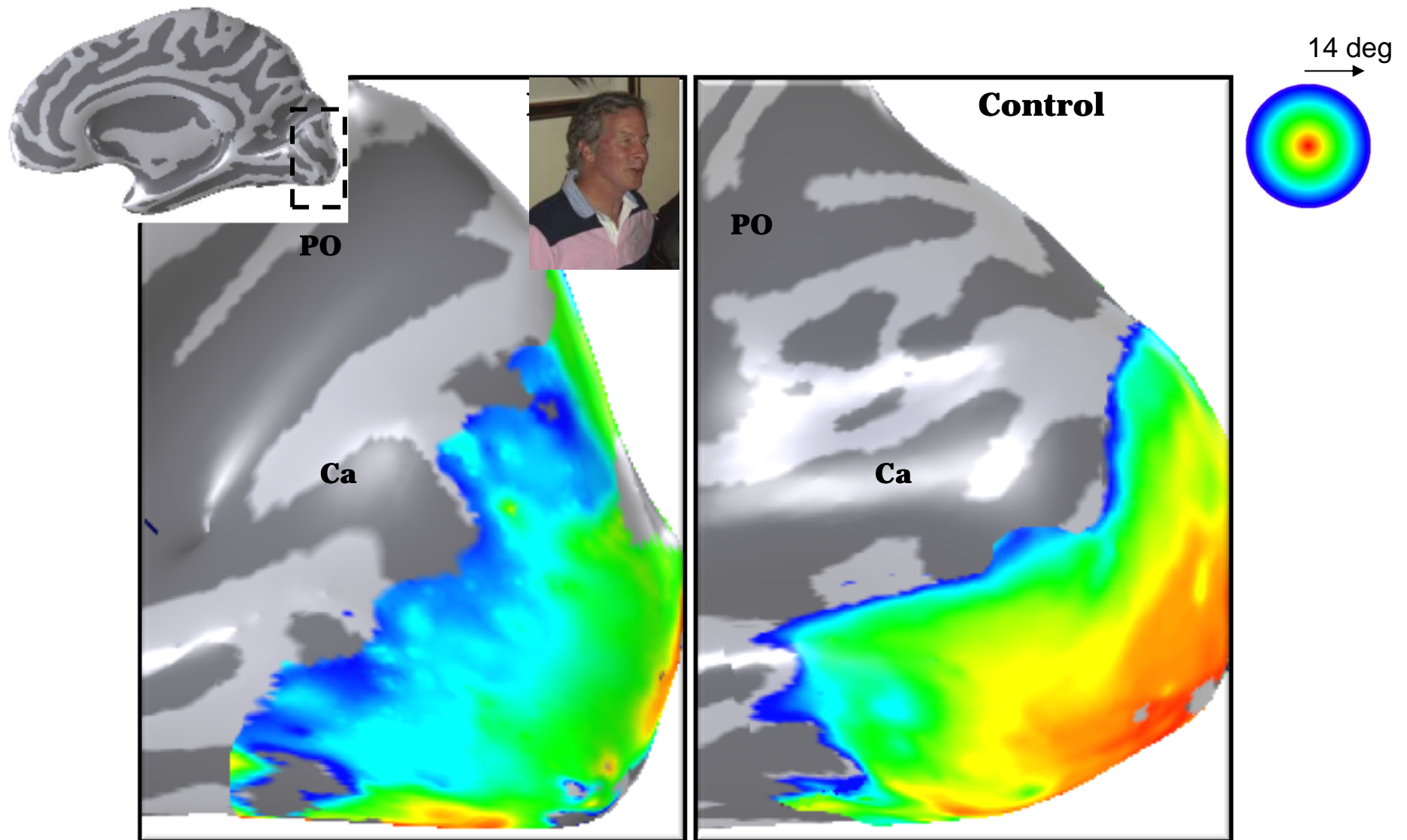
# Contrast sensitivity functions



- Similar to controls at low spatial frequency
- Substantially worse above 0.25 cpd
- Constant for the 7 years following surgery

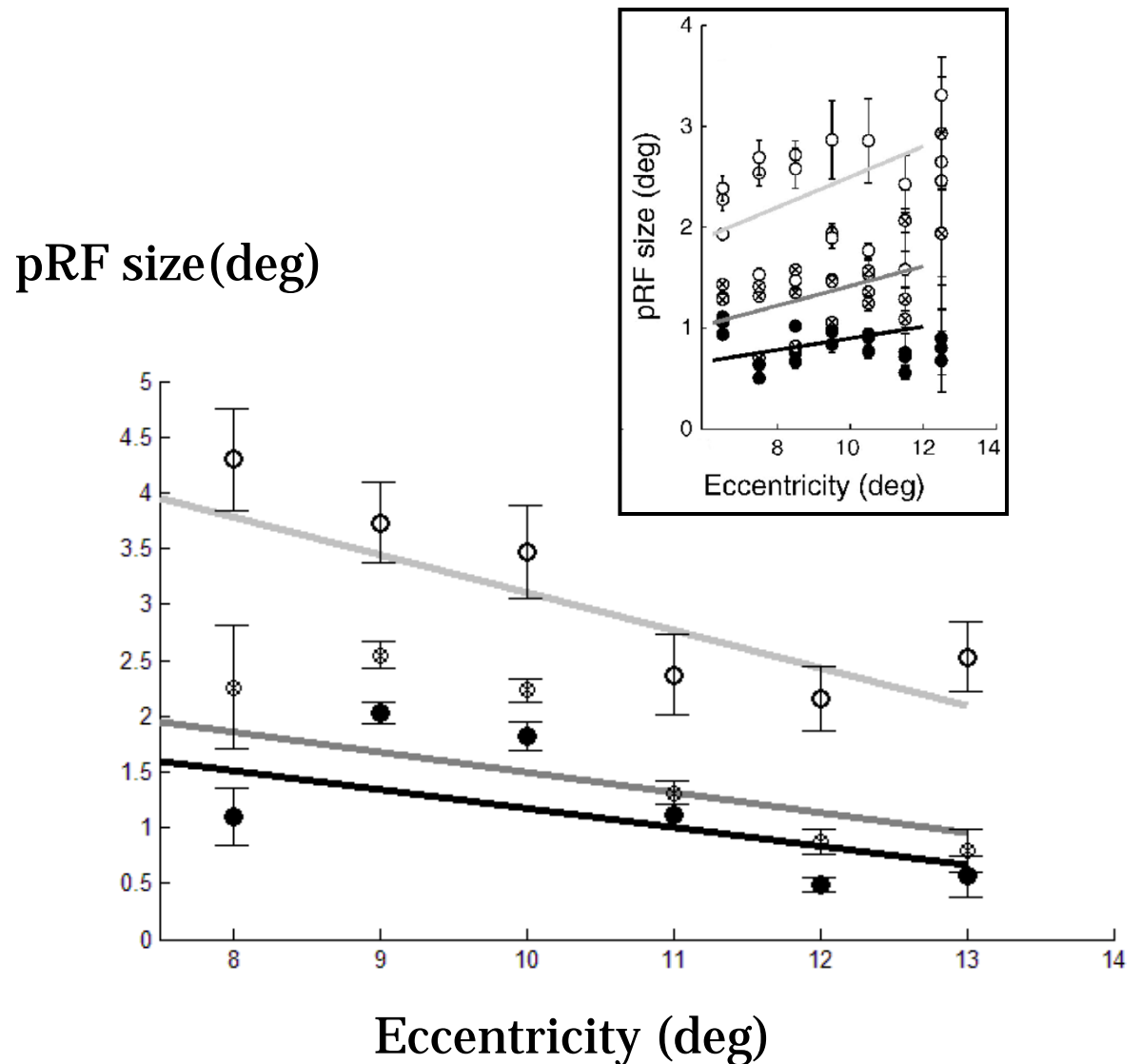
- 5 m
- ▲ 11 m
- ◆ 17 m
- 21 m
- 84 m

# Why can't Mike see? Missing signals to visual cortex



# Hypothesis: MM is selectively missing V1 neurons with small receptive

- Poor spatial resolution in psychophysics
- In typical development, there are many neurons with small receptive fields; these compete with the large receptive field population and extrastriate feedback for synaptic space in V1.
- If the small receptive field neurons are absent in MM's V1, and their synaptic space is given over to these large receptive field neurons, we expect to find large V1 pRF sizes.

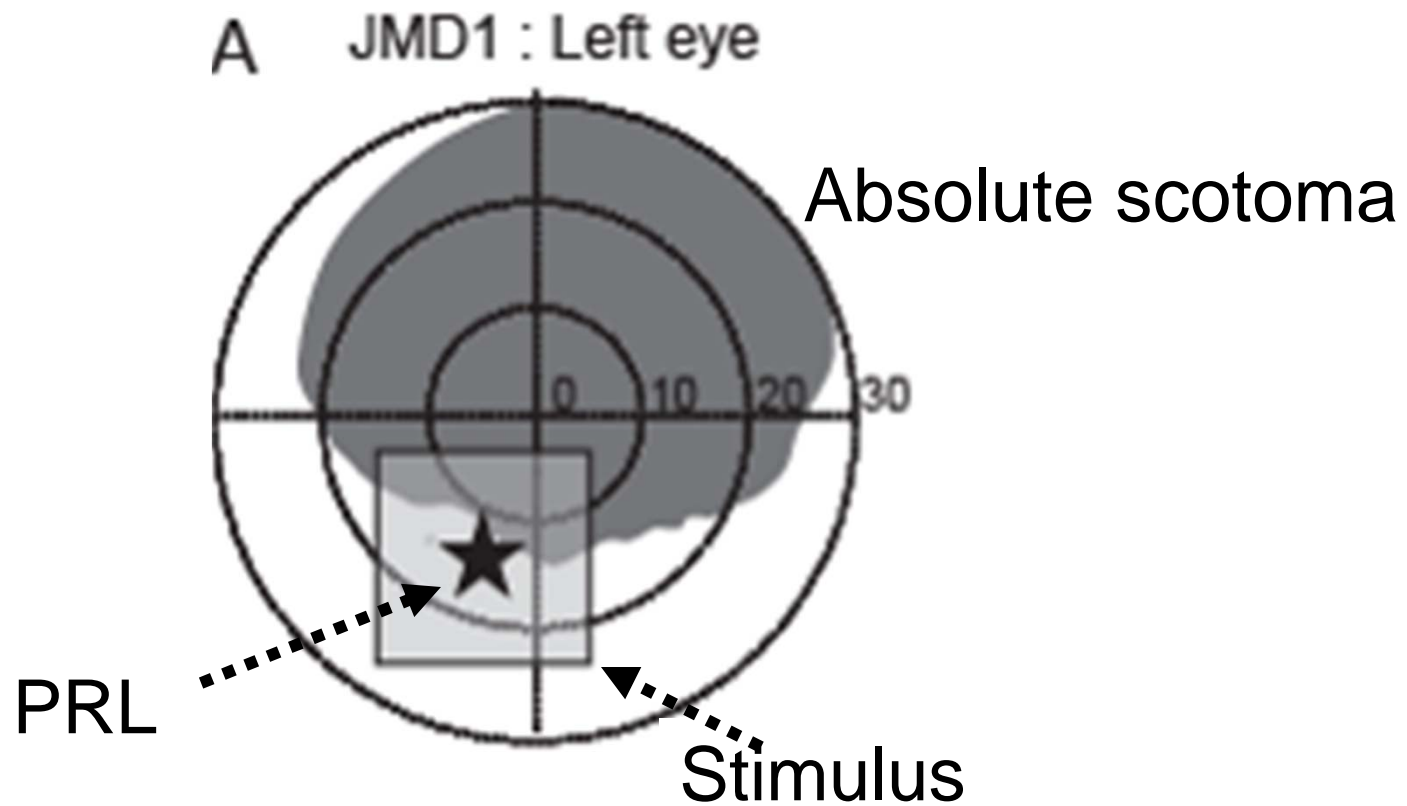


# Retinal dysfunction

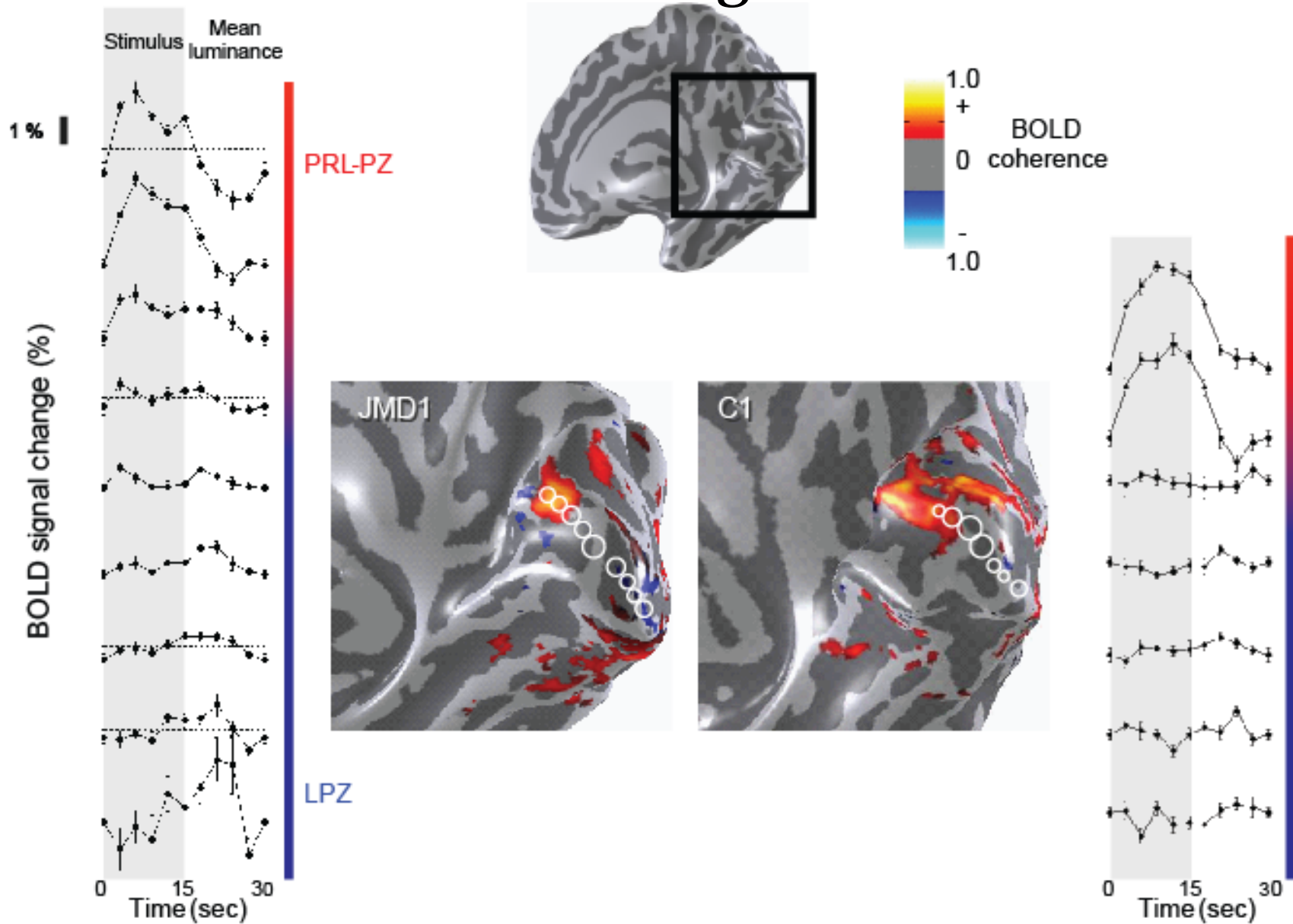
- V1 Projection zone signals in human macular degeneration depend on task, not stimulus. Y. Masuda, S.O. Dumoulin, S. Nakadomari and B.A. Wandell (2008). **Cerebral Cortex** Feb. 3, 2008
- Task-Dependent V1 Responses in Human Retinitis Pigmentosa. Yoichiro Masuda, Hiroshi Horiguchi, Serge O. Dumoulin, Ayumu Furuta, Satoru Miyauchi, Satoshi Nakadomari, and Brian A. Wandell (2010) . **Invest. Ophthalmol. Vis. Sci.** October 2010 vol. 51 no. 10 5356-5364
- Large-scale remapping of visual cortex is absent in adult humans with macular degeneration. Baseler, Gouws, Haak,, Racey Crossland, Tufail, Rubin, Cornelissen, Morland (2011). **Nature Neuroscience**, v 14.
- Lack of long-term cortical reorganization after macaque retinal lesions. Stelios M. Smirnakis Alyssa A. Brewer, Michael C. Schmid, Andreas S. Tolias, Almut Schüz, Mark Augath, Werner Inhoffen, Brian A. Wandell and Nikos K. Logothetis (2005) **Nature**. vol. 435, 19 May
- Plasticity and stability of visual field maps in adult primary visual cortex. B. A. Wandell, S.M. Smirnakis (2009). **Nature Reviews Neuroscience**, doi:10.1038/nrn2741

# Human subjects with deafferented V1: JMD

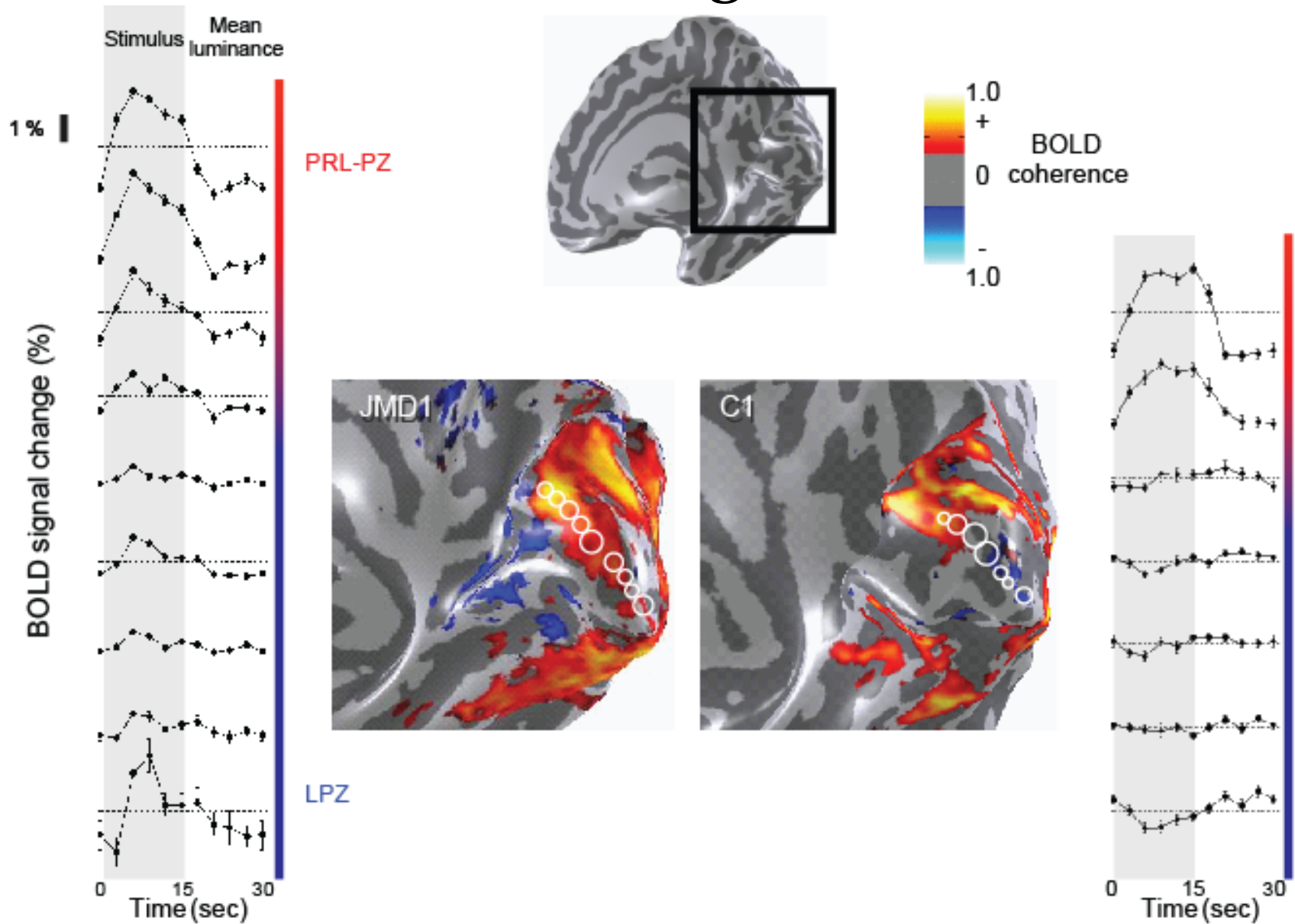
(Masuda et al., 2008)



# Passive: No signal in LPZ



# One-back: Signal in LPZ



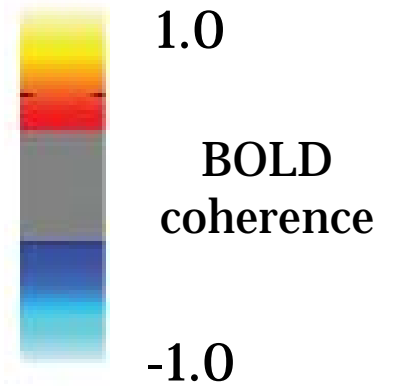
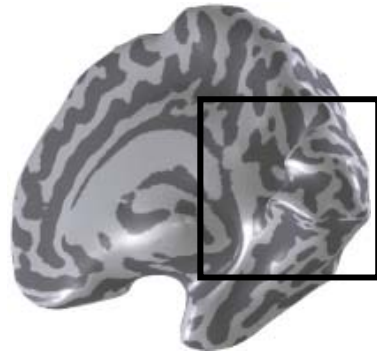
# JMD onset age – (Masuda et al., ARVO poster, Wed.)

Drifting contrast pattern

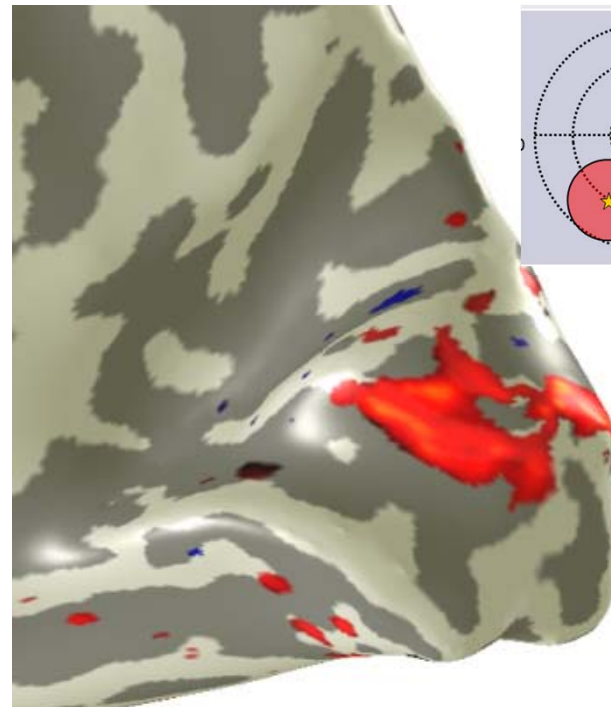
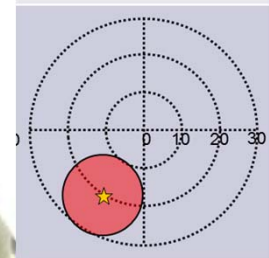
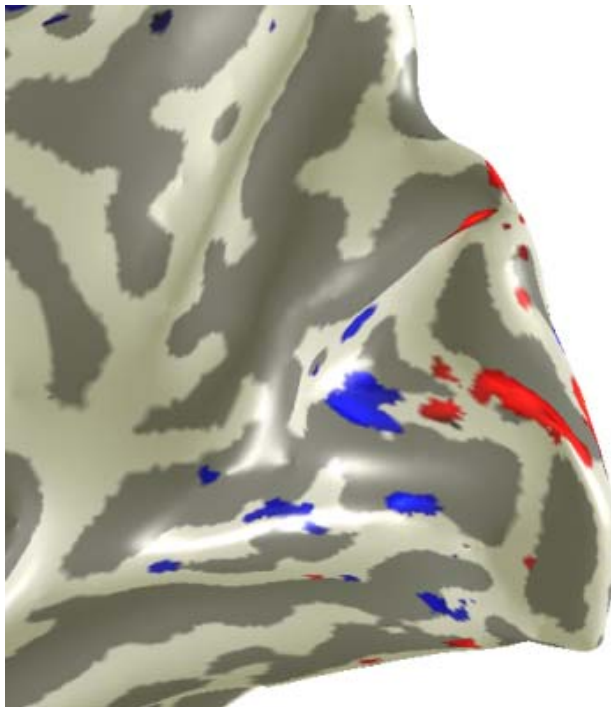
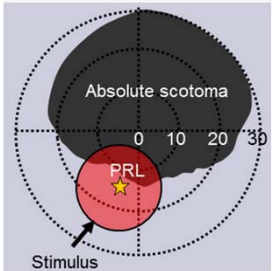
Fixation, no task

Teen age onset  
Current: 32

Acquired JMD



Control



# JMD onset age – (Masuda et al., ARVO poster, Wed.)

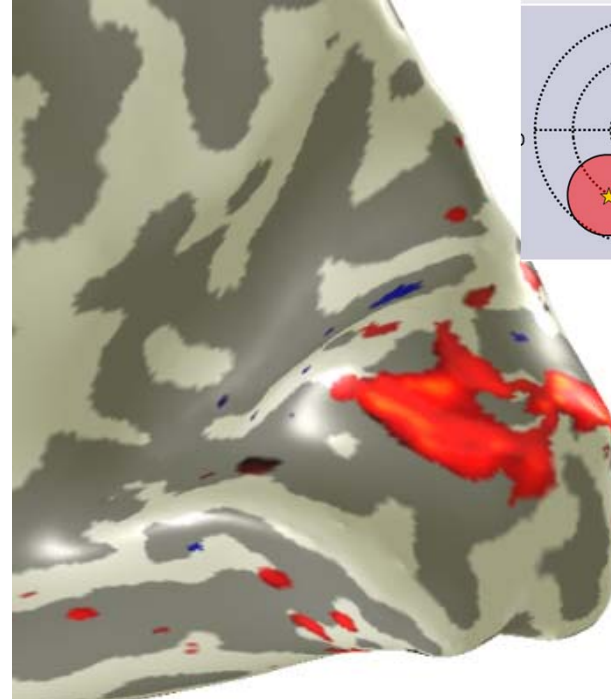
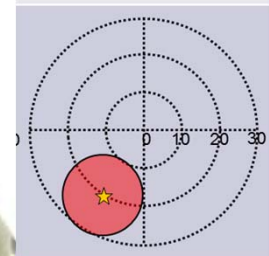
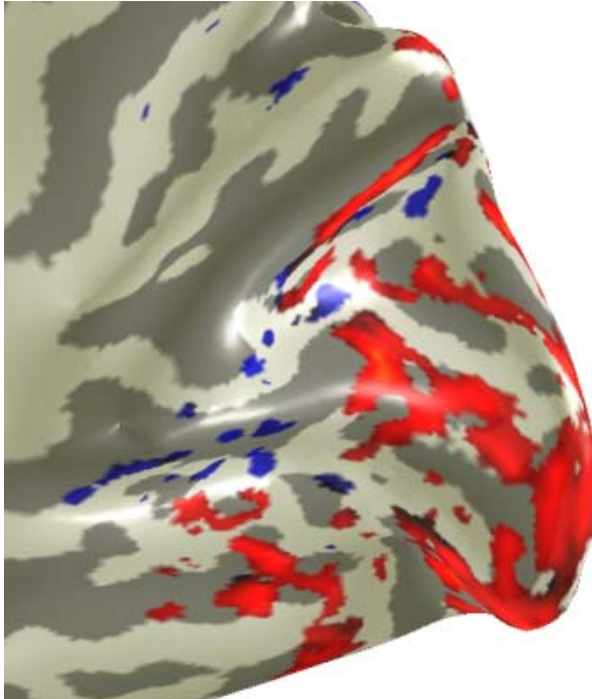
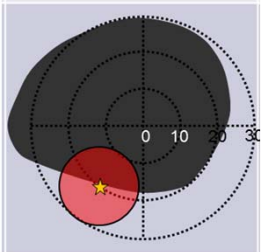
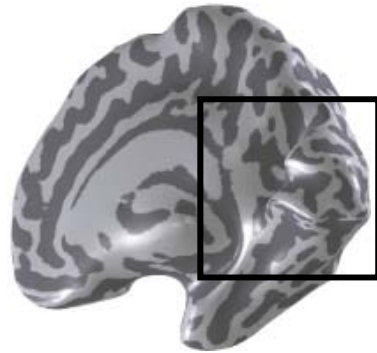
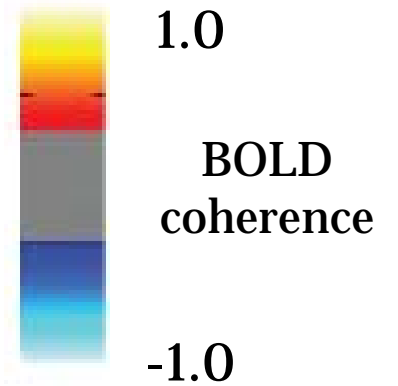
Drifting contrast pattern

Fixation, no task

Birth onset  
Current: 35

Congenital JMD

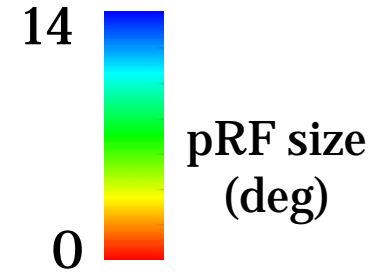
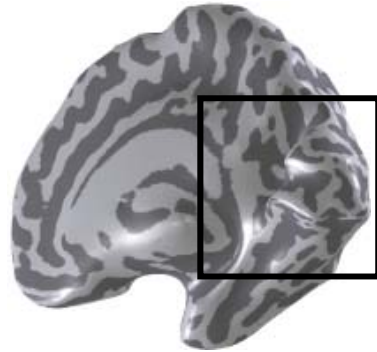
Control



# JMD onset age – (Masuda et al., ARVO poster, Wed.)

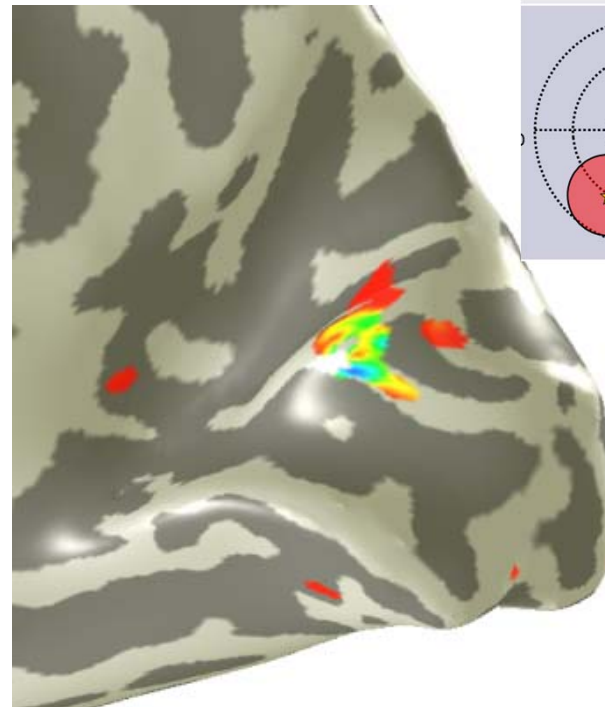
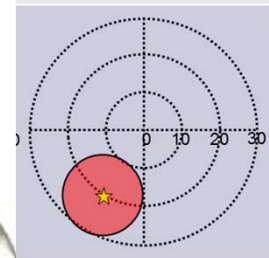
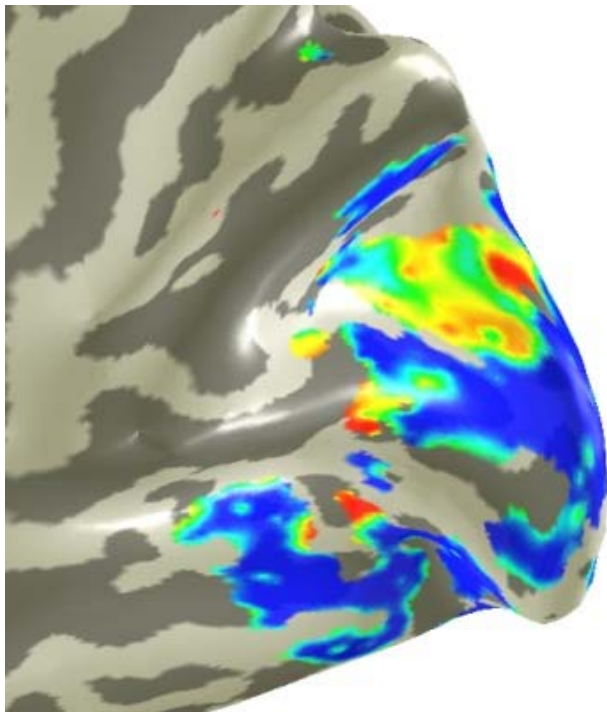
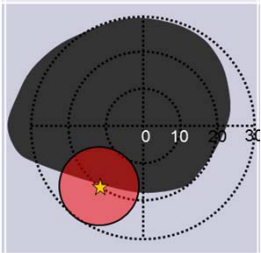
Moving bar

Fixation, no task



Congenital JMD

Control

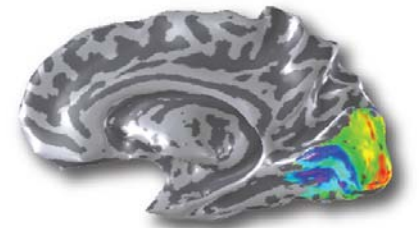

A scenic landscape photograph featuring a large, calm lake in the foreground, surrounded by lush green grass and trees. In the middle ground, a town with red-tiled roofs and a prominent tall, white tower with a red roof is visible. The background shows a range of mountains under a cloudy sky. Two vibrant rainbows are visible, one on the left and one on the right, arching over the town and mountains. A semi-transparent grey rounded rectangle is overlaid in the center of the image, containing the text "Summary and conclusions".

# Summary and conclusions

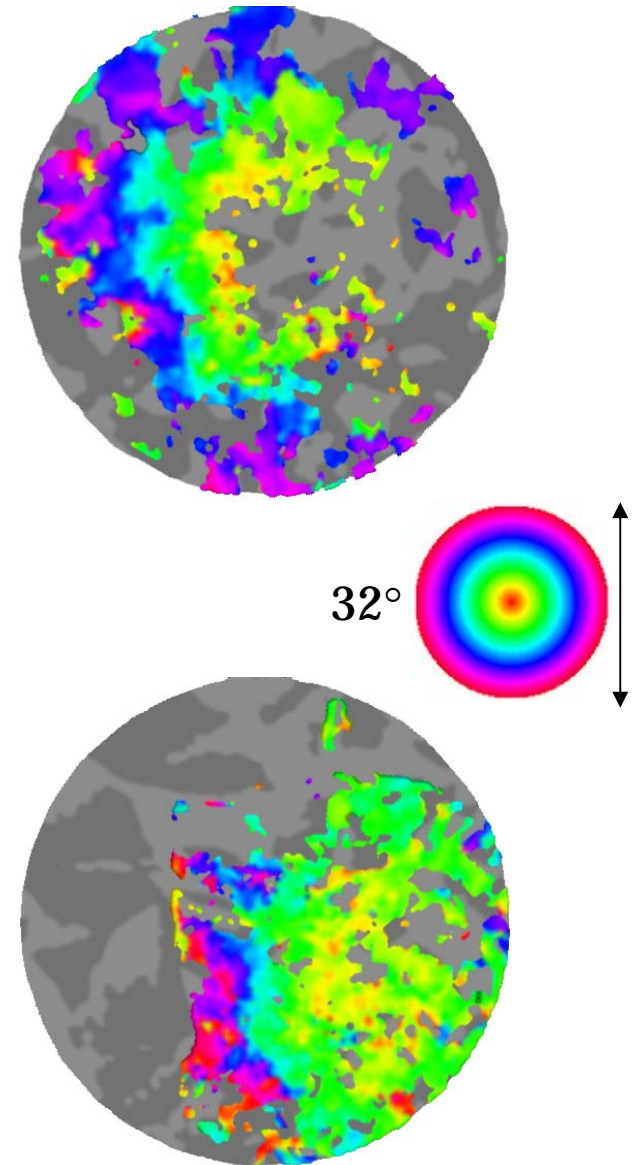
# Plasticity and stability in human visual cortex

- What does functional magnetic resonance imaging (fMRI) reveal about the stability and plasticity of human visual cortex across the lifespan?
- What are the consequences of abnormal development for V1 maps and responses?
- What are the consequences of acquired retinal dysfunctions for V1 maps and responses?



# Summary

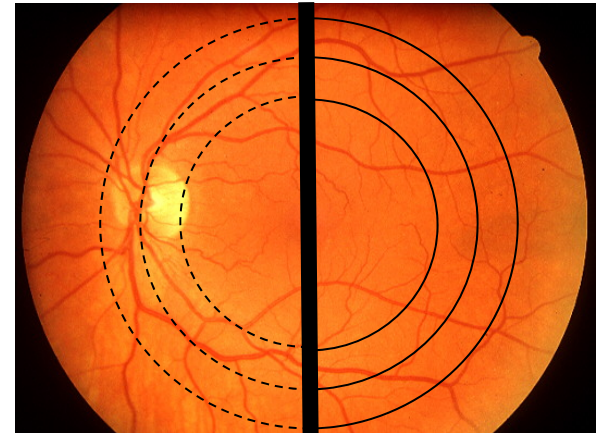
1. In controls, rod signals do not elicit responses in foveal cortex.
2. In rod monochromats, normally foveal cortex is active
3. **A genetic defect that disrupts cone signaling causes a developmental reorganization in visual cortex**



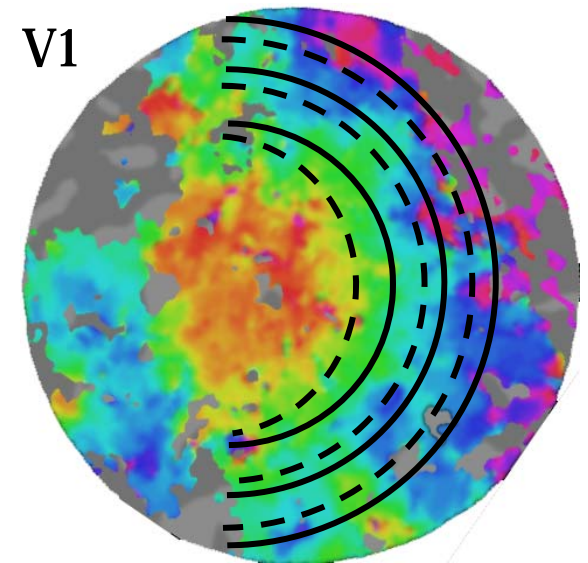
# Summary

1. A genetic defect that disrupts crossing at the chiasm signaling causes a developmental reorganization in visual cortex.
2. **Despite the entirely disrupted maps in V1, the rest of the brain figures out what to do.**

Retina

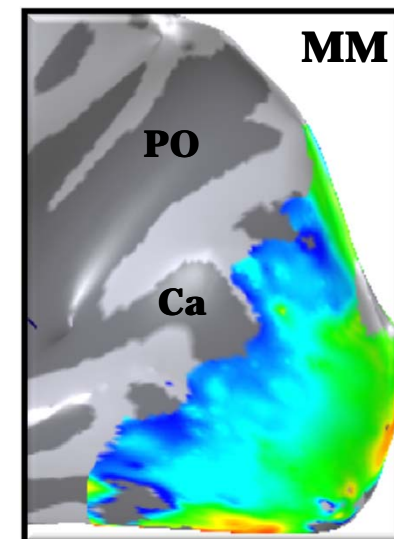
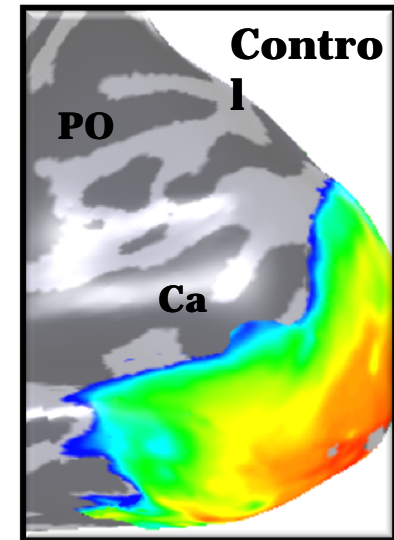


V1



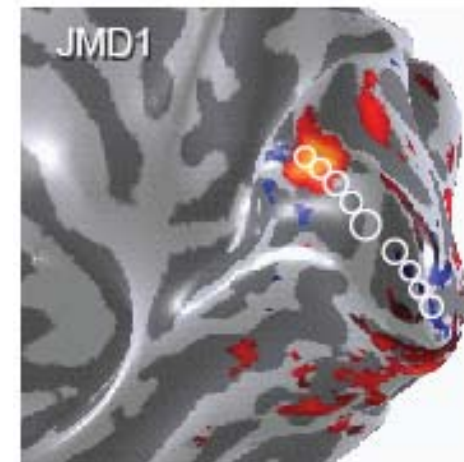
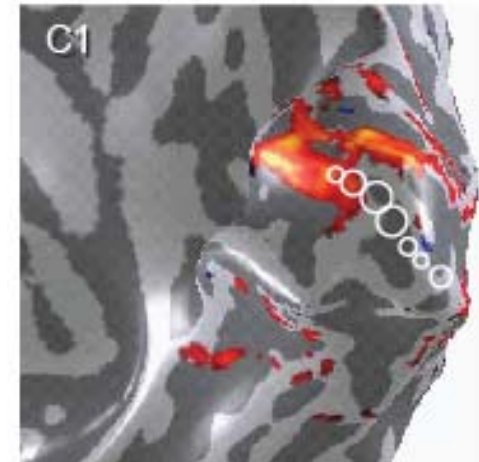
# Summary

1. Eliminating fine resolution images at a young age interfered with normal development. Restoration of the image for the adult did not succeed in producing high quality vision.
2. **The inability to restore high quality vision may be caused by a specific system – the high resolution foveal cells – that is late-developing.**



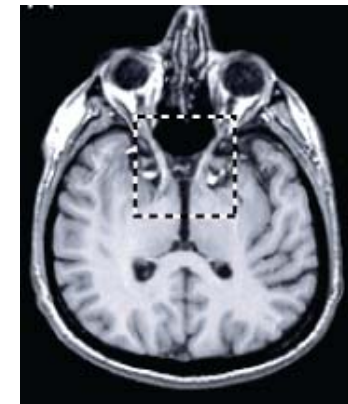

# Summary

1. The fMRI measures individuals with macular (or peripheral) loss are consistent with a stable feedforward signal.
2. Interactions with cortex introduced by task demands, however, are atypical.
3. **The stability of the feedforward signal is a hopeful sign for the viability of retinal prosthetics.**



# Plasticity and stability in human visual cortex

- In congenital and developmental studies, human fMRI measures substantial cortical reorganization
- In adult retinal dysfunction produces
  - A. Stable feedforward mapping
  - B. Atypical cortical interactions







Hiroshi Horiguchi



To Mike:

Thanks from all of us for your advice and support



# Structure and function of human visual cortex following peripheral disruption

Professor Brian Wandell  
Stanford Center for Cognitive and Neurobiological Imaging (CNI)  
Department of Psychology  
Stanford University

These slides can be downloaded from  
<http://vistalab.stanford.edu/~brian>

