

Elsevier allows preprints of articles to be posted on the web.

Because it is difficult to obtain the Neurologic Clinics series on line (for example, Stanford has no subscription) I have decided to make this version available on my web-page for teaching and personal use only.

Thank you for your interest.

Brian Wandell



Functional imaging of the visual pathways

Brian A. Wandell, MD, PhD^{a,*}, Alex R. Wade, PhD^b

^a*Psychology Department, Stanford University, Stanford, CA 94305, USA*

^b*The Smith-Kettlewell Eye Research Institute, 2318 Fillmore Street,
San Francisco, CA 94115, USA*

In 1990, Ogawa and collaborators developed a magnetic resonance technique for imaging oxyhemoglobin levels in the living human brain [1–3]. The discovery of this blood oxygenation level–dependent (BOLD) signal gave rise to the field of functional magnetic resonance imaging (fMRI). Ogawa’s original work demonstrated a BOLD signal in visual cortex [4–6]; of the thousands of fMRI articles published subsequently, at least 10% were concerned with the human visual system.

The field of visual neuroscience was at least a century old in the early 1990s, and many wondered if functional brain imaging could reveal anything not already learned from animal models, especially from electrophysiologic work in primates. Whereas fMRI produces compelling images of the living human brain, the link between the images and the science sometimes can be tenuous, and there is a suspicion in the neuroscience community that there is less to this photogenic newcomer than meets the eye. An analysis of the method was premature within the first few years of its discovery, but human fMRI is now a decade old and already has generated more data on the human visual system than was collected in the previous 100 years. It is time for those in the field of functional neuroimaging to consider some of the method’s successes and limitations.

With this goal in mind, we review findings of interest to a broad range of vision scientists and clinicians, addressing the reader who is not engaged with neuroimaging on a daily basis and who might reasonably ask, “What have you folks done?”

This article is organized into two main sections. Advances in understanding the physiological mechanisms are described in the first section ‘The

Supported by grant no. EY03164 (NEI) from the National Institutes of Health.

* Corresponding author: Psychology Department, Building 420, Stanford University, Stanford, CA 94305-2136.

E-mail address: wandell@stanford.edu (B.A. Wandell).

fMRI signal: Bold'. This understanding is important for those who wish to integrate neuroimaging with other measurement modalities, including electroencephalography (EEG), magnetoencephalography (MEG), and transcranial magnetic stimulation (TMS) and microelectrode recordings. Understanding the basis of the fMRI signal also is important in clarifying the types of experiments that might usefully be addressed by this method. fMRI can provide only a small part of the information needed to understand visual computation [7]; progress will be speeded by understanding properly which questions the method can address effectively.

fMRI has been used to answer fundamental questions about the organization of visual areas in human cortex, as described in the second section, 'Organization of human visual cortex'. One important success has been the description and measurement of multiple visual field maps in human cortex. These measurements have revealed significant similarities and differences between human and macaque visual brain. This topic still is a source of active and heated investigation. These measurements set the stage for experiments designed to clarify stimulus selectivity and computations within the visual cortex, and this article provides a perspective on these developments.

The fMRI signal: BOLD

The main fMRI method is based on the BOLD signal. The neural basis of the BOLD signal must be understood in order to compare it with other types of measurements of neural activity, including single-unit recordings, local field potentials, and electromagnetic scalp recordings (EEG/MEG). The BOLD signal does not measure precisely the same neural activity as microelectrode recordings or EEG, and these differences must be taken into account when integrating measurements across the imaging modalities and building a theory of brain function.

The fundamental principles of the BOLD fMRI signal have been reviewed many times [8–10]. A clear and compact description is in Heeger and Ress [11]. A summary of the final portion of the BOLD signal pathway is as follows: The brain comprises approximately 2% of the total body weight, whereas it receives 12% to 15% of the cardiac output and consumes approximately 20% of the oxygen entering the body [12]. The distribution of oxygen varies across the brain. Gray matter consumes approximately four times more energy than white matter. Regions of the cerebral cortex that are "physiologically active" require additional glucose and oxygen for metabolism. The vasculature delivers these materials to the brain, but the increased oxygen supply and consumption do not match precisely. The net result is that active cortical regions have a higher blood oxygen level than regions at rest [13]. BOLD fMRI measures time-varying spatial maps of this oxygen concentration.

The BOLD signal is derived from the effect of the oxygenated blood on the local magnetic field (see box for definitions of the magnetic properties of various materials). In brain the local magnetic field measurement depends mainly on signals emitted by the hydrogen nuclei that are abundant in the water molecules of the brain. Applying a radio-frequency pulse excites these nuclei away from their resting state. The MR scanner measures the decaying sum of the emitted radio frequency energy as these atoms relax to a low energy state. The precise signal decay rate (characterized by the variable $T2^*$) is affected by the presence of inhomogeneities in the magnetic field. The degree of the local magnetic field inhomogeneity depends on the relative amounts of oxygenated and deoxygenated blood. In these two states, blood has different magnetic properties: deoxyhemoglobin introduces a much greater inhomogeneity into the nearby magnetic field than oxyhemoglobin. Hence, increasing the local oxyhemoglobin concentration increases the local signal.

Why is there a mismatch between the supply and consumption of blood oxygen? Blood supplies two essential ingredients for brain metabolism: oxygen and glucose. The increased glucose supply matches the incremental consumption precisely; but the additional oxygen exceeds the local consumption [13,14]. This causes a net increase in the local oxyhemoglobin that is measured in the BOLD signal.

Why does neuronal activity produce an excess of oxygenated blood? One explanation is that the vasculature delivers a ratio of oxygen and glucose that is used by an aerobic process. Demand for blood, however, is driven by aerobic and anaerobic glucose metabolism, which is located mainly in the astrocytes. The anaerobic processes use far less oxygen to metabolize the same amount of glucose, resulting in a surplus of oxyhemoglobin [15]. Based on this hypothesis, the BOLD signal is not uniquely a measure of neural activity. Instead, the excess oxygen measures in part the local demand for anaerobic glucose metabolism. An alternative hypothesis is that oxygen extraction matches the metabolic needs, and the excess is a result of an inefficient delivery process [16,17]. Based on this hypothesis, the oxygenation level is tightly coupled to neural activity, and the anaerobic process of

Susceptibility. A dimensionless quantity describing the contribution made by a substance, when subjected to a magnetic field, to the total magnetic flux density present.

Paramagnetic. Material that is slightly attracted to a magnet (low positive susceptibility).

Diamagnetic. Material that is slightly repelled by a magnet (low negative susceptibility).

Ferromagnetic. Material that is strongly attracted to a magnet (high positive susceptibility).

the astrocytes represents only a small amount of energy [18] supplied by existing reserves [19]. The effort to determine if the relationship between neural signals and oxygen supply is tightly or loosely coupled has led to vigorous discussions in a field labeled “neuroenergetics” [20]. The resolution of this discussion will have significant implications for how the fMRI signal fits into quantitative models of the neural processing.

Whether or not it is loosely or tightly coupled to neural activity, the BOLD signal is an indirect measure of neural activity. This bothers some investigators who deride it as inferior to microelectrode measurements. This criticism seems flawed for two reasons. First, indirect measures have been used successfully for many years to infer brain mechanisms and computations in neurology and vision science [21–23]. Young knew little about transduction when he deduced the presence of three cone types [24]; Helmholtz knew little about the retina when he used perceptual measurements to deduce the properties of the cone mosaic [25]. The BOLD signal can be a useful view of brain activity that provides additional insights beyond other methods. Second, the criticism is based on a view of microelectrode measurements as a standard without serious flaws (discussed later).

Action potentials and the BOLD signal

Which aspect of neural activity couples most closely with the BOLD signal? Researchers have tried to answer this in a variety of ways. For example, one group assumed that the BOLD signal is related directly to action potentials [26]. They then analyzed a set of neuroimaging data in visual area MT (a motion-responsive region of the brain described more fully later) and concluded that a 1% increase in BOLD signal represents an average of nine additional spikes per second. Using this approach, another group suggested that in primary visual cortex (V1), a 1% increase in BOLD signal represents a mere 0.4 additional spikes per second [27]. Such efforts to couple BOLD signal modulation with spikes were useful in confronting in more detail what is measured by these two methods, although we suspect the conclusions will not stand.

The fundamental problem in trying to connect the BOLD signal with spikes is evident in direct experimental measurements of cerebral blood flow and electric signals made in the same preparation [28–31]. Taking advantage of several special properties of rat cerebellar cortex, Mathiesen et al modulated the spiking activity from the Purkinje cells, the principal cerebellar cortex output neurons. They used climbing fiber stimulation to produce sustained activity and modulated the activity using signals on the parallel fibers (Fig. 1A). While doing this, they measured the cerebral blood flow (Fig. 1B). They found that suppression of the Purkinje cells spikes was accompanied by an increase in the CBF. The investigators concluded that the increase in cerebral blood flow caused by the parallel fiber stimulation measures all synaptic excitation, even if the excitation acts through

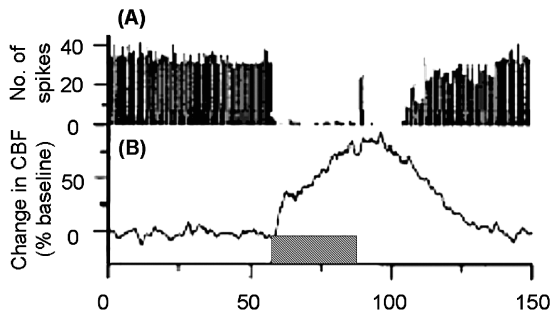


Fig. 1. The relationship between spiking and blood flow measured in rat cerebellar cortex. (A) Purkinje cell spike firing activity almost vanished after the first 1 to 3 s of inhibitory stimulation from the parallel fibers, and spontaneous firing did not return to basal levels until 19 to 25 s after the end of stimulation. (B) Cerebral blood flow increased during inhibitory stimulation, continued to increase for 5 to 10 s after the end of stimulation, and reversed to baseline after 40 to 50 s. Duration of inhibitory input indicated by shaded block on lower axis. (See Fig. 3 in Mathiesen et al [28]) (*Adapted from Mathiesen C, et al. Modification of activity-dependent increases of cerebral blood flow by excitatory synaptic activity and spikes in rat cerebellar cortex. J Physiol 1998;512:555–66; with permission.*)

inhibitory neurons to reduce the net number of action potentials on the large and numerous Purkinje cells. If this result is generalized to the visual cortex, the conclusion is that the spiking activity of the main output neurons (pyramidal cells) is not the main determinant of the BOLD signal [30].

The effort to relate action potentials and fMRI signals is a reminder that cortical microelectrode sampling biases are not well understood, and that these biases may differ from other methods. It is likely that microelectrodes measure large neurons (cortical pyramidal cells) rather than the smaller interneurons [32]. The BOLD signal may reflect a different sampling bias, perhaps including a higher proportion of the synaptic potentials from small cells. If this is so, the conclusions drawn from microelectrode recordings and BOLD signals may diverge [33–35].

Differences between the measurement modalities do not imply that one is inferior. The difference in sampling bias of the electric signals should be used to better understand the biases of both methods and to design computational models that account for these differences. The next section discusses ways in which electric activity is measured.

Local field potentials and the fMRI signal

Most theorizing about the brain centers on action potentials because of their crucial role in neural communication over significant distances. For the same reason, the previous section focused explicitly on the relationship between the fMRI signal and microelectrode measurements. Microelectrodes, however, measure a broader spectrum of electric activity than just

action potentials. The microelectrode output is a continuous time-varying voltage, and action potentials are measured by extracting a portion of the signals from this voltage. In recent years, there has been increasing interest in measuring other components of this time-varying electric signal with respect to neural function and behavior.

The separation of the electric signal into different frequency bands makes good sense when comparing microelectrode signals with the fMRI signal. The experiments by Mathiessen et al suggest that the metabolic energy needed to maintain postsynaptic ionic gradients is a dominant factor in blood flow measurements. The time course of these postsynaptic signals is much slower than the time course of an action potential; spikes last from 0.5 to 1.5 ms, whereas postsynaptic potentials often last 100 ms or more. Consequently, the postsynaptic voltages are likely to be represented predominantly in the relatively slow temporal components of the electric signal (10–300 Hz). The electric activity from the action potentials is predominantly in the higher temporal frequencies (eg, 300–3000 Hz). Examining the signals in these different bands is instructive as to the different components of the cortical signaling mechanisms.

In an empiric tour-de-force, Logothetis [36] simultaneously measured the local electric signal and fMRI signal in anaesthetized macaque visual cortex. These experiments were designed to analyze which component of the microelectrode electric signal best predicted the BOLD response. They found a great deal of variability across different recording sites. On the whole, the fMRI signal follows the lower temporal frequency components of the electric signal better than the higher temporal frequency components. Again, these measurements suggest that the BOLD and microelectrode measurements sample different aspects of the neural signal.

Spatial precision and signal-to-noise ratio of the fMRI signal

Beyond the measurement method itself, which is remarkable for the simultaneous recording of electric and MR signals, perhaps the most important observation from the Logothetis group is the wide variability across different recording sites. What might be the source of the spatial variation across recording sites? In general, what is the spatial concordance between microelectrode and fMRI signals?

A disappointing assessment of the spatial agreement comes from experiments performed in macaque somatosensory cortex using a 1.5 T magnet and an echo-planar imaging (EPI) pulse sequence [37]. These investigators identified somatosensory maps in areas 3a, 3b, 1, and 2, using fMRI and microelectrode recordings. They identified these maps using a block design in which stimulation of a location was alternated with no stimulation. They found that approximately half the response fields overlapped between the two measurement methods, but that in half the

cases the fMRI signal was displaced from the electric signal, sometimes by as much as a centimeter.

The spatial discordance between fMRI and electric measurements is not always large. In an fMRI study of the locations and properties of macaque visual areas, Brewer et al [38] used a 4.7 T magnet and an EPI sequence. The boundaries of these visual areas have been mapped many times using electric single-unit recording techniques, thus their positions with respect to major sulcal landmarks are well established. For example, areas V1 and V2 contain a map of the visual field. The lower vertical meridian representations from these two areas abut one another, tracing a path along the peak of the operculum before descending into the lunate sulcus. Retinotopic mapping using fMRI showed that the boundary of V1/V2 fell close to this expected location (Fig. 2). Such close agreement is not expected if BOLD and electric signals were separated routinely by 1 cm.

Harrison et al [39] provide an excellent study of the limitations of spatial localization of the neural and vascular signals. In chinchilla auditory cortex, they measured intrinsic optic images based on hemodynamic responses, electric activity, and anatomic measurements of the spatial distribution of the vasculature. They compared the size of the intrinsic optic signals with the spatial distribution of veins and arteries by creating a corrosion cast of the vasculature (Fig. 3). The distribution of veins and arteries was uneven and correlated with the strength of the optic images. They concluded that the spatial distribution of the vasculature defines much about the

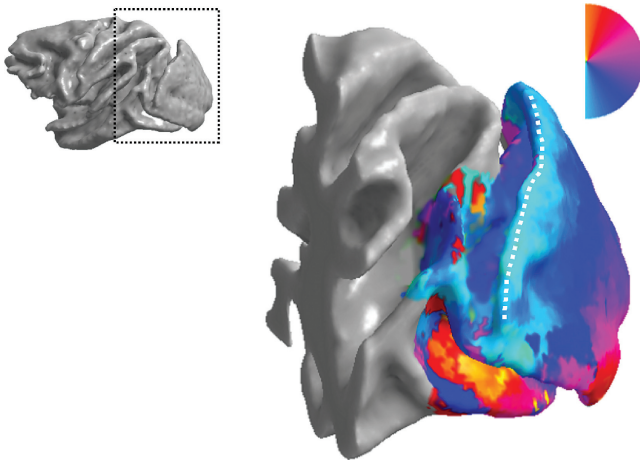


Fig. 2. The preferred angular representation in macaque area V1 measured with fMRI. The entire hemifield is represented in area V1 on the operculum of macaque visual cortex (represented by the color map from red through cyan). The reversal of the visual field representation at the lower vertical meridian, indicated at the upper edge of the operculum, occurs at the boundary between V1 and V2. The location of this field reversal is spatially concordant with electrophysiologic studies of the V1/V2 boundary.

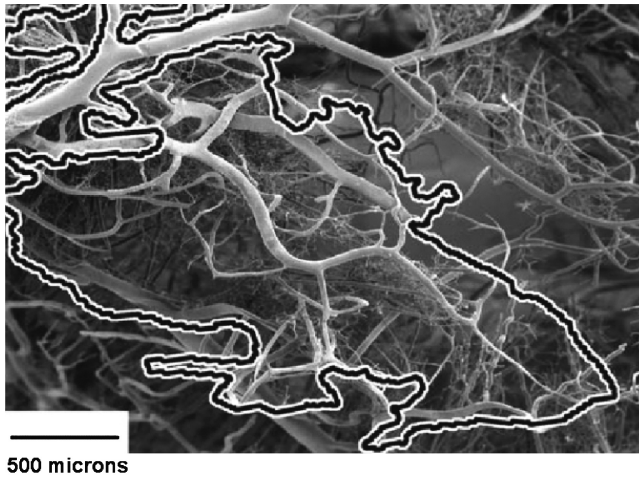


Fig. 3. Regions of high intrinsic optic signal measured in chinchilla auditory cortex superimposed on a corrosion cast of the capillary network. The nonuniform spacing of the vasculature correlates with the location and level of the functional signal measured in related experiments. (From Harrison RV, et al. Blood capillary distribution correlates with hemodynamic-based functional imaging in cerebral cortex. *Cereb Cortex* 2002;12:225–33; with permission.)

spatial pattern and overall responsivity of hemodynamic-based brain imaging studies, such as fMRI. The uneven distribution influences the amplitude and statistical reliability of such hemodynamic-based cortical signals.

A current working hypothesis is that the density of the capillary bed depends on the general excitation levels of the neurons in a region [40]. It is plausible that the primary sensory areas have larger and more reliable functional signals than less active cortical regions. This raises the possibility that the localization of signals might differ significantly across the brain.

Related measurement methods: PET, MEG, EEG, and TMS

The relationship between fMRI and electric activity has been a prominent question in the literature; a comparably detailed analysis of the relationship between fMRI and other neuroimaging methods has yet to be undertaken. Specifically, positron emission tomography (PET), recordings of electric scalp potentials (EEG), and recordings of magnetic fields at the scalp (MEG) all measure some aspect of the neural response. The relationship between the underlying signals of these methods must be resolved, however, before the strengths of each technology can be combined confidently.

PET and fMRI are the most similar measurement methods. PET images are spatial maps of the radioactive tracers introduced into the subject's blood stream. The delivery of these tracers to different brain locations depends on the same basic mechanisms as the BOLD signal, and studies of the

basis of the PET signal clarified the way in which neural activity influences cerebral blood flow, cerebral blood volume, and blood oxygenation [13,41]. Despite these similarities, PET and fMRI do not measure identical aspects of the vasculature. In the early days of fMRI, members of the PET community often challenged this technology, asking if fMRI could measure signals from the fine capillaries that diffuse the radioactive materials. The high-resolution measurements of retinotopic maps (described later) provided an answer for visual cortex. In this primary sensory area, it seems that the fMRI signal provides high spatial resolution information, but there is no definitive answer for many other brain regions [7].

There is even less information about the relative contributions from different neural populations that contribute to the electromagnetic scalp potentials. Combining measurement from these modalities has been of great interest because the time resolution of fMRI and PET is poor, whereas that of MEG and EEG is excellent. Combining fMRI and EEG/MEG might provide a noninvasive unified view of human brain activity with high spatial and temporal resolution [42,43].

To combine fMRI and electromagnetic signals meaningfully, a deeper understanding of the neural mechanisms that drive these neuroimaging modalities is needed. The EEG and MEG reflect the electric and magnetic fields, respectively, resulting primarily from synaptic transmembrane currents in neuronal dendrites [44]. Eighty-five percent of cortical neurons are pyramidal cells, and these are the cells that dominate these field potentials at the scale [45]. The neural basis of the fMRI signal has not yet been resolved, but it seems that blood flow measurements do not necessarily follow the responses of the largest cells [28]. It is possible that the EEG/MEG and fMRI signals weight the signals from various cell populations in different proportions, and both methods may differ from microelectrodes. Consequently, the spatial concordance of the EEG/MEG and fMRI signals sometimes may be poor.

It is optimistic to think that simultaneous measurement of these two types of signals can provide the spatial resolution of fMRI and the temporal resolution of EEG/MEG, and there is a place for optimism. Further experiments analyzing the issue can be a valuable contribution and particularly helpful to those with a less optimistic nature.

Organization of human visual cortex

The discovery and analysis of the cortical visual areas is a major accomplishment of visual neuroscience. The number, size, and locations of these areas are important topics for continuing experimental studies of the human brain. The computational roles of these visual areas remain a key issue in vision science [23,46].

In animal models, several criteria identify visual areas: (1) the presence of retinotopic map of the visual field; (2) regularities in the receptive field

properties of the neurons; (3) coherent projections between cortical regions; and (4) cellular architecture, including features such as the thickness of the layers and general features of the cortical region. When all the criteria are met, there is no doubt that a visual area has been well and truly identified [47,48]. After 30 years of exploration of macaque visual cortex and the availability of multiple experimental criteria, consensus has been reached on how to partition large regions of posterior visual cortex (eg, V1, V2, and V3). The main differences between investigators concern the partitioning of relatively anterior regions of macaque cortex where the retinotopic maps are poorly defined [49].

In the human brain, fewer criteria are available to identify visual areas. The main data for partitioning visual areas are fMRI measurements of visual field maps, occasionally augmented by measurements of response selectivity, such as a particular sensitivity to color, motion, or object form. There are limited data on connectivity and cellular architecture, and there are virtually no data on neuronal receptive fields.

Despite these limitations, there has been progress in identifying certain visual areas based on visual field maps derived from fMRI. In particular, there is agreement on the locations and properties of several visual areas near the occipital pole; there also is agreement on the location and retinotopic organization of a motion-selective area located on the lateral occipital surface. The next section describes the main properties of these visual areas, including their location, size, and retinotopic organization.

Areas of agreement

Retinotopy measurements

In humans, visual areas are determined principally by measuring distinct visual field maps. Fine resolution measurements of these maps often are made using a method developed by Engel [50,51]; the methods are described and reviewed in many articles [7,52–55]. Briefly, the method is based on using simple stimuli that change position over time. The maximum response in cortex is mapped and an association is formed between the stimulus position and the maximum response at various cortical locations. The relationship between the changing stimulus position and the fMRI time series offers detailed insights into the organization and responses [52,54,56–60].

The simplest and most robust retinotopic measurements capture the distribution of activity from fixation (fovea) to periphery. This aspect of retinotopy can be measured using a simple set of flickering rings that are presented at increasing eccentricity over time (Fig. 4A). In summarizing the measurements, the ring eccentricity that evokes the largest fMRI response is coded by a color overlay on the brain. In Fig. 4B, a view of an inflated brain, with the sulci brought to the surface, is shown. By inflating the brain this

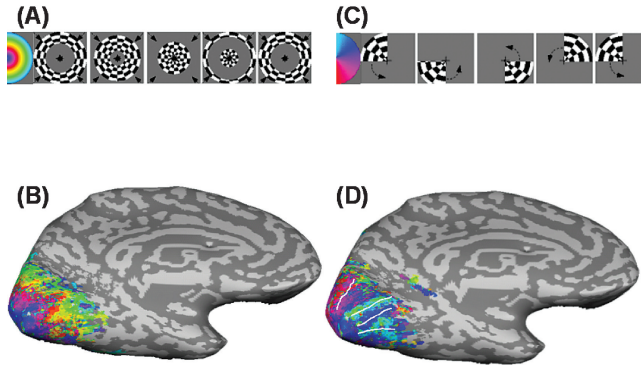


Fig. 4. Retinotopic organization in posterior occipital lobe of the human brain. (A) Expanding ring stimulus. (B) Inflated human brain with a color overlay that indicates the eccentricity at which the ring drives each cortical location most powerfully. (C) Rotating wedge stimulus. (D) Inflated human brain with a color overlay that indicates the angle at which the rotating wedge drives each cortical location most powerfully.

way, it is easier to see the full pattern without interference from the sulcal folds. Software tools for brain inflation and related visualization can be downloaded from the Internet (<http://white.Stanford.edu/~brian/mri/segmentUnfold.htm>) or purchased from private companies (<http://www.brainvoyager.de>).

From many experimental measurements, the authors have found a simple function that relates position on the cortical surface (p) to visual field eccentricity (v) [52,61]

$$v = \exp(sp + 2.3)$$

The position parameter, p , is specified in millimeters and the origin ($p = 0$) is set to the location that represents 10° of visual eccentricity. For the eccentricity measurement, position is measured along lines of constant angular representation. The scale parameter, s , is approximately 0.35 for humans. For macaque, the same formula applies, but the scale parameter is changed from 0.35 to 0.65, reflecting the smaller size of macaque V1 [38]. The authors have evaluated the function over the range of approximately 1.5° to 25° eccentricity.

To identify visual areas, the eccentricity measurements must be combined with the angular dimension of the visual field. The angular dimension can be measured using a wedge stimulus that rotates slowly over time (Figs. 4C,D). This measurement is important because the angular representation reverses direction at the boundaries between several early visual areas.

The angular representation is represented in more detail in Fig. 5. Fig. 5A shows a schematic representation of the angular retinotopy that is expected in a series of visual areas around the calcarine sulcus. Color indicates the most effective stimulus angle representation at each cortical location. V1 is

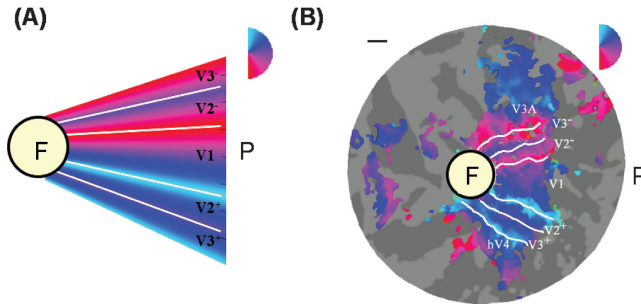


Fig. 5. (A) Schematic of the organization of several retinotopic areas on a flattened representation of the occipital lobe. (B) Flattened representation of occipital cortex, centered at the occipital lobe. The region towards the right shows the medial cortex surrounding left calcarine cortex, and the region towards the left shows the lateral occipital cortex. Up and down are dorsal and ventral, respectively. Color overlay shows the angular position of a rotating wedge stimulus that most strongly excites each cortical position. F = foveal confluence; P = periphery. Scale is 1 cm.

a contiguous cortical region that represents an entire hemifield. Area V2 surrounds area V1, with their borders touching along the upper and lower lips of the calcarine cortex. Area V2 is, in turn, surrounded by V3. The several visual areas are difficult to distinguish at their foveal representation, probably because of the limited spatial resolution of the fMRI signal.

Fig. 5B shows a real measurement of the angular retinotopic map on a flattened representation of the region near calcarine cortex. Such flat maps of visual cortex are used to make it easier to see the representation along extended regions of the cortical brain [62–64]; otherwise, it is difficult to visualize data that fall at the bottom of sulci. The rotating wedge stimulus is important for measuring the boundaries between retinotopically organized visual areas, but to be certain that one has identified a well-grouped area, both dimensions of retinotopic organization must be measured.

The rationale for these experimental measurements is based on the assumption that the neurons have a limited spatial receptive field. When either the ring or wedge is seen through a small aperture in the visual field, such as the receptive field of a neuron, as the stimulus progresses, the visual field alternates between the flickering checkerboard and the neutral gray field; this produces a waxing and waning of the neural response. If the stimulus moves at a constant velocity from periphery to fovea, the modulation frequency of the response is the same for all points in the visual field; the responses differ only in their phase. In the case of an expanding ring, neurons with receptive fields in the fovea are phase advanced compared with neurons with receptive fields in the periphery. Hence, the phase of the temporal modulation defines the receptive field position along the dimension of eccentricity. For this reason, retinotopic mapping methods in fMRI often are called “phase-encoded retinotopies”.

After its introduction by Engel et al [50,51], phase-encoding methods were used to identify visual field maps and to define human visual areas [55]. A report by Sereno et al [65] sparked the imagination of many investigators by using phase-encoding methods to create lovely images of the visual areas in the human brain. The main claim in that article, however, that the representation of central vision field is greatly magnified in humans compared with the macaque, now seems incorrect based on direct measurements of humans and macaques using the same fMRI methods [38].

Since its introduction, several groups have measured photopic visual field maps in the normal human brain [53,54,57–60,66,67]. The method also has been used to quantify scotopic maps [68] and the organization of responses in individuals with retinal and cortical dysfunction [61,69]; more recently, Smith and colleagues have extended the analysis of the phase-encoding data in an effort to distinguish the spatial receptive field properties of neurons within these different areas [56–58]. Several investigators have taken the time to identify the visual areas in individual brains before studying response properties to contrast, color, depth, or motion [53,70–73].

Retinotopic organization can be measured without using a visual stimulus: simply have subjects smoothly shift the spatial location of attention from fovea to periphery reveals retinotopic organization in several visual areas [74]. This is surprising because it has proved difficult to measure the effects of attention using microelectrode measurements in areas V1, V2 and V3 of macaque. Several groups have demonstrated the effects of spatial attention in human V1 [73,75,76]. The difference between the single-unit microelectrode measurements and fMRI may be a species difference, or it may reflect differences in the sampling of the neural activity measured by the two techniques.

Cortical area measurements

The existence, location, and general properties of areas V1, V2, V3, and V3A are agreed on across several fMRI labs and shown schematically in two views of posterior brain in Figs. 6A and 6B. The boundaries between these areas can be measured securely beginning at the 2° eccentricity, but there is not yet a secure way to partition their confluent central representations, just lateral to the occipital pole, into the corresponding visual areas (Fig. 6C). The foveal confluence is quite large, usually spanning approximately 2100 mm². A region of area V1 that can be securely defined, representing 2° to 12°, spans roughly 1500 mm². The total area of V2 representing the same portion of the visual field tends to be slightly smaller than V1, on the order of 1100 mm².

There are additional, distinct representations of the central visual field in area V3A [54,59], in motion-selective cortex [77], and in some relatively unexplored regions on the ventral surface of occipital cortex [60,67,78]. Some speculations about the significance of these representations are discussed later.

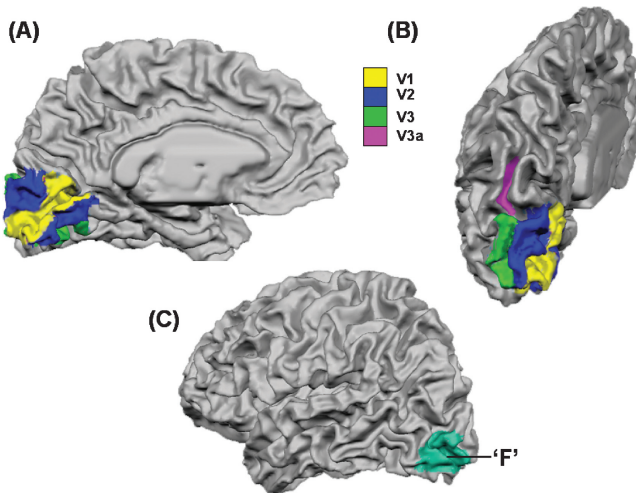


Fig. 6. The typical locations of several retinotopic visual areas in the human brain. Medial (A) and posterior (B) views of cortex showing the positions of visual areas V1, V2, V3, and V3A. (C) Lateral view showing the foveal confluence 'F': the point where the foveal representations of areas V1, V2, and V3 converge. Note that the foveal confluence spreads far onto the lateral surface of the occipital cortex.

Motion-selective cortex

A fundamental assumption of vision science is that the distinctive neural structures, including retinal mosaics of cells (rods and cones; parasol, midget, and small bistratified ganglion cells; cortical areas) have evolved to perform specialized computations. The divergence of signals into multiple processing streams is extraordinary; for example, approximately 250 different bipolar cells contact each foveal cone [79,80]. The functional specialization hypothesis guides work from computational models to neurologic analysis of visual disease [81].

Whereas there is considerable debate about the functional role of most cortical structures, there is consensus that there is an association between motion perception and a human cortical region near the intersection of the occipital, parietal, and temporal lobes. In humans, this region is generally called "MT+" to indicate its homology with a motion-selective region called "MT" in macaque visual cortex.

Like MT, MT+ responds strongly to moving stimuli [82,83]; the anatomic connectivity and functional responsivity in this region of human cortex seem homologous to macaque MT [84,85]. A portion of this region has a detectable retinotopic organization [77] and several aspects of the fMRI responses to moving patterns are explained in terms of the known single-unit properties of macaque MT [86–90].

In an influential single-unit report, Treue and Maunsell [91] showed that single units in macaque MT are influenced by attention. Only a short time

later, it was confirmed that fMRI signals in human MT+ also are strongly modulated by changes in visual attention [92,93]. More recently, this region has been shown to respond to changes of auditory attention [94]. The significance of attention in modulating MT+ signals led to a reappraisal of the widely cited report of a motion aftereffect in MT+ attention [95]; this too turned out to be caused by modulation of attention rather than a stimulus-driven motion aftereffect [96].

In addition, the region near MT+, and perhaps MT+ itself, responds vigorously during normal reading tasks (compared with fixation) [97,98]. Further, the size of the fMRI signal in MT+ is correlated with reading skill in adult readers [99–101]. The confluence of important visual phenomena in this region, including motion signals, attention, and reading, suggests that its computational function will continue to be a focus of studies.

The cutting edge

At this point, the reader might believe that there is widespread agreement about the properties of visual areas in human cortex and that the methods are well in hand. However, such a reader might look at the opening lines of some recent articles to see that passion has not left the field and there are substantial areas of disagreement [102]. Here we focus on the disagreements concerning color, and then look forward to some future directions.

Color areas

It has long been suspected that the ventral surface of the visual cortex is important for color vision. Cases of ventral surface brain damage leading to disruptions in color perception were reported as early as the end of the nineteenth century [103,104], and in the 1970s researchers proposed that cortex contains at least one region specialized in some way for processing color [105–109]. The specific cortical computation that became the focus of the debate was the mechanism by which people regulate the appearance of a surface despite large changes in the ambient illumination. This property is known as “color constancy” and there have been many experiments and computational analyses of the how the visual system achieves perceptual stability across illumination changes [110–114].

Zeki showed that area V4 of the macaque visual cortex contained many cells whose responses tracked the color appearance of an object in the receptive field rather than the wavelength composition of the light it reflected [115,116]. On the basis of this, Zeki proposed that macaque V4 was the “color area” and that it had a special role in color constancy. Later studies questioned this interpretation and described measurements to suggest that V4 is involved in many different visual tasks besides color [117,118]. As functional brain imaging techniques were just becoming available, the next logical stage was to look for a human homologue of this color area.

In a seminal PET study, the London group led by Zeki identified a ventral occipital location for color selective responses in the normal human brain [82,119]. This location was consistent with neurologic data concerning dysfunctional color perception (cerebral achromatopsia) in human patients with achromatopsia [104,120]. The poor spatial resolution and sensitivity of PET made the exact location of the ventral surface activations unclear, and at the time it was impossible to measure visual areas using retinotopic maps. The absence of activation on the dorsal surface suggested that if a human color area existed on the ventral surface, it must contain a compact representation of the upper and lower visual fields. This central claim was buttressed in a series of studies using fMRI; throughout, the London group showed increased responses in human ventral occipital cortex [121,122].

The spatial distribution of the color responses on ventral surface in human differed from those described in macaque V4. In macaque, V4 includes a dorsal and ventral portion that circles around V1, V2 and V3 with the dorsal and ventral regions encoding the lower and upper visual field, respectively (Fig. 7). The implication from the PET and fMRI work in humans was that the human color area was contained entirely on the ventral surface.

In the 1990s, fMRI offered vastly improved spatial resolution and signal-to-noise ratio compared with PET. In principle, these advances should have clarified the existence, function, and location of the human color pathways. Instead, a series of misunderstandings and disagreements over nomenclature triggered a debate that is ongoing, a debate that illustrates the strengths and weaknesses of functional neuroimaging methods.

At the heart of the debate is a claim from a Boston group that the human color area is not V4, rather a “new” color area they termed “V8” [67] (Fig. 8A). Their rationale was based on a combination of color measurements and retinotopic mapping. They identified a quarterfield retinotopic map adjacent to V3 on the ventral surface that they believed to be ventral quarterfield of V4. But the area that they found to respond most strongly to color was

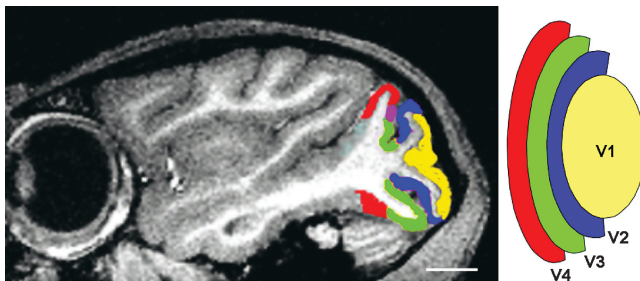


Fig. 7. The location of several retinotopic areas in macaque. V4 (red) flanks visual areas V1 (yellow), V2 (blue), and V3 (green). A small part of V3a (magenta) also is visible on the dorsal surface. In macaque, dorsal cortex represents the lower visual field, whereas the upper visual field representation mainly is found in ventral cortex.

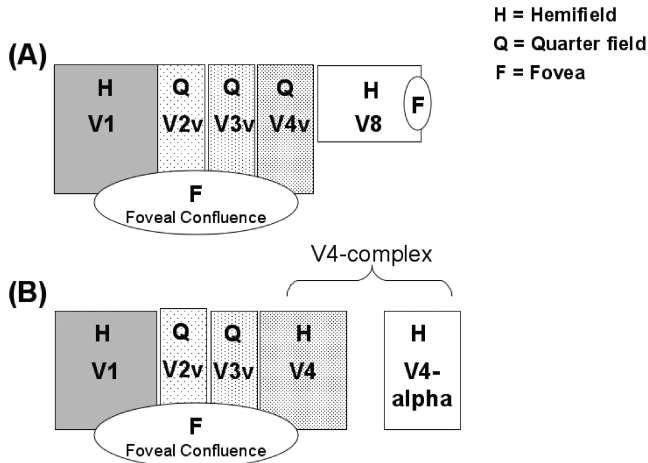


Fig. 8. Organization of the human ventral color areas as proposed by Hadjickani et al (A) and Zeki et al (B). Hadjickani et al locate a single retinotopic quarterfield adjacent to ventral V3, whereas Zeki et al assume this region represents a hemifield. Note also that the V8 hemifield is rotated 90° and thus is perpendicular to the other visual areas. In Zeki et al's model, this region corresponds to a nonretinotopic area called "V4-alpha."

anterior to this region. Retinotopic mapping seemed to show that this "V8" region also composed a hemifield representation.

The London group extended their color work and argued that there are two foci of activation on the ventral surface, one in a retinotopic area they termed "human V4" and the other in an anterior, nonretinotopic or weakly retinotopic area they termed "V4- α (Fig. 8B)." Although the visual field mapping techniques were not complete enough to locate these activations in relation to earlier visual areas [121–123], the standardized Talaraich coordinates for V4- α were close to those of the "newly discovered" V8. It was reasonably clear that the Boston and London groups were describing the same cortical location. The apparent difference arose because the Boston group was eager to retain a theory of the visual maps homologous with macaque. Specifically, they expected a retinotopic representation adjacent to V3, homologous to the quarterfield macaque ventral V4. They presumed that this representation exists, and they referred to the adjacent hemifield representation as V8. The London group did not specifically address retinotopic mapping, choosing instead to challenge the validity of the method. They named V4 based entirely on the color responsivity and putative homology to macaque.

The situation has become further confused. In subsequent publications, the Boston group continued to write about a quarterfield human V4 representation on the ventral occipital lobe. Indeed, their description of V8 hinges on the presence of such a quarterfield representation. They then

searched for a complementary quarterfield representation on the dorsal surface, as in macaque. Not finding a satisfactory dorsal counterpart, they wrote an article asking, “Where is dorsal V4 in human visual cortex?” [72]. Other reports refer vaguely to a V4/V8 region, hoping to avoid controversy, but also avoiding clarity.

The entire area of retinotopic cortex adjacent to ventral V3 is on the order of 3 cm². The voxel dimensions of the MRI signal usually are on the order of 3 mm on a side, and many groups average the responses of several adjacent voxels, improving signal but reducing spatial resolution. In studies of the retinotopic organization of the ventral surface, using methods designed to achieve a high spatial resolution, Wade et al found a complete hemifield representation directly adjacent to ventral V3 [60]. The authors conclude that human V4 simply has a different location than macaque V4, with the entire area representing a full hemifield, falling on the ventral surface. The positions of ventral V3 and V4 measured in humans are shown in Fig. 9. The ventral V3 region represents a quarterfield; the ventral V4 region, which the authors call “human V4 (hV4),” represents a hemifield. In response to the search for dorsal V4, Wade et al [60] concluded that it appears to be alive and well on the ventral surface.

Whether or not hV4 is principally a color computation center is an open question. Engel et al [70] measured the responses of area V1 to calibrated color stimuli and showed stronger activation per unit of cone contrast for opponent color stimuli than for pure luminance stimuli. Based on a definition that uses the criterion, “responds better to color than luminance,” it seems that even striate cortex has a claim to be a “color area.” So too would the central retina. In studies of the effects of color adaptation, an essential part of color constancy, the authors have found that much of the computation is explained by gain changes in the photoreceptors [124].

Given the fact that all groups measure multiple responses to color in ventral cortex, and that the authors’ group sees important computational processes that are almost surely of retinal origin, it may be wise to focus on the entire computational stream rather than emphasizing the unique role of a single region in ventral occipital cortex. Until the computational basis of human color vision is understood more clearly, it may be more productive to speak of a color pathway that begins in the retina and passes through V1, V2, and higher areas including the V4 complex. Each area is important for color perception (and in other facets of vision), and their precise functions await a more complete characterization.

Neurologic applications

Beyond the work using control subjects, much is learned from functional brain imaging studies of individuals with visual deficits. These deficits (cortical, retinal, or ocular) permit study of the way in which the cortex reorganizes in response to a change in the nature of everyday visual

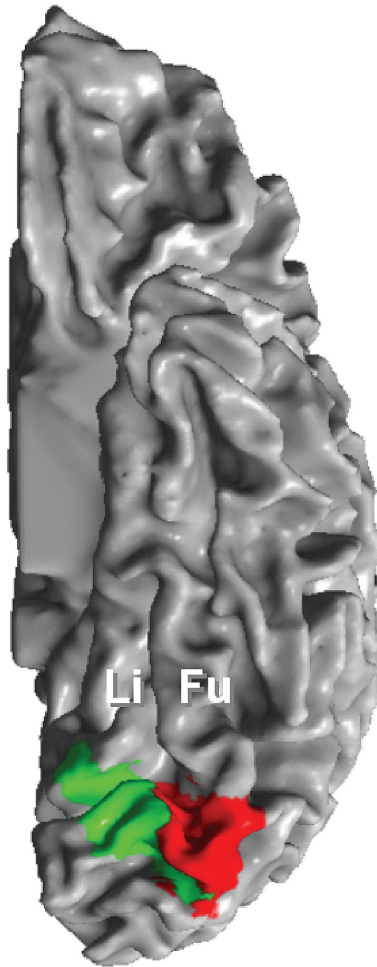


Fig. 9. Locations of the ventral portion of area V3 (green) and the entire area human V4 (hV4; red) [60,102].

stimulation and allow testing of some of the theories regarding the existence, function, and overlap of different visual pathways. The application of fMRI to neuro-ophthalmology is in its infancy, and there are many opportunities for useful work. Here, a few instances are described that have provided insight into visual pathways and visual development.

Perhaps the most intensely investigated area of cortical visual dysfunction is the phenomenon of blindsight. In this condition, a patient with cortical damage resulting in a hemianopia retains some residual abilities to discriminate between targets. The phenomenon is called blindsight, because the patient reports no conscious visual experience in the blind hemifield;

yet when pressed to respond, the patient makes certain types of visual discriminations at levels much higher than chance. The most thoroughly studied blindsight patient is GY, whose visual brain and performance have been studied by several laboratories [125–127]. GY has two major lesions, one of which falls on the medial aspect of the left occipital lobe and includes calcarine cortex. There is some foveal sparing of his vision, but he reports a complete blindness in his peripheral field beyond approximately 2°. GY performs better than chance, however, on several simple visual discriminations involving motion, orientation, and color [128].

Although the neural basis of this has been attributed to spared islands of gray matter within V1 [129], this does not seem to be a general explanation [130]. Rather, it seems that the discrimination performance in blindsight is based on signals that travel via alternate thalamic pathways. Evidence for this hypothesis comes from studies showing that such individuals have powerful activation in MT+ despite nearly complete destruction of V1 [126,127,131]. These signals may travel via the superior colliculus and pulvinar [132]. Until the work on blindsight, this route was rarely discussed. The blindsight studies show, however, that cortical signals traveling via the pulvinar make a significant contribution to extrastriate cortex, particularly those in the motion-responsive regions [131].

A fascinating case of unusual vision further supports the role of these cortical responses. Subject MM suffered an injury from a chemical explosion when he was a three-year-old child: one eye was lost, and the second eye was damaged to the point where no corneal replacement was possible. He lived as a blind man for forty years, when his cornea was restored monocularly after an epithelial stem transplant. Fine and colleagues measured the consequence of this long-term deprivation on MM's visual judgments [133]. The authors' group has assisted their study by measuring the effects of this deprivation on the organization of cortex, and in particular the identifiable visual areas.

Remarkably, just as in GY, the motion-selective portion of MM's brain is powerfully activated in response to moving stimuli. His MT+ region is the same size and location as that of a control subject (Fig. 10), but visual stimulation to map retinotopic visual areas produces only weak and disorganized activation near calcarine cortex; the standard retinotopic organization flanking the calcarine sulcus is clearly disrupted and this is particularly so on the ventral surface of the occipital lobe.

MM's visual judgments are consistent with this pattern of cortical signals. He performs well on tasks involving motion perception, for example, extracting form from patterns of coherently moving dots and navigating complex environments in real-time. His visual acuity and static form perception, however, are much impaired: he has a grating acuity of only 1.5 cycles per degree and has great difficulty in recognizing everyday objects and faces. His monocular depth perception also is severely degraded. Some of these deficits may be attributable to failures in higher-level visual mechanisms, but the initial reduction in visual acuity almost certainly is cortical with its origins in

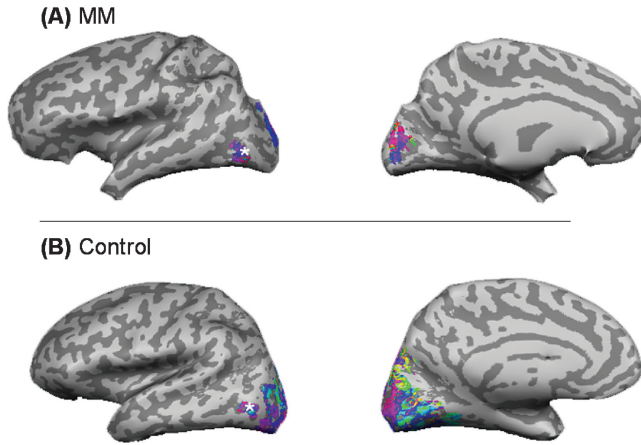


Fig. 10. Visual field representations in MM and a control shown on inflated representations of the brain. The color overlay shows the preferred angular signal measured using a rotating wedge stimulus (see Fig. 4) in subject MM (A) and a control subject (B). Area MT+ is marked with an asterisk and has a retinotopic organization of comparable size in both subjects (lateral views, *left*). Signals in cortex surrounding the calcarine sulcus and extending onto the lateral surface are much weaker in subject MM compared a control; in MM, these signals do not exceed a coherence threshold of 0.35.

V1; the absence of well-defined retinotopic maps in early visual areas must have some severe consequences for later visual computations.

These results suggest that after cortical damage, or after extended absence of contrast stimulation, the plasticity and recovery in separate cortical pathways differ. In MM and the blindsight patients, motion-responsive cortex continues to respond powerfully and to occupy a similar position and size as in controls. V1 and neighboring regions seem to be much more vulnerable to visual deprivation and these areas seem to reorganize [69]. Reorganization in V1 also is present in subjects with congenital stationary night blindness (rod monochromats [61]). The blindsight subjects and MM seem to use the secondary (pulvinar) pathway, even when there is significant degradation of input from V1. The remaining MT+ signals do not produce a conscious visual experience.

The future

What has been learned about the visual pathways using fMRI? The early fMRI studies created trust in the data. The first images of visual field maps and identification of visual areas provided no insights into the workings of the visual pathways, but without these studies there could have been little confidence that the measurements were valid.

Almost as soon as the methodology became trusted, discoveries were made. That human V3A was strikingly sensitive to motion, unlike macaque V3A, came as a surprise [54]. The presence of strong opponent color signals

in human striate cortex contradicted the view that color was a minor component of the signals in V1 [70]. The powerful and retinotopically organized human responses to shifts in spatial attention also were unexpected [74]. Whatever the details of the final outcome, the debate regarding human “color area” demonstrates that the human color responses follow a different spatial organization from those in the macaque.

A second advance from fMRI flows from the ability to visualize across a significant span of the cortical surface. The comparison between human and macaque visual cortex measured on the scale of centimeters raises questions about the system-level organization that was difficult to visualize in the past. For example, in this article, the authors discuss the foveal confluence and the nearby visual areas. Human visual cortex seems to differ from macaque in that it contains several clearly distinct foveal representations, each of which is surrounded by a region of retinotopically organized cortex [54,59,60,67]. Does each representation form a computational unit for the visual brain?

Functional neuroimaging of the human is bringing about a third change. Through persistent and often heroic efforts, visual neuroscientists have measured single-unit activity and behavior simultaneously. Often, the time spent training the animal to perform the task is the most difficult experimental challenge. In human functional neuroimaging, however, it is much simpler to arrange for subjects to perform tasks during the measurement process. This provides access to a range of performance measures that enrich the understanding of human awareness and behavioral challenges [127,134–137].

Beyond the specific questions about visual cortex, probably the most significant contribution of noninvasive brain imaging, in particular fMRI, has been to return humans to a position of importance. In the nineteenth and early twentieth centuries, knowledge of the brain came mainly from studying the coarse measurements of head trauma and brain lesions in human subjects. In the twentieth century, the development and use of single-unit electrode measurements in animal models generated a wealth of information on all aspects of neuroscience, drawing attention to the fine spatial scale of the single neuron. These animal measurements are now augmented by functional neuroimaging techniques in humans, and there soon will be an uninterrupted view of the brain from the micron to the centimeter scale. One of the most exciting challenges of twenty-first century neuroscience is to turn this wealth of data into a unified explanation of how sight works.

Acknowledgment

The authors thank David Heeger for comments.

References

- [1] Ogawa S, Lee TM. Magnetic resonance imaging of blood vessels at high fields: in vivo and in vitro measurements and image simulation. *Magn Reson Med* 1990;16:9–18.
- [2] Ogawa S, et al. Brain magnetic resonance imaging with contrast dependent on blood oxygenation. *Proc Natl Acad Sci USA* 1990;87:9868–72.
- [3] Ogawa S, et al. Oxygenation-sensitive contrast in magnetic resonance image of rodent brain at high magnetic fields. *Magn Reson Med* 1990;14:68–78.
- [4] Ogawa S, et al. Intrinsic signal changes accompanying sensory stimulation: functional brain mapping with magnetic resonance imaging. *Proc Natl Acad Sci USA* 1992;89:5951–5.
- [5] Bandettini P, et al. Time course EPI of human brain function during task activation. *Magn Reson Med* 1992;25:390–7.
- [6] Kwong KK, et al. Dynamic magnetic resonance imaging of human brain activity during primary sensory stimulation. *Proc Natl Acad Sci USA* 1992;89:5675–9.
- [7] Wandell BA. Computational neuroimaging of human visual cortex. *Annu Rev Neurosci* 1999;22:145–73.
- [8] Jezzard P, Matthews PM, Smith SM. Functional magnetic resonance imaging: an introduction to methods. Oxford, UK: Oxford University Press; 2001.
- [9] Buxton RB. An introduction to functional magnetic resonance imaging: principles and techniques. Cambridge, UK: Cambridge University Press; 2001.
- [10] Moonen CTW, Bandettini PA. Functional MRI. New York: Springer; 1999.
- [11] Heeger DJ, Ress D. What does fMRI tell us about neuronal activity? *Nat Rev Neurosci* 2002;3:142–51.
- [12] Siesjo B. Brain energy metabolism. New York: John Wiley & Sons; 1978.
- [13] Fox PT, Raichle ME. Focal physiological uncoupling of cerebral blood flow and oxidative metabolism during somatosensory stimulation in human subjects. *Proc Natl Acad Sci USA* 1986;83:1140–4.
- [14] Fox PT, et al. Nonoxidative glucose consumption during focal physiologic neural activity. *Science* 1988;241:462–4.
- [15] Magistretti PJ, Pellerin L. Cellular mechanisms of brain energy metabolism and their relevance to functional brain imaging. *Philos Trans R Soc Lond [Biol]* 1999;354:1155–63.
- [16] Buxton RB, Frank LR. A model for the coupling between cerebral blood flow and oxygen metabolism during neural stimulation. *J Cereb Blood Flow Metab* 1997;17:64–72.
- [17] Hyder F, Shulman RG, Rothman DL. A model for the regulation of cerebral oxygen delivery. *J Appl Physiol* 1998;85:554–64.
- [18] Attwell D, Laughlin SB. An energy budget for signaling in the grey matter of the brain. *J Cereb Blood Flow Metab* 2001;21:1133–45.
- [19] Shulman RG, Hyder F, Rothman DL. Cerebral energetics and the glycogen shunt: neurochemical basis of functional imaging. *Proc Natl Acad Sci USA* 2001;98:6417–22.
- [20] Fitzpatrick SM, Rothman D. New approaches to functional neuroenergetics. *J Cogn Neurosci* 1999;11(4):467–71.
- [21] Damasio H, Damasio AR. Lesion analysis in neuropsychology. New York: Oxford University Press; 1989.
- [22] Graham N. Visual pattern analyzers. Oxford (UK): Oxford University Press; 1989.
- [23] Wandell BA. Foundations of vision. Sunderland (MA): Sinauer Press; 1995.
- [24] Young T. On the theory of light and colors. (The 1801 Bakerian Lecture) *Philosophical Transactions of the Royal Society of London* 1802;92:12–8.
- [25] Helmholtz H. Physiological optics. In: Southall JPC, editor. *Treatise on physiological optics*. Rochester, NY: The Optical Society of America; 1924–1925.
- [26] Rees G, Friston K, Koch C. A direct quantitative relationship between the functional properties of human and macaque V5. *Nat Neurosci* 2000;3:716–23.

- [27] Heeger DJ, et al. Spikes versus BOLD: what does neuroimaging tell us about neuronal activity? *Nat Neurosci* 2000;3:631–3.
- [28] Mathiesen C, et al. Modification of activity-dependent increases of cerebral blood flow by excitatory synaptic activity and spikes in rat cerebellar cortex. *J Physiol* 1998;512:555–66.
- [29] Mathiesen C, Caesar K, Lauritzen M. Temporal coupling between neuronal activity and blood flow in rat cerebellar cortex as indicated by field potential analysis. *J Physiol* 2000;523:235–46.
- [30] Lauritzen M. Relationship of spikes, synaptic activity, and local changes of cerebral blood flow. *J Cereb Blood Flow Metab* 2001;21:1367–83.
- [31] Norup Nielsen A, Lauritzen M. Coupling and uncoupling of activity-dependent increases of neuronal activity and blood flow in rat somatosensory cortex. *J Physiol* 2001;533:773–85.
- [32] Logothetis NK. The neural basis of the BOLD fMRI signal. *Philos Trans R Soc Lond [B]* 2002;357(1424):1003–37.
- [33] Leopold DA, Logothetis NK. Activity changes in early visual cortex reflect monkeys' percepts during binocular rivalry. *Nature* 1996;379:549–53.
- [34] Blake R, Logothetis NK. Visual competition. *Nat Rev Neurosci* 2002;3:13–21.
- [35] Polonsky A, et al. Neuronal activity in human primary visual cortex correlates with perception during binocular rivalry. *Nat Neurosci* 2000;3:1153–9.
- [36] Logothetis NK, et al. Neurophysiological investigation of the basis of the fMRI signal. *Nature* 2001;412:150–7.
- [37] Disbrow EA, et al. Functional MRI at 1.5 tesla: a comparison of the blood oxygenation level-dependent signal and electrophysiology. *Proc Natl Acad Sci USA* 2000;97:9718–23.
- [38] Brewer AA, Press WA, Logothetis NK, Wandell BA. Visual areas in macaque cortex measured using functional MRI. *J Neurosci* 2002;22:10416–26.
- [39] Harrison RV, et al. Blood capillary distribution correlates with hemodynamic-based functional imaging in cerebral cortex. *Cereb Cortex* 2002;12:225–33.
- [40] Zheng D, LaMantia AS, Purves D. Specialized vascularization of the primate visual cortex. *J Neurosci* 1991;11:2622–9.
- [41] Raichle M. A brief history of human functional brain mapping. In: Toga A, Mazziotta J, editors. *The systems*. San Diego: Academic Press; 2000. p. 33–75.
- [42] Dale AM. Optimal experimental design for event-related fMRI. *Hum Brain Map* 1999;8:109–14.
- [43] George JS, et al. Dynamic functional neuroimaging integrating multiple modalities. In: Jezzard P, Matthews PM, Smith SM, editors. *Functional MRI: an introduction to methods*. Oxford (UK): Oxford Medical Publishing; 2001.
- [44] Nunez PL. *Electric fields of the brain*. New York: Oxford University Press; 1981.
- [45] Braitenberg V, Schüz A. *Cortex: statistics and geometry of neuronal connectivity*. 2nd edition. Berlin, Germany: Springer; 1998.
- [46] Zeki S. *A vision of the brain*. London: Blackwell Scientific Publications; 1993.
- [47] Felleman DJ, Van Essen DC. Distributed hierarchical processing in the primate cerebral cortex. *Cereb Cortex* 1991;1:1–47.
- [48] Kaas J. Theories of visual cortex organization in primates. In: Rockland K, Kaas J, Peters A, editors. *Extrastriate cortex in primates*. New York: Plenum Press; 1997. p. 91–125.
- [49] Van Essen DC. Organization of visual areas in macaque and human cerebral cortex. In: Chalupa L, Werner J, editors. *Visual neurosciences*, in press.
- [50] Engel SA, et al. fMRI of human visual cortex [letter]. *Nature* 1994;369:525 [erratum, *Nature* 1994;370:106].
- [51] Engel SA, et al. Functional MRI measurements of human striate cortex topography. *Soc Neurosci Abs* 1993;19:335.
- [52] Engel SA, Glover GH, Wandell BA. Retinotopic organization in human visual cortex and the spatial precision of functional MRI. *Cereb Cortex* 1997;7:181–92.
- [53] Tootell RB, et al. New images from human visual cortex. *Trends Neurosci* 1996;19:481–9.

- [54] Tootell RB, et al. Functional analysis of V3A and related areas in human visual cortex. *J Neurosci* 1997;17:7060–78.
- [55] DeYoe EA, et al. Functional magnetic resonance imaging (fMRI) of the human brain. *J Neurosci Methods* 1994;54:171–87.
- [56] Singh KD, Smith AT, Greenlee MW. Spatiotemporal frequency and direction sensitivities of human visual areas measured using fMRI. *Neuroimage* 2000;12:550–64.
- [57] Smith AT, et al. Estimating receptive field size from fMRI data in human striate and extrastriate visual cortex. *Cereb Cortex* 2001;11:1182–90.
- [58] Smith AT, et al. The processing of first- and second-order motion in human visual cortex assessed by functional magnetic resonance imaging (fMRI). *J Neurosci* 1998; 18:3816–30.
- [59] Press WT, et al. Visual areas and spatial summation in human visual cortex. *Vision Res* 2001;41:1321–32.
- [60] Wade AR, et al. Functional measurements of human ventral occipital cortex: retinotopy and color. *Philos Trans R Soc [B]* 2002;357:963–73.
- [61] Baseler HA, et al. Reorganization of human cortical maps caused by inherited photoreceptor abnormalities. *Nat Neurosci* 2002;5:364–70.
- [62] Fischl B, Sereno MI, Dale AM. Cortical surface-based analysis. II: inflation, flattening, and a surface-based coordinate system. *Neuroimage* 1999;9:195–207.
- [63] Dale AM, Fischl B, Sereno MI. Cortical surface-based analysis I. Segmentation and surface reconstruction. *Neuroimage* 1999;9:179–94.
- [64] Wandell BA, Chial S, Backus B. Visualization and measurement of the cortical surface. *J Cog Neurosci* 2000;12:739–52.
- [65] Sereno MI, et al. Borders of multiple human visual areas in humans revealed by functional MRI. *Science* 1995;268:889–93.
- [66] Tootell RB, et al. Visual motion aftereffect in human cortical area MT revealed by functional magnetic resonance imaging [see comments]. *Nature* 1995;375:139–41.
- [67] Hadjikhani N, et al. Retinotopy and color sensitivity in human visual cortical area V8. *Nat Neurosci* 1998;1:235–41.
- [68] Hadjikhani N, Tootell RB. Projection of rods and cones within human visual cortex. *Hum Brain Mapp* 2000;9:55–63.
- [69] Baseler HA, Morland AB, Wandell BA. Topographic organization of human visual areas in the absence of input from primary cortex. *J Neurosci* 1999;19:2619–27.
- [70] Engel SA, Zhang X, Wandell BA. Color tuning in human visual cortex measured using functional magnetic resonance imaging. *Nature* 1997;388:68–71.
- [71] DeYoe EA, et al. Mapping striate and extrastriate visual areas in human cerebral cortex. *Proc Natl Acad Sci USA* 1996;93:2382–6.
- [72] Tootell RB, Hadjikhani N. Where is ‘dorsal V4’ in human visual cortex? Retinotopic, topographic and functional evidence. *Cereb Cortex* 2001;11:298–311.
- [73] Tootell RB, et al. The retinotopy of visual spatial attention. *Neuron* 1998;21:1409–22.
- [74] Brefczynski JA, DeYoe EA. A physiological correlate of the ‘spotlight’ of visual attention. *Nat Neurosci* 1999;2:370–4.
- [75] Somers DC, et al. Functional MRI reveals spatially specific attentional modulation in human primary visual cortex. *Proc Natl Acad Sci USA* 1999;96:1663–8.
- [76] Gandhi SP, Heeger DJ, Boynton GM. Spatial attention affects brain activity in human primary visual cortex. *Proc Natl Acad Sci USA* 1999;96:3314–9.
- [77] Huk AC, Dougherty RF, Heeger DJ. Retinotopy and functional subdivision of human areas MT and MST. *J Neurosci* 2002;22:7195–205.
- [78] Malach R, Levy I, Hasson U. The topography of high-order human object areas. *Trends Cogn Sci* 2002;6:176–84.
- [79] Calkins DJ. Representation of cone signals in the primate retina. *J Opt Soc Am [A]* 2000;17:597–606.
- [80] Rodieck RW. *The first steps in seeing*. Sunderland (MA): Sinauer Press; 1998.

- [81] Barton JJ, Rizzo M. Motion perception in optic neuropathy. *Neurology* 1994;44: 273–8.
- [82] Zeki S, et al. A direct demonstration of functional specialization in human visual cortex. *J Neurosci* 1991;11:641–9.
- [83] Watson JD, et al. Area V5 of the human brain: evidence from a combined study using positron emission tomography and magnetic resonance imaging. *Cereb Cortex* 1993;3: 79–94.
- [84] Tootell RB, et al. Functional analysis of human MT and related visual cortical areas using magnetic resonance imaging. *J Neurosci* 1995;15:3215–30.
- [85] Tootell RBH, Taylor JB. Anatomical evidence for MT and additional cortical visual areas in humans. *Cereb Cortex* 1995;1:39–55.
- [86] Heeger DJ, et al. Motion opponency in visual cortex. *J Neurosci* 1999;19:7162–74.
- [87] Huk AC, Heeger DJ. Pattern-motion responses in human visual cortex. *Nat Neurosci* 2002;5:72–5.
- [88] Wandell BA, et al. Color signals in human motion-selective cortex. *Neuron* 1999;24:901–9.
- [89] Seidemann E, et al. Color signals in area MT of the macaque monkey. *Neuron* 1999;24:911–7.
- [90] Dougherty R, Press WT, Wandell BA. Perceived speed of color stimuli. *Neuron* 1999;24:893–9.
- [91] Treue S, Maunsell JH. Attentional modulation of visual motion processing in cortical areas MT and MST. *Nature* 1996;382:539–41.
- [92] O’Craven KM, et al. Voluntary attention modulates fMRI activity in human MT-MST. *Neuron* 1997;18:591–8.
- [93] Beauchamp MS, Cox RW, DeYoe EA. Graded effects of spatial and featural attention on human area MT and associated motion processing areas. *J Neurophysiol* 1997;78: 516–20.
- [94] Berman RA, Colby CL. Auditory and visual attention modulate motion processing in area MT+. *Brain Res Cogn Brain Res* 2002;14:64–74.
- [95] Tootell RB, et al. Visual motion aftereffect in human cortical area MT revealed by functional magnetic resonance imaging. *Nature* 1995;375:139–41.
- [96] Huk AC, Ress D, Heeger DJ. Neuronal basis of the motion aftereffect reconsidered. *Neuron* 2001;32:161–72.
- [97] Price CJ. The anatomy of language: contributions from functional neuroimaging. *J Anat* 2000;197:335–59.
- [98] Fiebach CJ, et al. fMRI evidence for dual routes to the mental lexicon in visual word recognition. *J Cogn Neurosci* 2002;14:11–23.
- [99] Demb JB, Boynton GM, Heeger DJ. Brain activity in visual cortex predicts individual differences in reading performance. *Proc Natl Acad Sci USA* 1997;94:13363–6.
- [100] Demb JB, Boynton GM, Heeger DJ. Functional magnetic resonance imaging of early visual pathways in dyslexia. *J Neurosci* 1998;18:6939–51.
- [101] Eden GF, et al. Abnormal processing of visual motion in dyslexia revealed by functional brain imaging. *Nature* 1996;382:66–9.
- [102] Zeki S. Improbable areas in the visual brain. *Trends Neurosci* 2003;26:23–6.
- [103] Verrey L. Hémichromatopsie droite absolue. *Arch Opthal (Paris)* 1888;8:289–301.
- [104] Zeki S. A century of cerebral achromatopsia. *Brain* 1990;113:1721–77.
- [105] Meadows J. Disturbed perception of colours associated with localized cerebral lesions. *Brain* 1974;97:615–32.
- [106] Zeki SM. Colour coding in rhesus monkey prestriate cortex. *Brain Res* 1973;53:422–7.
- [107] Zeki SM. Colour coding in the superior temporal sulcus of the rhesus monkey [proceedings]. *J Physiol* 1976;263:169P–70P.
- [108] Zeki SM. Colour coding in the superior temporal sulcus of rhesus monkey visual cortex. *Proc R Soc Lond [B]* 1977;197:195–223.
- [109] Zeki S. The representation of colours in the cerebral cortex. *Nature* 1980;284:412–8.

- [110] Maloney LT, Wandell BA. Color constancy: a method for recovering surface spectral reflectance. *J Opt Soc Am A* 1986;3:29–33.
- [111] Wandell BA. The synthesis and analysis of color images. *IEEE PAMI* 1987;PAMI-9:2–13.
- [112] Land EH. Recent advances in retinex theory. *Vision Res* 1986;26:7–22.
- [113] Brainard D, Wandell B, Chichilnisky E. Color constancy: from physics to appearance. *Current Directions in Psychological Science* 1993;2:165–70.
- [114] Brainard D, Freeman W. Bayesian color constancy. *J Opt Soc Am [A]* 1997;14:1393–411.
- [115] Zeki S. Colour coding in the cerebral cortex: the reaction of cells in monkey visual cortex to wavelengths and colours. *Neuroscience* 1983;9:741–65.
- [116] Zeki S. The relationship between wavelength and color studied in single cells of monkey striate cortex. *Prog Brain Res* 1983;58:219–27.
- [117] Schein SJ, Marrocco RT, de Monasterio FM. Is there a high concentration of color-selective cells in area V4 of monkey visual cortex? *J Neurophysiol* 1982;47:193–213.
- [118] Desimone R, et al. Contour, color and shape analysis beyond the striate cortex. *Vision Res* 1985;25:441–52.
- [119] Lueck CJ, et al. The colour centre in the cerebral cortex of man. *Nature* 1989;340:386–9.
- [120] Rizzo M, et al. Color perception profiles in central achromatopsia. *Neurology* 1993;43:995–1001.
- [121] McKeefry DJ, Zeki S. The position and topography of the human colour centre as revealed by functional magnetic resonance imaging. *Brain* 1997;120:2229–42.
- [122] Bartels A, Zeki S. The architecture of the colour centre in the human visual brain: new results and a review. *Eur J Neurosci* 2000;12:172–93.
- [123] Zeki S, Bartels A. The clinical and functional measurement of cortical (in)activity in the visual brain, with special reference to the two subdivisions (V4 and V4 alpha) of the human colour centre. *Philos Trans R Soc Lond [B]* 1999;354:1371–82.
- [124] Wade A, Wandell B. Cone specific color adaptation measured in human V1. *J Neurosci* 2002;22:8148–57.
- [125] Weiskrantz L, Barbur JL, Sahraie A. Parameters affecting conscious versus unconscious visual discrimination with damage to the visual cortex (V1). *Proc Natl Acad Sci USA* 1995;92:6122–6.
- [126] ffytche DH, Gu DH, Zeki S. Motion specific responses from a blind hemifield. *Brain* 1996;119:1971–82.
- [127] Goebel R, et al., Sustained extrastriate cortical activation without visual awareness revealed by fMRI studies of hemianopic patients. *Vision Res* 2001;41:1459–74.
- [128] Morland AB, et al. Visual perception of motion, luminance and colour in a human hemianope. *Brain* 1999;122:1183–98.
- [129] Fendrich R, Wessinger CM, Gazzaniga MS. Residual vision in a scotoma: implications for blindsight. *Science* 1992;258:1489–91.
- [130] Kleiser R, et al. Is V1 necessary for conscious vision in areas of relative cortical blindness? *Neuroimage* 2001;13:654–61.
- [131] Bittar RG, et al. Activation of the remaining hemisphere following stimulation of the blind hemifield in hemispherectomized subjects. *Neuroimage* 1999;10:339–46.
- [132] Shipp S. Corticopulvinar connections of areas V5, V4, and V3 in the macaque monkey: a dual model of retinal and cortical topographies. *J Comp Neurol* 2001;439:469–90.
- [133] MacLeod DIA, Fine I. Vision after early blindness. *J Vis* 2001;1:470A.
- [134] Formisano E, et al. Tracking the mind's image in the brain I: time-resolved fMRI during visuospatial mental imagery. *Neuron* 2002;35:185–94.
- [135] Grill-Spector K, et al. The dynamics of object-selective activation correlate with recognition performance in humans. *Nat Neurosci* 2000;3:837–43.
- [136] Backus BT, et al. Human cortical activity correlates with stereoscopic depth perception. *J Neurophysiol* 2001;86:2054–68.
- [137] Heeger DJ. Linking visual perception with human brain activity. *Curr Opin Neurobiol* 1999;9:474–9.