

Extrastriate visual signals in the absence of striate cortex in a human hemianope

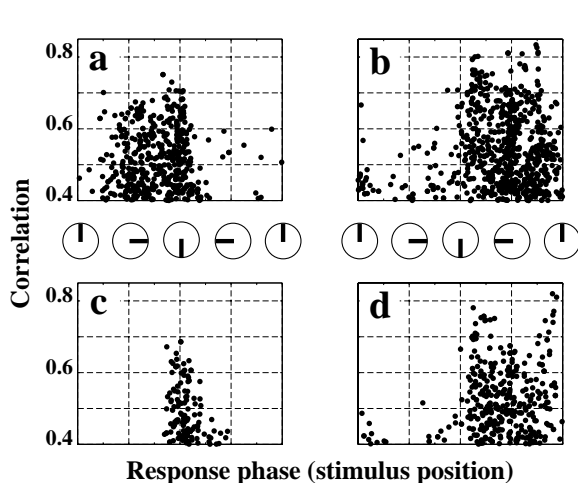
H. A. Baseler, A. B. Morland[†] and B. A. Wandell

*Depts. of Psychology and Neuroscience, Stanford University, Stanford, CA, 94305, USA.
and Biophysics Section, Physics Department, Imperial College, London, UK[†]*

Introduction. Primary visual (striate) cortex (V1) is a major gateway that distributes signals from the retina and subcortex to extrastriate cortex. Individuals with V1 lesions are blind to most visual targets, although careful testing shows that in some, residual visual function is present in the hemianopic field. Using functional magnetic resonance imaging (fMRI), we measured activity in a subject with a large lesion in left calcarine cortex, including most of V1. Our principal goal was to evaluate the retinotopic organization of the responses obtained from the intact portion of the damaged hemisphere in order to understand (a) the sources of these signals, and (b) whether they serve a role in his residual vision.

Methods. Subject G.Y. had unilateral occipital lobe damage with sparing at the occipital pole. Phase-encoded measurements of rotating wedges and expanding rings were used to identify early visual areas on flattened representations of the cortical surface (1). Data were gathered using two types of rotating wedge stimuli. In the *full wedge* condition the stimulus spanned a radius of 8 deg of visual angle. In the *annular wedge* condition the stimulus was presented only at eccentricities between 4 and 8 deg from the fovea.

Results. Within the right hemisphere and intact regions of the damaged left hemisphere expanding ring stimulation revealed normal, retinotopic organization.



The figure shows measurements made under rotating wedge conditions. The vertical axis represents the amplitude of the fMRI signal at the stimulus frequency divided by the total variance of the signal (correlation). The horizontal axis represents angular position of the visual field representation (insets) as inferred from the phase of the fMRI signal. Data from areas V1, V2, V3, V3A and V4v are pooled in each panel.

Left panels show data from the left hemisphere, right panels from the right hemisphere. The top panels (a,b) show measurements using the full wedge, including the spared macula. Consistent with normal observers, the left and right hemispheres responded primarily to stimuli in the right and left hemifields, respectively.

The bottom panels (c,d) show measurements in the left and right hemispheres using the annular wedge. Activation in the intact hemisphere was similar to that measured in the full wedge condition (panel d). Activation in the lesioned hemisphere was confined to dorsal regions (not identified in this figure), and generated mainly by stimuli near the lower vertical meridian (panel c). Interestingly, this activity included response phases that were present in the responses of both the lesioned (panel a) and intact (panels b,d) hemispheres.

Conclusions. The distribution of response phases near the lower vertical meridian to blind field stimulation suggest three possible sources: 1) Spared sections of area V1 near the representation of the lower vertical midline, 2) subcortical projections within the lesioned hemisphere which bypass V1 (compare panels a and c), and 3) transcallosal connections from cortical areas in the intact hemisphere (compare panels b and d with c). Previously reported psychophysical measurements of visual field sensitivity suggest that G.Y.'s blind field may be enhanced near the lower vertical meridian.

1. Engel, S.A., Glover, G.H., Wandell, B.A., *Cerebral Cortex*, 1997, 7:181-192.

Presented at the 4th International Conference on the Functional Mapping of the Human Brain, June 10, 1998, in Montreal, Quebec, Canada